

KERATOCONUS



8 St Marks Road, Remuera
phone (64) 09 529 2480
fax (64) 09 529 2481
email admin@aucklandeye.co.nz
web www.aucklandeye.co.nz

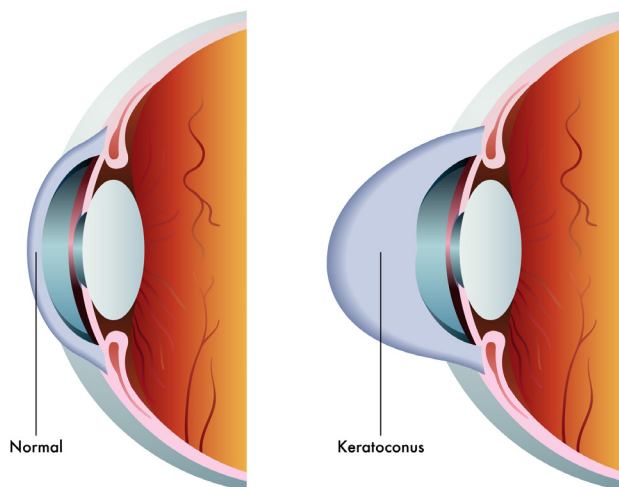


www.aucklandeye.co.nz

KERATOCONUS

Keratoconus is an inherited condition of the cornea. The cornea is the transparent front surface of the eye. In keratoconus, the normally round cornea becomes thinned, distorted and cone shaped.

This abnormal shape prevents the light entering the eye from being focused correctly on the retina and causes distortion of vision. Because of the cornea's irregular shape, patients with keratoconus are usually very nearsighted and have a high degree of astigmatism that is not correctable with glasses.



SIGNS AND SYMPTOMS

- Nearsightedness
- Astigmatism

- Blurred vision – even when wearing contact lenses or glasses
- Glare at night
- Eye rubbing
- Light sensitivity
- Frequent prescription changes in glasses and contact lenses

WHAT CAN CAUSE KERATOCONUS?

Studies have provided evidence to suggest a genetic basis for keratoconus. Up to 50% of family members of patients with keratoconus have subtle signs of early keratoconus.

Keratoconus can occur in association with a variety of diseases, including eczema, hay fever and asthma. Keratoconus is more common in people with Down's syndrome.

DEVELOPMENT OF KERATOCONUS

In its earliest stages, keratoconus causes slight blurring and distortion of vision and increased sensitivity to glare and light. These symptoms usually appear in the late teens or early twenties. Most cases are stable and non progressive by the time the patients are in their mid 30s.

Each eye may be affected differently and one eye may have very poor vision while the other eye retains perfect vision.

As keratoconus progresses, the cornea bulges more and the vision may become more distorted. The cornea is weaker than the normal cornea and may be damaged by minor trauma. For this reason people with keratoconus should not participate in contact sports.



HYDROPS

In a small number of cases, hydrops occurs where the cornea will swell and cause a sudden and significant decrease in vision. This occurs when the stretching causes a tiny split to develop in the inside surface of the cornea.

The swelling may last for weeks or months as the crack heals and is gradually replaced by scar tissue. If this sudden swelling does occur, your doctor can prescribe eyedrops for temporary relief, but there are no medicines that can prevent the disorder from progressing.

Often the scarring causes the vision to be somewhat worse after an attack of hydrops. Sometimes however the scarring may improve the shape of the cornea, improving the vision. The cornea may become very thin but it is very unlikely to spontaneously rupture.

TREATMENT

Treatment of keratoconus depends on the severity of the condition. Initially, eye glasses or soft contact lenses are successful in correcting the myopia (near sightedness) and astigmatism.

As the disorder progresses and the cornea continues to thin and change shape, rigid gas permeable contact lenses can be prescribed to correct vision.

In most cases, this is adequate but the contact lenses must be carefully fitted by

an optometrist and frequent checkups and lens changes may be needed to achieve and maintain good vision.

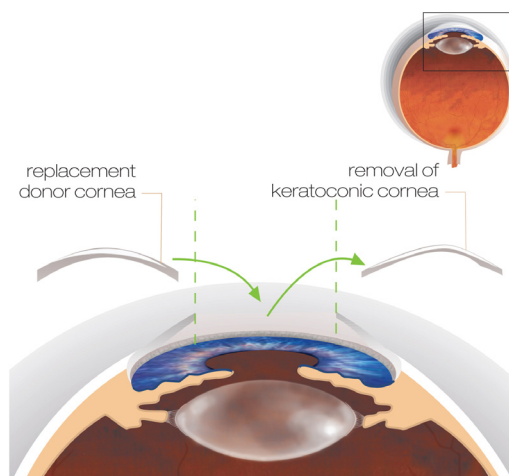
A government subsidy may be available to help with the costs of contact lens wear. Contact lens wear in keratoconus does not alter the progression of the disease or cure the condition.

It merely gives improved vision while the lenses are being worn. When good vision can no longer be attained with contact lenses because of corneal scarring or intolerance to contact lens wear, surgery may be indicated.

SURGICAL PROCEDURES

Some patients may be suitable for corneal implants, which work by flattening the steep part of the cornea to reduce vision distortion caused by keratoconus. The end result depends on the degree of keratoconus being treated. For severe keratoconus, corneal transplantation (or graft surgery) may be the only option.

This procedure is usually performed under general anaesthesia. The keratoconic cornea is removed and a donor cornea (human tissue provided by the National Eye Bank after careful quality screening) is then sutured back in its place. A prolonged period of post operative care is required to ensure the graft remains healthy.



Corneal graft surgery



AUCKLAND EYE

SEE YOUR LIFE CHANGE



Auckland Eye is New Zealand's centre of excellence for eye care, with a totally tailored approach that provides the best possible outcome for patients. Our team of leading experts are highly trained in their specialist fields, providing assessment and management of a comprehensive range of eye conditions.

Combined with Oasis Surgical – Auckland's premier eye surgery facility – we offer superior treatment and world-class care in a relaxed, friendly environment. Both centres are independently accredited against EQUIP 5 standards for excellence in patient care and services.

Auckland Eye is centrally located in Remuera, with easy motorway access, plentiful off-street parking and wheelchair access. There are additional dedicated consulting facilities in Takapuna and New Lynn, as well as appointments available at a wide range of other locations across the Auckland region.

Auckland Eye is an affiliated provider to Southern Cross Health Society.

For more information on Keratoconus please contact our friendly specialist team.

AUCKLAND EYE SURGEONS



Dr Stephen Best
BSc, MBChB, FRANZCO
Remuera, Botany



Dr Stuart Carroll
MBChB, FRANZCO
Remuera, Silverdale, Takapuna



Dr Shenton Chew
BHB, MBChB, MD,
PGDipOphthBS, FRANZCO
Remuera, Takapuna, New Lynn



Dr Dean Corbett
BSc, MBChB, FRANZCO
Remuera, Takapuna, Orewa



Dr Archie McGeorge
MBChB, PhD, FRANZCO
Remuera, Takapuna, Orewa



Dr Justin Mora
MBChB, FRANZCO
Remuera, Papakura, Pukekohe,
New Lynn



Dr Yvonne Ng
MBChB, FRANZCO
Remuera, Botany, Henderson, Takapuna

AUCKLAND EYE SURGEONS



Dr Sue Ormonde
MBChB, MD, FRCOphth, FRANZCO
Remuera, Takapuna, Westgate



Dr David Pendergrast
MBChB, FRANZCO
Remuera, Papakura, Pukekohe



Dr Alison Pereira
MBChB, FRCOphth, FRANZCO
Remuera, Takapuna



Assoc. Prof. Philip Polkinghorne
MBChB, MD, FRANZCO, FRCOphth
Remuera, Papatoetoe, Whangarei



Dr Paul Rosser
MBChB, FRANZCO
Remuera, Albany, New Lynn



Dr Jo Sims
MBChB, FRANZCO
Remuera, New Lynn, Papatoetoe



Dr Sarah Welch
BSc, BMedSci, MBChB, FRANZCO
Remuera, New Lynn, Pukekohe