



**AUCKLANDEYE**  
Life Changing Eye Care

Auckland Eye is delighted to provide you The Auckland Eye Manual – a comprehensive ophthalmology diagnostic tool.

Part One covers taking an ophthalmic history and warning symptoms that arise, and signs to look for when conducting an ophthalmic examination. It also includes ten flowcharts covering the most common ophthalmic signs and symptoms as a guide to the various diseases which may be involved.

The fourteen chapters in Part Two describe the most common eye diseases. These chapters include a general description of each eye disease, their signs and symptoms, immediate and longer-term management, and referral guidelines. Chapters on the common eye problems include a more detailed commentary on the treatment, surgery and aids. The conditions are grouped into chapters based on the part of the eye affected i.e. Cornea, Retina, Orbit.

The book also includes a list of essential ophthalmic medications, a comprehensive glossary and a referral guide providing information about the specialists at Auckland Eye.

Auckland Eye is dedicated to providing excellence in ophthalmic care to all patients. The aim of this book is to act both as a reference guide and an update across all sub-specialty areas of eye disease along with providing recommendations on treatment and referral guidelines.

We hope you enjoy this book and that it is useful in everyday clinical practice.

***Auckland Eye***

# Auckland Eye

Auckland Eye is a premium eye specialist group in New Zealand. Our expert ophthalmologists deliver world class eye care.



Centre of excellence



State of the art technology



Widest range of sub-specialty services



Clinic locations Auckland-wide



Internationally renowned specialists



Dry Eye Clinic



NZ's leading private clinic



Clinical Research department

## Services

- General Ophthalmology
- Cataract
- Glaucoma
- Dry Eye Syndrome
- Red Eye
- Watery Eye
- Blepharitis
- Oculoplastic / Blepharoplasty
- Keratoconus
- Pterygium / Pinguecula
- Paediatrics
- Macular Degeneration
- Squints (Strabismus)
- Amblyopia
- Floaters & Flashes
- Retinal Tears & Detachment
- Diabetic Retinopathy
- Macular Holes
- Uveitis & Iritis
- Neuro-Ophthalmology

Want to see better – better see Auckland Eye

Q [aucklandeye.co.nz](http://aucklandeye.co.nz)  
e. [admin@aucklandeye.co.nz](mailto:admin@aucklandeye.co.nz)  
p. 0800 25 53 93



AUCKLANDEYE  
Life Changing Eye Care



The background features a dark blue gradient with intricate, wavy patterns. Red lines form a hexagonal mesh in the upper half, while blue lines form a similar mesh in the lower half. Scattered throughout are small, glowing blue and white particles, giving the impression of a digital or molecular structure.

## *Table of contents*



<b>1</b>	<b>Anatomy of the Eye</b>	<b>1</b>	6.2	Lid Lumps – Malignant	67
1.1	Anatomy of the Eye	2	6.3	Lower Lid Ectropion	69
<b>2</b>	<b>Ophthalmic History</b>	<b>5</b>	6.4	Lid Entropion	70
2.1	Change in vision	7	6.5	Ptosis – Acquired	71
2.2	Ocular discomfort	9	6.6	Trichiasis	73
2.3	Changes in ocular appearance	11	6.7	Watery Eye in the Adult	75
2.4	Other important aspects of history	14	6.8	Chalazion	77
<b>3</b>	<b>Ophthalmic Examination</b>	<b>16</b>	6.9	Upper Blepharoplasty	79
3.1	Assessment of vision	17	6.10	Lower Eyelid Rejuvenation	81
3.2	Assessment of anterior segment	18	<b>7</b>	<b>Conjunctivita</b>	<b>83</b>
3.3	Assessment of posterior segment	20	7.1	Blepharitis	84
3.4	Pupillary examination	21	7.2	Dry Eye	86
3.5	Assessment of eye movements	22	7.3	Allergic Conjunctivitis	88
3.6	Assessment of visual fields	24	7.4	Bacterial Conjunctivitis	91
3.7	Lids, lacrimal and orbit	25	7.5	Adenovirus Conjunctivitis	93
3.8	Paediatric examination	27	7.6	Chlamydial Conjunctivitis	95
<b>4</b>	<b>Ophthalmic Symptoms &amp; Signs</b>	<b>29</b>	7.7	Pingueculum and Pterygium	97
4.1	Acute Red Eye	30	7.8	Ocular Surface Squamous Neoplasia	99
4.2	Watery Eye	32	7.9	Pigmented Conjunctival Lesions	101
4.3	Sudden/Recent Loss of Vision	34	7.10	Ocular Cicatricial Pemphigoid	103
4.4	Gradual Loss of Vision	36	7.11	Stevens Johnson Syndrome	105
4.5	Visual Disturbances	38	<b>8</b>	<b>Cornea</b>	<b>107</b>
4.6	Double Vision	40	8.1	Bacterial Keratitis	108
4.7	Headache	42	8.2	Herpes Simplex Keratitis	110
4.8	Pupil Abnormalities	44	8.3	Herpes Zoster Keratitis	113
<b>5</b>	<b>Trauma</b>	<b>48</b>	8.4	Acanthamoeba Keratitis	115
5.1	Chemical Injury	49	8.5	Fungal Keratitis	117
5.2	Corneal Abrasions	51	8.6	Marginal Keratitis	119
5.3	Corneal Foreign Bodies	53	8.7	Peripheral Ulcerative Keratitis	121
5.4	Blunt Trauma	55	8.8	Recurrent Erosion Syndrome	123
5.5	Traumatic Hyphaema	57	8.9	Exposure Keratopathy	125
5.6	Penetrating Eye Injury	59	8.10	Neurotrophic Keratitis	127
5.7	Canalicular Trauma	61	8.11	Corneal Ectasias	129
5.8	Orbital Fractures	62	8.12	Keratoconus	130
<b>6</b>	<b>Lids</b>	<b>64</b>	8.13	Corneal Dystrophies	132
6.1	Lid Lumps – Benign	65	8.14	Deposition Keratopathies	135
			8.15	Contact Lenses	136
			8.16	Corneal Transplants ( <i>Grafts</i> )	139
			<b>9</b>	<b>Sclera</b>	<b>143</b>
			9.1	Episcleritis	144
			9.2	Anterior Scleritis	146
			9.3	Posterior Scleritis	148

<b>10</b>	<b>Cataract</b>	<b>150</b>	13.11	Diabetic Retinopathy	224
10.1	Cataract types	151	13.12	Retinal Artery Occlusion	226
10.2	Cataract Surgery	153	13.13	Branch Retinal Vein Occlusion ( <i>BRVO</i> )	228
10.3	Intraocular Lenses ( <i>IOLs</i> )	156	13.14	Central Retinal Vein Occlusion ( <i>CRVO</i> )	229
<b>11</b>	<b>Glaucoma</b>	<b>159</b>	13.15	Hypertensive Retinopathy	231
11.1	Primary Open Angle Glaucoma	160	13.16	Radiation Retinopathy	233
11.2	Primary Open Angle Glaucoma – Investigations	163	13.17	Toxic Retinopathies	235
11.3	Primary Open Angle Glaucoma – Management	165	13.18	Haematological Disease and the Retina	237
11.4	Secondary glaucoma	168	13.19	Cystoid Macular Oedema	239
11.5	Acute Angle Closure Glaucoma	170	13.20	Central Serous Chorioretinopathy ( <i>CSR</i> )	241
11.6	Glaucoma surgery	172	13.21	Choroidal Folds	243
<b>12</b>	<b>Uveitis</b>	<b>176</b>	13.22	Degenerative Myopia	244
12.1	Acute Anterior Uveitis	177	13.23	Retinal Dystrophies	245
12.2	Chronic Anterior Uveitis	179	13.24	Retinitis Pigmentosa ( <i>RP</i> )	247
12.3	Intermediate Uveitis	181	<b>14</b>	<b>Orbit</b>	<b>249</b>
12.4	Infectious Uveitis – Fungal	183	14.1	Orbital Cellulitis	250
12.5	Viral Uveitis	184	14.2	Orbital Inflammation	252
12.6	Endogenous Endophthalmitis	187	14.3	Orbital Cystic Lesions	254
12.7	Toxoplasma Chorioretinitis	189	14.4	Orbital Vascular Lesions	256
12.8	Retinal Vaculitis	191	14.5	Thyroid Eye Disease	258
12.9	Sarcoidosis	193	14.6	Orbital Tumours	260
12.10	Behcet's Disease	195	<b>15</b>	<b>Uvea</b>	<b>262</b>
12.11	White Dot Syndromes	197	15.1	Iris Melanomas	263
12.12	Masquerade Syndromes	199	15.2	Other Iris Lesions	265
12.13	Vogt Koyanagi Harada Disease	201	15.3	Choroidal Naevus	267
12.14	Sympathetic Ophthalmia	203	15.4	Choroid Melanoma	269
12.15	Uveitis in an Immunocompromised Patient	205	15.5	Capillary Haemangioma of the Retina ( <i>von Hippel-Lindau Disease</i> )	271
<b>13</b>	<b>Retina</b>	<b>207</b>	15.6	Retinal Pigment Epithelium Tumours	273
13.1	Posterior Vitreous Detachment ( <i>PVD</i> )	208	15.7	Primary Intraocular Lymphoma	274
13.2	Retinal Breaks	210	<b>16</b>	<b>Neuro</b>	<b>276</b>
13.3	Rhegmatogenous Retinal Detachment	212	16.1	Optic Neuritis	277
13.4	Other Types of Retinal Detachment	214	16.2	Anterior Ischaemic Optic Neuropathy	279
13.5	Epiretinal Membranes ( <i>ERM</i> )	216	16.3	Giant Cell Arteritis	280
13.6	Macular Hole	218	16.4	Papilloedema	282
13.7	Retinoschisis	219	16.5	Idiopathic Intra-Cranial Hypertension ( <i>IIH</i> )	284
13.8	Surgical Techniques	220	16.6	Chiasmal Lesions/Syndromes	286
13.9	Vitrectomy	221	16.7	Retrochiasmal Lesions	288
13.10	Age-Related Macular Degeneration ( <i>AMD</i> )	222	16.8	Migraine	290
			16.9	Supranuclear Paresis ( <i>Palsy</i> )	291
			16.10	Third Nerve Palsy	292
			16.11	Fourth Nerve Palsy	294

16.12	Sixth Nerve Palsy	296	20	<b>Focusing</b>	352
16.13	Adie's Tonic Pupil Defect	298	20.1	Myopia ( <i>Short Sighted</i> )	353
16.14	Horner's Syndrome	299	20.2	Hyperopia/Hypermétropia( <i>Long Sighted</i> )	355
16.15	Nystagmus	300	20.3	Astigmatism	356
16.16	Myasthenia Gravis	301	20.4	Presbyopia = "Near vision failure"	357
16.17	Blepharospasm ( <i>Benign essential Ocular Blepharospasm</i> )	303	20.5	Laser In-Situ Keratomileusis ( <i>LASIK</i> )	358
17	<b>Oncology</b>	304	20.6	Small Incision Lenticule Extraction ( <i>SMILE</i> )	360
17.1	Ocular Oncology	305	20.7	Photo Refractive Keratectomy ( <i>PRK</i> )	362
18	<b>Orthoptics</b>	311	20.8	Phakic Intraocular Lenses ( <i>Phakic IOLs</i> )	364
18.1	Orthoptic assessment	312	20.9	Refractive Lens Exchange ( <i>Clear Lens Extraction</i> )	366
19	<b>Paediatrics</b>	313	20.10	Intacs and Kerarings	367
19.1	Amblyopia	314	21	<b>Other Areas of Expertise</b>	369
19.2	Childhood Esotropias	316	21.1	Auckland Eye Clinical Research	370
19.3	Childhood Exotropias	318	21.2	Dry Eye Clinic	372
19.4	Strabismus Syndromes	320	22	<b>Medications</b>	375
19.5	Strabismus Surgery	322	23.1	Glaucoma	376
19.6	The Child Who Does Not See	326	23.2	Steroid	379
19.7	Vision Problems – Overview	327	23.3	Non-Steroidals	380
19.8	Watery Eyes in Children	329	23.4	Antibiotics	381
19.9	Blinking Eyes	331	23.5	Mydriatics and Cycloplegics	382
19.10	Abnormally sized eye	332	23.6	Ocular Lubricants	383
19.11	Childhood Nystagmus	333	23.7	Ocular Decongestants	384
19.12	Congenital Ptosis	335	23.8	Ocular Anti-Allergy	385
19.13	Paediatric Orbital and Preseptal Cellulitis	336	23.9	Intravitreal	386
19.14	Ophthalmia Neonatorum	337	23.10	Cytotoxic Drugs	387
19.15	Cloudy Cornea and Leukocoria	338	23.11	Drops Used for Examination	387
19.16	Congenital Cataract	340	25	<b>Glossary and Index</b>	389
19.17	Glaucoma in Children	342	26	<b>Referral Guide</b>	416
19.18	Albinism	343	26.1	Auckland Eye specialists	417
19.19	Uveitis in Children	344	26.4	Doctors and their specialties	423
19.20	Retinoblastoma	345	26.2	Auckland Eye locations	424
19.21	Retinopathy of Prematurity ( <i>ROP</i> )	346	26.3	Referrals	434
19.22	Optic Nerve Hypoplasia	348	26.5	Locations and Offerings	435
19.23	Phakomatoses	349			
19.24	Child Abuse/Non-Accidental Injury ( <i>NAI</i> )	350			
19.25	Dyslexia and Learning Disorders	351			



# Cataract Surgery & Lifestyle Lens

## Transform Your Life with Cataract Surgery

Cataract removal is one of the most common eye operations performed in New Zealand, renowned for its safety and effectiveness, with a success rate exceeding 98%.

Cataract surgery offers a transformative solution, replacing blurred vision with crystal-clear sight. Restore the vibrancy of your surroundings and ensure your vision aligns with your lifestyle needs.



Auckland Eye is accredited by the DAA Group for quality of patient care, so you can be confident you are in the safest possible hands.

## Your eyes do not have to act their age

Curious about which cataract surgery option is right?

Our expert team is here to guide you every step of the way.

Take the first step towards a brighter, clearer future.


Q [aucklandeye.co.nz](https://aucklandeye.co.nz)  
e. [admin@aucklandeye.co.nz](mailto:admin@aucklandeye.co.nz)  
p. 0800 25 53 93



AUCKLANDEYE  
Life Changing Eye Care



## 2 *Ophthalmic History*



As with any medical history, the goals of the ophthalmic assessment are to help develop a differential diagnosis and identify any “red flag” symptoms that alert the clinician to potentially urgent problems.

While a full eye evaluation is made easier with specialised equipment, such as a slit lamp, a reasonable differential diagnosis can be formulated from the clinical history alone. The symptoms described by the patient can be helpful in coming to this point, and common symptoms and causes are outlined below:



# 2.1 Change in vision

## Timing of visual changes

Timing of visual changes helps determine cause and severity.

Gradual worsening of vision is less likely to be associated with a serious underlying problem, and more likely to be indicative of treatable pathology such as cataract. In patients who have had cataract surgery, it may indicate formation of posterior capsular opacity, which is readily treatable with laser.

It is important to ask whether any specific symptoms are present, such as distortion (as this suggests there is a problem with the central retina/macula) or any visual field defect (suggesting either a neurological problem or a peripheral retinal problem). These problems need to be dealt with far more urgently.

Sudden changes in vision should always be treated seriously and be referred promptly for a further opinion. It is likely that the patient has either developed a retinal problem or optic nerve problem if there is a sudden and dramatic decrease in vision. This may affect the eye alone, or could occur as part of a systemic problem, e.g. giant cell arteritis (GCA) presenting with an acute ischaemic optic neuropathy. Early diagnosis and intervention can be important for salvaging vision, protecting the fellow eye, and protecting general health and circulation.

## Frequency of visual changes

Intermittent fluctuations in vision can be a warning sign before a more significant problem develops, and generally should be referred for review.

Symptom	Causes	Red flag symptoms
Central loss of vision	Age-related macular degeneration (AMD) Central serous retinopathy	Sudden decrease in central vision in elderly, especially if distortion present
Distortion	Central serous chorioretinopathy "Wet" age-related macular degeneration	Sudden onset distortion in older patient
Double vision (diplopia)	Monocular: cataract Binocular: cranial nerve palsy, thyroid eye disease	Symptoms of giant cell arteritis (GCA) Painful headache (posterior communicating artery aneurysm)

Symptom	Causes	Red flag symptoms
<b>Floaters and flashes</b>	Posterior vitreous detachment Retinal detachment Uveitis	"Curtain" in vision (can mean retinal detachment present) Eye pain (uveitis)
<b>Halo</b>	Angle closure glaucoma (ACG) Corneal scar or haze	Halo more in dim lighting (ACG)
<b>Peripheral loss of vision</b>	Retinal detachment Retinitis pigmentosa Glaucoma	Progressive field loss, floaters and flashes
<b>Subacute loss of vision (over a few hours or days)</b>	Optic neuritis Retinal detachment (can progress like a curtain over vision) Uveitis Angle closure glaucoma	Severe pain, nausea (ACG)
<b>Sudden monocular loss of vision</b>	Retinal detachment (often floaters first) Central retinal artery occlusion Central retinal vein occlusion Anterior ischaemic (or non-ischaemic) optic neuropathy	Symptoms of GCA
<b>Transient loss of vision: bilateral</b>	Transient ischaemic attack Ocular migraine Papilloedema: can be posture- related, lasts seconds	Other associated neuro symptoms Morning headaches, vomiting
<b>Transient loss of vision: monocular</b>	Amaurosis fugax (TIA) Tear film debris (clears with blink)	Jaw claudication, headache, background of polymyalgia

## 2.2 Ocular discomfort

### Timing

Timing of symptoms can help generate a differential diagnosis.

#### Symptoms worse on waking:

- Sudden onset of eye pain on waking suggests a corneal erosion
- Headaches and nausea suspicious for raised intracranial pressure

#### Symptoms worse later in day, or when reading or working on computer:

- Ocular surface problems, such as dryness or blepharitis (as the eye “dries out” when concentrating and blinking less)
- Uncorrected refractive error/focusing error
- Diplopia that gets worse as the day wears on or later in the day can be indicative of underlying extraocular muscle imbalance
- If diplopia is associated with ptosis this is suggestive of Myasthenia Gravis

#### Symptoms worse in dark:

- Aching pain with haloes seen at night may indicate the patient has narrow angles and is at risk of angle closure glaucoma

#### Symptoms worse in light:

- Uveitis
- Corneal ulcers

#### Symptoms worse with changes in environment, such as air conditioning:

- Ocular surface problems, such as dryness, blepharitis, allergy

### Frequency

Serious causes of ocular discomfort will give constant rather than intermittent symptoms. Problems such as corneal ulcers, angle closure glaucoma or uveitis do not resolve without specific treatment.



### Associated symptoms

If a patient presents with ocular discomfort it is important to determine the presence or absence of other symptoms such as visual change, as this is more likely to signify a serious problem. Eye discomfort associated with reduction in vision should always be treated seriously, particularly if the symptoms develop over a short timeframe.

Symptom	Causes	Red flag symptoms
Aching pain and tenderness	Uveitis Angle closure glaucoma Scleritis	Nausea and vomiting (ACG) Decrease in vision Severe pain
Burning discomfort	Blepharitis Dry eye Conjunctivitis	Change in vision, severe pain
Foreign body sensation	Foreign body Corneal abrasion or ulcer Trichiasis (misdirected lashes) Blepharitis	History of corneal ulcers Contact lens wear
Glare	Dry eyes Corneal problems including scars near visual axis Cataract (particularly posterior subcapsular)	Nil
Headache	Non-ocular causes, e.g. migraine, sinusitis Uveitis Scleritis Angle closure glaucoma	Decrease in vision, severe tenderness
Pain on eye movements	Optic neuritis Myositis or orbital inflammation Non-ocular causes, e.g. flu, sinusitis	Associated decrease in vision (suggests inflammation around optic nerve)
Photophobia	Dry eye (usually mild photophobia) Uveitis	Change in vision, ache, abrupt onset (uveitis more likely)

Symptom	Causes	Red flag symptoms
Red eye	Conjunctivitis Corneal ulcer Uveitis Scleritis, episcleritis Angle closure glaucoma Inflamed pterygium	Decrease in vision, severe pain (uveitis, ACG, corneal ulcers, scleritis)
Sticky eyes	Conjunctivitis (especially bacterial) Nasolacrimal duct obstruction	Nil
Watery eye	Conjunctivitis Lid problems, e.g. ectropion Nasolacrimal duct obstruction	Nil

## 2.3 Changes in ocular appearance

Patients may complain of changes in ocular appearance that are cosmetic concerns only (although may still be important to deal with from this perspective) or can be associated with functional problems, such as a ptosis interfering with vision.

Changes in eye appearance can occasionally herald serious underlying pathology, such as orbital tumours and the history and examination can help determine whether this is a possibility.

### Timing

Serious problems, such as orbital cellulitis, aggressive tumours or cranial nerve palsies, usually have a quicker onset of symptoms and signs than more indolent eye problems.

Common age-related problems, such as aponeurotic (age-related) ptosis or ectropion, will come on over months to years.

Problems, such as ptosis or strabismus, in children are often present from early in life. If there are concerns that a new problem has developed it can be useful to get history from other family members or even to look at old photographs.

Frequency

Intermittent changes in eye appearance are not very common. However, they can occur in certain conditions. Myasthenia Gravis is a rare cause of ptosis and may fluctuate with fatigue, and patients may also have intermittent diplopia.

Certain types of childhood strabismus, in particular intermittent exotropia, can be seen more when the child is tired.

Associated symptoms

In general, if a change in eye appearance is also associated with any change in vision then this is more likely to be a serious concern. Examples would include sudden onset of unilateral ptosis accompanied by diplopia, such as in a patient with third nerve palsy.

Symptom	Causes	Red flag symptoms
Abnormal head posture (AHP)	Fourth nerve palsy Other childhood strabismus, e.g. Brown's syndrome Non-ocular causes e.g. torticollis	Sudden onset of AHP plus diplopia
Crossed or wandering eyes	Childhood strabismus Cranial nerve palsy (III, IV, VI) Thyroid eye disease	Sudden onset of eye movement problem (cranial nerve palsy more likely) Ptosis (third nerve) New headache
Droopy lids	Age-related "aponeurotic" ptosis Congenital ptosis Dermatochalasis Third nerve palsy Horner's syndrome	Unilateral ptosis with double vision (third nerve palsy) Ptosis in young child that interferes with visual axis
Symptom	Causes	Red flag symptoms
Lid malposition	Ectropion Entropion	Entropion with severe pain (corneal ulceration)
Prominent eye	Thyroid eye disease Orbital tumours High myopia	Change in vision (may be optic nerve compression) All patients with suspected proptosis need investigation

Symptom	Causes	Red flag symptoms
Red eye	Conjunctivitis Corneal ulcer Uveitis Scleritis, episcleritis Acute glaucoma	Decrease in vision, severe pain (uveitis, ACG, corneal ulcers, scleritis)
Shrinking eye	Ptosis giving appearance of small eye Proptosis of other eye	All patients with suspected proptosis need investigation
Swollen lids	Thyroid eye disease Preseptal cellulitis Orbital cellulitis	Fever, reduced vision, double vision (cellulitis, thyroid eye disease)
Unequal pupils	Horner's syndrome (affected pupil smaller) Third nerve palsy (pupil larger) Pharmacological (pupil larger) Adie's pupil	Headache, ptosis and new eye deviation (third nerve palsy)

## 2.4 Other important aspects of history

### Ocular trauma

The mechanism of trauma can help determine likelihood of serious problems being present.

Chemical injury should always be treated as an ocular emergency, with immediate prolonged irrigation of the eye before any further assessment is performed. Alkali is more serious than acid injury.

High-velocity trauma, either sharp or blunt, has the potential to cause a penetrating eye injury or eye rupture. Common examples would be a punch to the eye, sports injury, or assault with an object.

Dust or other foreign material falling, blowing or being rubbed into the eye can cause corneal abrasion, but if it is not a high velocity injury there is no risk of a penetrating injury.

### Systems enquiry

This is particularly important for patients with inflammatory eye conditions, such as uveitis or scleritis, as the ocular inflammation is the presenting feature of an underlying autoimmune problem in up to 20% of cases. Important conditions that can present in this way include Behcet's syndrome, Wegener's granulomatosis, and ankylosing spondylitis.

### Other aspects

Other aspects of the clinical history, such as past medical history, medication history and allergies, are obviously also important as they are with any medical exam in terms of assessing risk of particular eye problems (e.g. diabetic retinopathy in poorly controlled diabetic) and safety of treatments.

# Research

Join the future of eye care with our expertise in Clinical Research

Auckland Eye specialises in phase 2-4 clinical trials, showcasing our extensive expertise and commitment to innovation. With exceptional patient recruitment and retention, you can trust that your patient is in good hands.

Be a pioneer in eye care, through our international research partnerships, our patients are among the first in the world to experience life-changing devices and procedures.

## Explore Our Subspecialty Areas:

- Anterior Segment / Cornea
- Cataract / Lens Replacement
- Dry Eye
- Glaucoma
- Neuro-Ophthalmology
- Oculoplastics
- Ocular Oncology
- Retina / Uveitis
- Strabismus / Pediatrics



Find a list of our latest clinical trials on our website <https://www.aucklandeye.co.nz/research-clinical-trials/>

Together, let's shape the future of vision health!

Q [aucklandeye.co.nz](https://www.aucklandeye.co.nz)  
e. [admin@aucklandeye.co.nz](mailto:admin@aucklandeye.co.nz)  
p. 0800 25 53 93



AUCKLANDEYE  
Life Changing Eye Care





## 3     *Ophthalmic Examination*

## 3.1 Assessment of vision

- Snellen visual acuity – measurement of distance vision.

### Tips

- Use a chart at the distance for which it is designed
- Measure the distance from the patient to the chart and mark it, so it is consistent each time
- Use a high-contrast, well-lit chart

### Method

- Ensure the patient has their distance glasses on
- Cover one eye
- Have them read the lowest line they can without mistakes. Push them to read the next line but stop if it is incorrect.
- Use a pinhole to see if the vision improves. The pinhole will correct for refractive error (i.e. patient needs new glasses) and to some extent cataract.
- Cover the other eye and test with and without pinhole

### Record vision as follows

- Distance from chart at top, e.g. 4 (m)
- Line number from the chart on the bottom, e.g. 8
- Thus this person's visual acuity recorded for one eye is: 4/8
- On most charts there is correlation to 6 m chart readings, which in this case would be 6/12

### Near vision

- Use a near-vision chart
- Ensure the chart is well lit
- Get the patient to hold it at a comfortable reading distance – approx. 30 cm
- Ensure patient is wearing reading glasses
- Test one eye at a time
- Record near vision as smallest type easily read as marked on chart, e.g. N5

### Colour vision

- A change in colour vision may be an early indication of optic nerve dysfunction
- A rough guide to uni-ocular colour vision change is the "red desaturation test":
  - Show the patient a red object and ensure they see it as red with both eyes open.

(e.g. red pen)

- Say: *If this red is 100% then is it the same 100% out of each eye?*
  - Get them to look at object out of one eye then the other and score it out of 100%
  - If one eye sees the object as significantly less red then that eye may have optic nerve dysfunction
- To formally test colour vision use an Ishihara colour test book
  - Test one eye at a time
  - Record the number of correct plates over the number of plates tested

## 3.2 Assessment of anterior segment

### Tips

Most external eye and anterior segment findings can be seen using a bright pen torch and a magnifying loupe or a direct ophthalmoscope.

The direct ophthalmoscope can be used to obtain a magnified view of the surface of the eye and of the red reflex. "10" on the dial will give focus at about 10 cm – adjust as needed for sharp focus. This will enable a close view of the cornea and any other anterior structures, as well as a bright and sharp red reflex to examine for cataract or other media opacity.

Use blue light to enhance fluorescein dye. Most direct ophthalmoscopes can be set for blue illumination.

Slit lamp examination allows estimation of the depth of lesions in the transparent surfaces of the eye (e.g. is a lesion on the corneal surface, within the aqueous, or in the lens), and allows visualisation of microscopic changes, such as red blood cells or inflammatory cells in the aqueous.

Examine the structures of the eye in an orderly manner – from the outside in.

### Conjunctiva

The conjunctiva includes the palpebral conjunctiva (under the lids), the limbal conjunctiva (adjacent to the cornea) and the bulbar conjunctiva (on the globe). Each part should be examined carefully.

#### Palpebral conjunctiva

This can be examined by everting the eyelid over a cotton bud. Look for inflammation, papillae (allergic), follicles (viral), granulomas, and foreign bodies.

#### Limbal conjunctiva

Look for degenerative changes like pterygium and pingueculum. Ciliary injection (marked hyperaemia of the conjunctiva by the cornea) is a sign of corneal or intraocular inflammation.

### **Bulbar conjunctiva**

Ask the patient to look in various directions to expose all the areas of bulbar conjunctiva.

#### **Look for:**

- Chemosis (swelling of the conjunctiva, most commonly caused by allergy)
- Hyperaemia or injection (i.e. a marked increase in dilation and number of conjunctival blood vessels is a non-specific sign of allergy, infection, trauma or inflammation)
- Subconjunctival haemorrhage (confluent bright red patch of blood with no marks of vessels)

### **Cornea**

Examine for foreign bodies, epithelial defects (seen by instilling a drop of fluorescein stain and viewing with a blue light), stromal infiltrates (white patches), corneal swelling (hazy cornea), corneal laceration (may be associated with a shallow anterior chamber due to aqueous leak or irregular pupil due to iris entrapment).

### **Anterior chamber**

The anterior chamber (AC) is best examined with a slit lamp. However, hyphaema (blood in the AC, seen as a red fluid collection in the inferior part of the AC) or hypopyon (pus in the AC, seen as a white or yellow fluid level in the inferior AC) can be seen macroscopically.

On the slit lamp, anterior chamber inflammation may produce inflammatory cells, seen either floating in the aqueous or settled on the inside of the cornea, seen as opaque spots (keratic precipitates).

### **Iris and pupil**

Check the reactivity of the pupil. The pupil should be round, reactive and symmetrical with the other pupil.

The iris colour should be symmetrical with the other eye and even; uneven areas of colouring or thickness may be suggestive of cysts or tumours. Inflammation in the AC suggests iris inflammation.

### **Lens**

Cataract may be visible as a shadow in the red reflex, best seen with the direct ophthalmoscope. Advanced cataract may be visible as a white pupil.

## 3.3 Assessment of posterior segment

### Without slit lamp

#### Direct Ophthalmoscope

An ophthalmoscope gives direct visualisation of the posterior pole of the eye but with a relatively small field of view. The view is substantially improved by dilating the pupil. Use one or two drops of mydriacyl (tropicamide) because of its relatively short action.

The direct ophthalmoscope has settings for both illumination and focus. Illumination settings include different apertures of light beam, as well as green and blue filters for enhanced visualisation of blood vessels and of fluorescein stain (on the surface of the eye) respectively. Focus settings allow a wide range of plus or minus lenses to be used to compensate for both the patient and examiner's refractive errors if present, as well as allowing close focus for surface examination (see Assessment of anterior segment, previous page). If there is no refractive error the dial should be set on "0".

To obtain the best possible view the examiner's eye and ophthalmoscope should approach the patient's eye as closely as possible. Use your own right eye to examine the patient's right eye, left for left. With the patient fixating on a distant object, begin at about half a metre away, and 15 degrees to the side. By steadily approaching the pupil it should be possible to visualise the optic nerve on this axis, and other nearby structures by following major vessels from the nerve. Because of the narrow field of view it is difficult to see the peripheral retina, and orientation away from the major vessels becomes difficult. To look at the macula ask the patient to look directly at the light.

#### Indirect ophthalmoscope

The indirect ophthalmoscope gives a lower magnification but broader view of the posterior segment. It almost always requires pupil dilation, and requires considerable experience to use. It gives an inverted image, but much wider field of view, which assists in orientation as well as viewing the peripheral retina. The extreme peripheries (retinal tears, etc.) are usually visualised by a combination of the indirect ophthalmoscope and indentation of the sclera.

### With slit lamp

At the slit lamp the posterior pole of the eye can be visualised with hand-held condensing lenses. Pupil dilation is very helpful, and considerable experience is required to see the retina. This is the optimal means for examining the optic disc and macula because of the combination of wide field and high magnification,

which can be obtained. The image is inverted, and somewhat less wide than the indirect ophthalmoscope.

### Other modalities

Specialised imaging techniques include:

- Fundus photography, which can be standard or wide field
- Fluorescein angiography and indocyanine green angiography to examine the circulation of the retina and assess for pathology in the choroid
- Optical coherence tomography (OCT) and OCT angiography show the anatomical structure of the retina, the pigment equilibrium and the choroid.
- When there is no view due to dense cataract or hemorrhage, B-scan ultrasound examination is required..

## 3.4 Pupillary examination

The key signs of pupil examination are size, shape and reactivity to light.

### Size

In ambient light both pupils should be of equal size. However, physiological anisocoria (unequal pupil size) is present in up to 15% of the population. This is benign and often best picked up on photos.

Conditions that cause anisocoria include:

- trauma (traumatic mydriasis – the affected pupil is often larger)
- surgery (the affected pupil may be smaller or larger)
- iritis (the affected pupil may be small and irregular)
- angle closure (mid-dilated pupil)
- pharmacological agents (the most common cause of dilated pupils)
- neurological causes – e.g. third nerve palsy (dilated pupil) or Horner's syndrome (small pupil)

### Shape

An irregularly shaped pupil may be seen after trauma, surgery or uveitis. Often it is long-standing and does not need further investigation. If it is a new finding then the eye should be examined more fully.

### Reactivity to light

In most cases the pupils should constrict equally to light stimulus and dilate equally in the dark. The “swinging flashlight test” is an objective test of the afferent visual pathway. It compares the pupillary light reflex response between both eyes. A difference in the response is called a “Relative Afferent Pupillary Defect” (RAPD). If there is an RAPD then the affected eye is failing to transmit messages to the



brain (there is an interruption in the afferent pathway), caused by either major retinal damage or optic nerve pathology.

#### **How to test for an RAPD**

1. Ask the patient to gaze across the room
2. Dim the lights
3. Use a bright light
4. Shine the light at the one eye and observe the direct response of that eye (pupil should constrict)
5. Move the light quickly to the other eye and observe the direct response of the second eye (pupil should stay constricted)
6. Observe the contralateral eye with each swing of the light. In the normal situation both eyes should constrict equally

#### **If there is an RAPD**

1. The affected eye dilates with the light and the contralateral eye also dilates
2. When the light is moved back to the unaffected eye, both pupils should constrict

Note: a difference in size in the pupils – anisocoria – does not imply an RAPD.

### **3.5 Assessment of eye movements**

Each eye is moved by 6 muscles – the 4 recti and 2 obliques. To keep the eyes aligned and moving together involves a complex system of co-ordination within the brainstem and requires normal visual function of both eyes, as well as functioning muscles and their associated nerves: cranial nerves 3, 4 and 6.

If the eyes do not move together even if all the muscles and their nerves are functioning this is called concomitant strabismus and is the type of strabismus most commonly seen in children. Paralytic strabismus occurs when one or more of the cranial nerves is not functioning, causing loss of function of the associated extraocular muscle. Restrictive strabismus is associated with abnormal muscles, e.g. in thyroid eye disease or tumours interfering with the normal eye movements.

The following diagram demonstrates the fields of action of the extraocular muscles.

## Tips

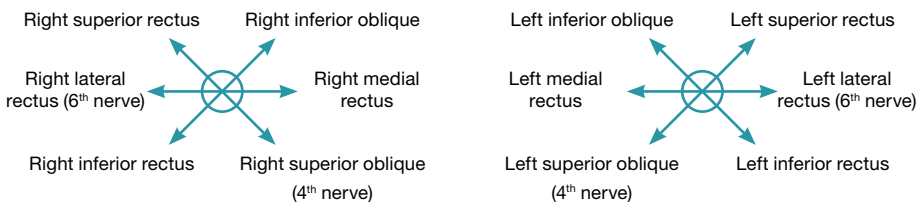
- Ask whether the patient has diplopia; is it vertical or horizontal?
- Does the diplopia change depending on the direction they look?
- In a sixth nerve palsy the affected eye turns in
- In a third nerve palsy the affected eye is down and out, the lid may be down and the pupil may be large
- In a fourth nerve palsy the affected eye is slightly higher than the other eye
- Is there a history of trauma, thyroid problems or headache?

## Examination

- Examine first in central gaze – so-called primary position
- Get patient to focus on a far target – e.g. Snellen acuity chart
  - Do the eyes appear to be aligned?
  - Is one eye turned out, up, in or down?
- **Get the patient to focus on a near target**
  - Are the eyes aligned?
- **Move the near target slowly to each of the 6 positions of gaze:**
  - Left, right, up and right, up and left, down and right, down and left
- Check the lid position – is there ptosis (drooping lid – cranial nerve 3), or lid retraction (thyroid eye disease)
- Check the pupils – a dilated pupil with third nerve palsy needs urgent referral
- **Look for evidence** of a mass causing restriction of movement
- Look for protrusion of the eyes – proptosis, common in thyroid eye disease

## Urgent referral

A patient with a third nerve palsy; ptosis, eye down and out and dilated pupil is a medical emergency, especially if they have headache. They need urgent referral to hospital for neuro-imaging. The most likely cause is a posterior communicating artery aneurysm that is at risk of rupture causing sub-arachnoid haemorrhage and consequent morbidity or mortality.



## 3.6 Assessment of visual fields

Visual field testing measures the extent of peripheral (or side) vision and is often overlooked as part of the ophthalmic examination. The most common conditions that affect the visual fields are glaucoma and neuro-ophthalmic disease. Visual field testing is usually performed for each eye alone, but for driving assessment it is performed with both eyes together.

A normal visual field usually extends approximately 60 degrees nasally, 110 degrees temporally and 90 degrees both superiorly and inferiorly. The physiologic blind spot is located around 15 degrees temporally on the horizontal and is usually about 5 degrees in diameter. It can become enlarged with conditions that cause swelling of the optic nerve head, such as papilloedema.

### Visual field examination

#### 1. Manual confrontation visual field testing

The examiner sits 1–2 m opposite from the patient who is asked to cover their left eye.

The examiner then closes their own right eye and asks the patient to fixate on their left eye. Thus the patient and examiner look directly into their uncovered eyes. The examiner then compares their own visual field to that of the patients (assuming the examiner's visual field is normal!).

There are a variety of comparisons that can be made, including counting fingers in each quadrant (static testing), moving fingers (kinetic testing), or by asking a direct comparison as to the appearance of one hand to the other held up on either side of the vertical midline. For example, patients with a homonymous hemianopia from a CVA will note that one hand appears to be normal whilst the other is indistinct.

Perhaps the best method of confrontation visual field testing uses a red object, such as a red-topped dropper bottle, which is moved from the far periphery towards the centre of the field. The patient is asked to identify when it is first seen as red. The visual field of the left eye is then tested in the same fashion.

### Tips

- Ensure the target is an equal distance from the examiner and the patient.
- Ensure both the patient and the examiner are sitting so that their eyelines are approximately level.
- Watch the patient's eye to ensure they keep looking straight ahead and don't "cheat" by looking at the target.

#### 2. Instrument testing of visual fields: termed "perimetry"

##### A. **Goldmann – operator assisted perimetry**

The patient is asked to look into a large hemisphere (ganzfield bowl), which is painted matt white. One eye is patched so that the monocular field is

measured. The operator manually moves a projected white target and records the patient's response to create "isopter" lines, which are similar to contour lines on a topographical map. This is a kinetic threshold test as the target light is moving. This instrument is now seldom used as automated perimetry has superseded it.

#### **B. Automated perimetry**

The patient looks into a similar large matt white bowl, and a computer generates specific patterns of projected light across the visual field and the patient's responses are recorded. The most commonly used machine is the Humphrey Visual Field Analyser. It uses a variety of testing paradigms suitable for different conditions. Other machines used include Oculus, Octopus, Medmont, Matrix and Frequency Doubling Technology (FDT).

Computer-automated perimetry is repeatable, reliable and allows more accurate determination of disease progression. It is most commonly used to monitor patients with glaucoma.

To test fitness to drive, the Esterman program, an automated binocular visual field test, is used to check that the horizontal field exceeds 140 degrees.

## **3.7 Lids, lacrimal and orbit**

### **Eyelid**

Most conditions of the lids relate to either benign or malignant masses, or abnormalities of position.

#### **Lid position**

The normal position of the upper lid is 1–2 mm below the superior limbus, while the lower lid should sit at the inferior limbus. With lid retraction, as seen in facial palsy or dysthyroid eye disease, the upper lid sits higher and the lower lid lower than the normal positions. In both of these conditions there may be lagophthalmos (incomplete lid closure) and reduced closure with blinking.

With ptosis the upper eyelid sits lower than normal.

The eyelid margins should sit accurately against the corneas. An inturned lid (entropion) directs the lashes against the cornea, which may cause abrasions and discomfort. Ectropion (out-turned lower lid) may cause a watery eye and there is often red, inflamed conjunctiva inferiorly and accompanying punctal stenosis.

The eyelid needs to be examined from both the anterior (skin) and posterior (conjunctival) aspects. The lid margin should be regular with a normally positioned and regular array of eyelashes. Destruction of the margin and/or

loss of lashes (madarosis) can be signs of a malignant tumour. Benign lesions generally don't cause lash destruction.

### Lacrimal

The tears are conducted along the lid margins with each blink into the upper and lower puncta. Normal eyelid position and function is important in maintaining good tear clearance. Punctal stenosis/narrowing commonly occurs with age and will cause a raised tear film or tear overflow.

Tear drainage can be assessed by instilling fluorescein drops into the eye and checking after 5 minutes as most of the dye should have disappeared. Having the patient blow their nose will usually, in a functioning system, reveal the presence of fluorescein.

Syringing fluid along the canaliculi will demonstrate anatomical patency but this is not a physiological test. With total nasolacrimal duct obstruction a lacrimal sac mucocoele may be present and, in this situation, pressing over the sac will often produce mucous regurgitation from one or both punctae. A lacrimal system X-ray (dacryocystogram) is useful in determining whether there is a partial nasolacrimal duct obstruction.

### Orbit

Because of the orbital contents being surrounded by bony walls, most orbital conditions cause the eye to be displaced forwards (proptosis). This displacement may be "axial", in which the eye comes directly forward (i.e. optic nerve tumour), or "non-axial", when the eye is displaced also to one side (i.e. sinus mucocoele). In marked proptosis there may be limitation of eyelid closure and the corneal health needs to be considered in these cases.

Occasionally enophthalmos can occur in orbital disease, such as with sclerosing breast metastasis or from trauma causing blow-out fractures.

Infections, inflammations and masses will generally cause secondary problems from interference in function of other orbital tissues. Diplopia from extraocular muscle involvement, reduced visual function from optic nerve compression and loss of sensation with neural interruption can all be seen. Lymphadenopathy involving the pre-auricular and sub-mandibular nodes should be checked for in cases of possible malignancy.

## 3.8 Paediatric examination

While many paediatric eye problems are similar to adult ones, treating and examining children has its own unique problems. Children cannot always tell us their symptoms or how well they see or not, and examining children can be more difficult, especially if they are uncooperative or pre-verbal.

### General observations

Observe the child noting: interactions with environment, visual behaviour, or abnormal head posture (this may occur when the child has diplopia and turns its head to a position where the diplopia is least or absent).

### Fixation behaviour

Show the child a small object. Is the child looking at a target with both eyes? Is fixation central, steady and maintained? Does the child follow the target if it is moved from side to side? Does the child object to occlusion of one eye? Are there involuntary eye movements, e.g. Nystagmus. Does one eye wander in or out when looking at the target?

### Visual acuity

Literate children can be tested as for adults with Snellen acuity charts. Pre-literate children that can talk can use “Kay Pictures” charts with different-sized pictures on them that correlate with Snellen acuity charts. Ensure these are used at the correct distance, in bright light and that each eye is well occluded.

For children that are pre-verbal use fixing and following information, and consider using small objects like hundreds and thousands for the child to pick up to give an indication of acuity in each eye. Once again, make sure each eye is completely occluded.

### Ocular alignment

Ask the parents if the eyes ever wander in or out. Use the fixation information as a guide as to whether the eyes are straight. Not all squints are present all the time



and so if there is a clear history of the eye turning in or out, even if it is not present on examination, then the child should be referred to an ophthalmologist.

### **Corneal light reflections**

Shine a light towards the child. Examine the position of the light reflection on each cornea. If the eyes are correctly aligned, the light reflexes are symmetrical and usually centred in the centre of the pupil of each eye.

### **Examination of the external eye**

Pay attention to symmetry of face, size of eyes (microphthalmos small eye/buphthalmos – large eye), lid position and contour, orbits (proptosis/enophthalmos).

### **Examination of the anterior segments**

Look for conjunctival inflammation, corneal clarity, pupils, anisocoria (different pupil sizes), direct light reflexes, relative afferent pupillary defect.

### **Red reflex examination**

Are the ocular media clear?

Dilate the pupils – <1 year old: Cyclopentolate 0.5% drops

>1 year old: Cyclopentolate 1% drops

Look through the direct ophthalmoscope at the pupils from ~30–40 cm away.

Focus the ophthalmoscope so that the pupil margin is seen clearly.

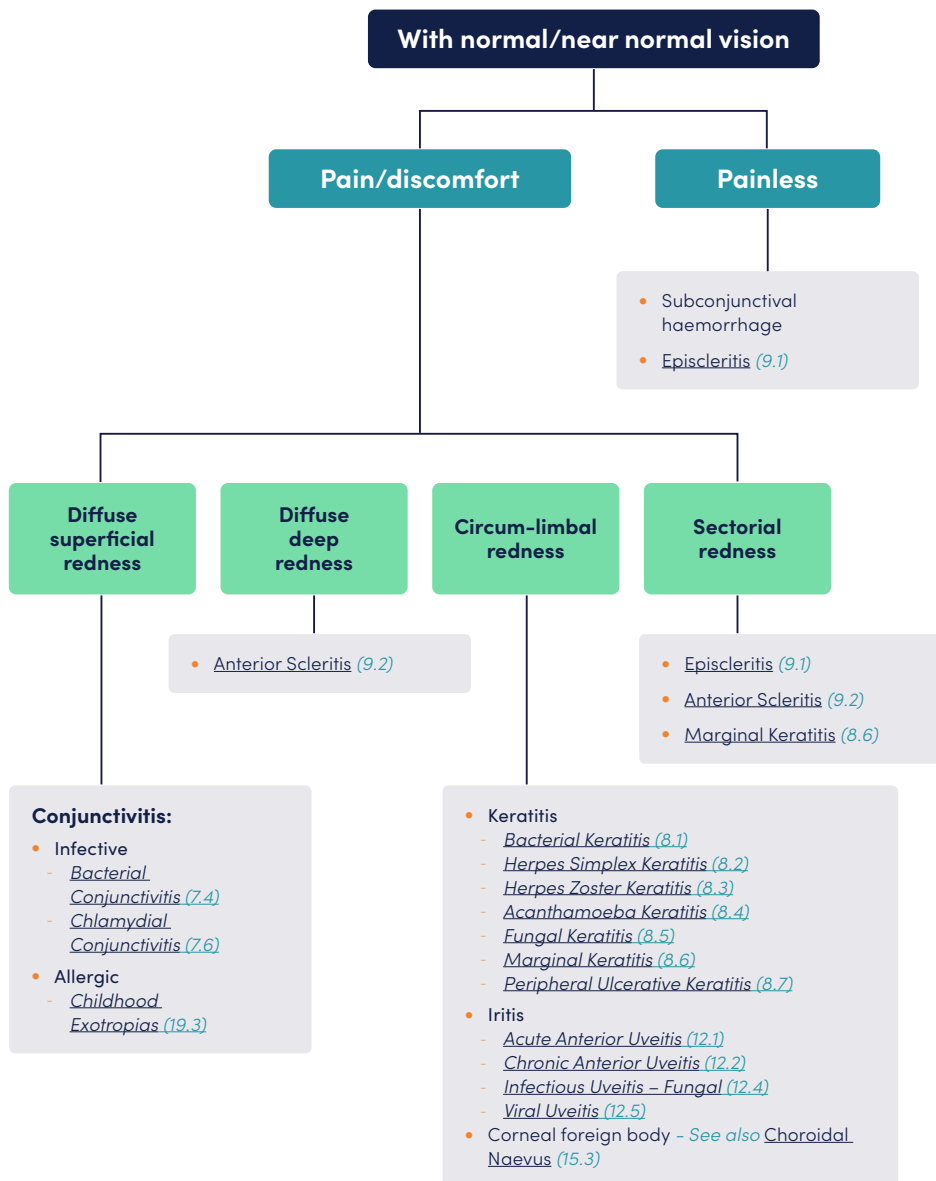
Media opacities in the cornea, aqueous, lens and vitreous will appear dark brown.



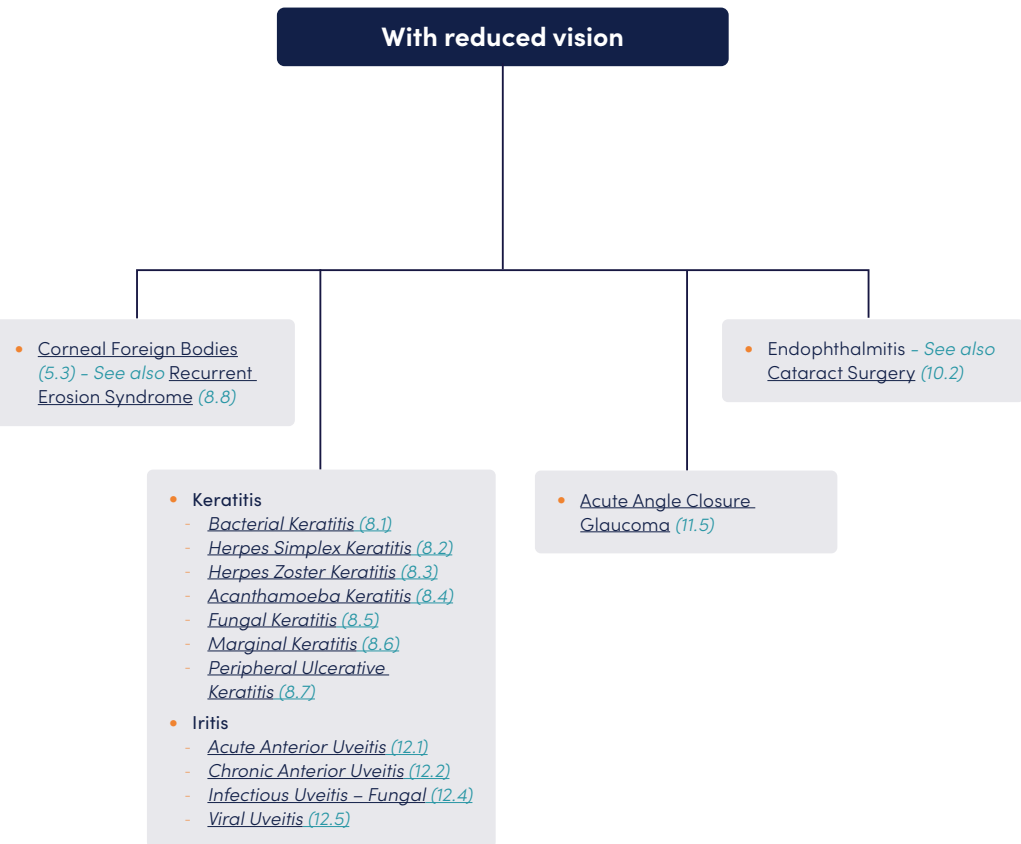
## 4 *Ophthalmic Symptoms & Signs*

## 4.1 Acute Red Eye

For best experience, view tables in two-page view

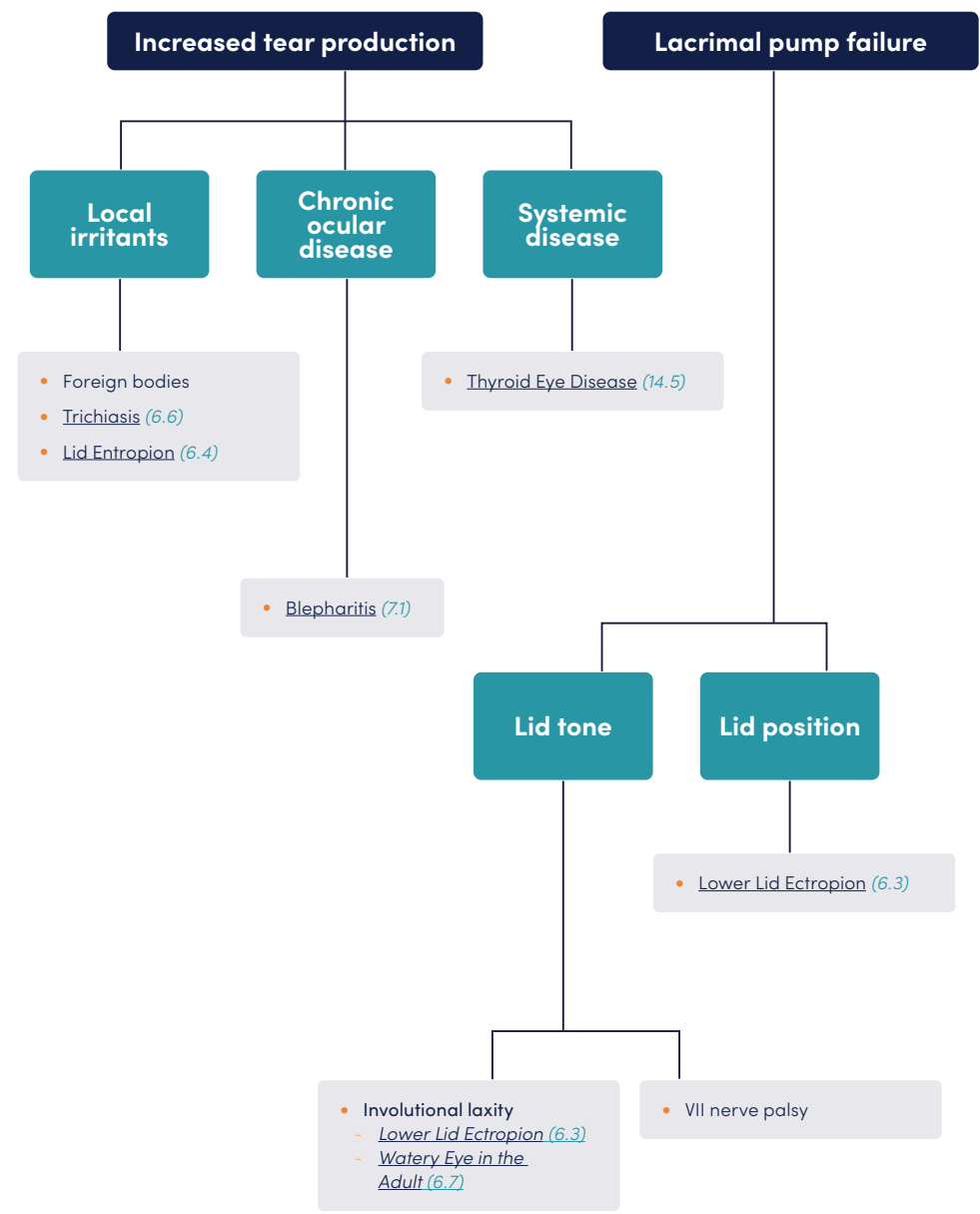


## Acute Red Eye (continued)

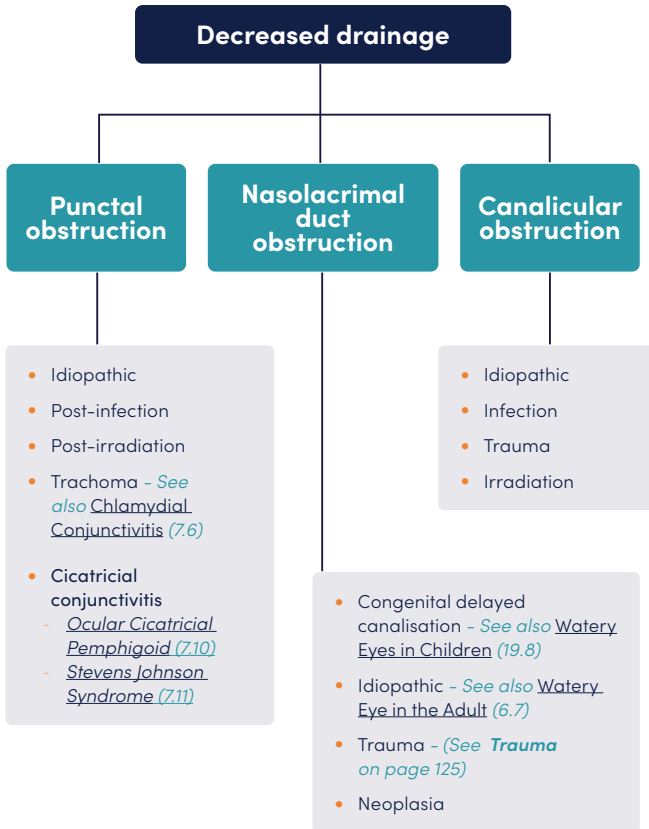


# 4.2 Watery Eye

For best experience, view tables in two-page view

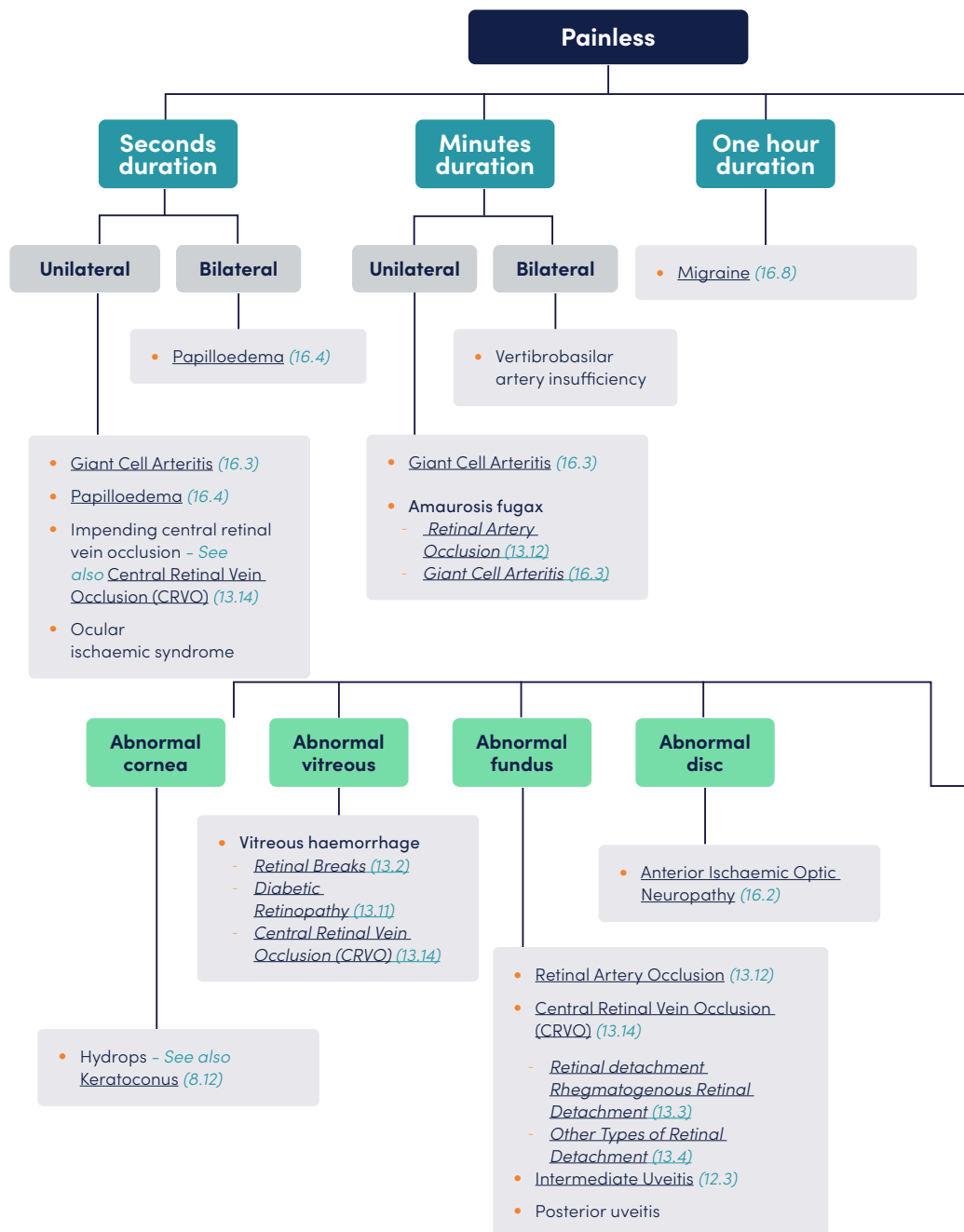


# Watery Eye (continued)

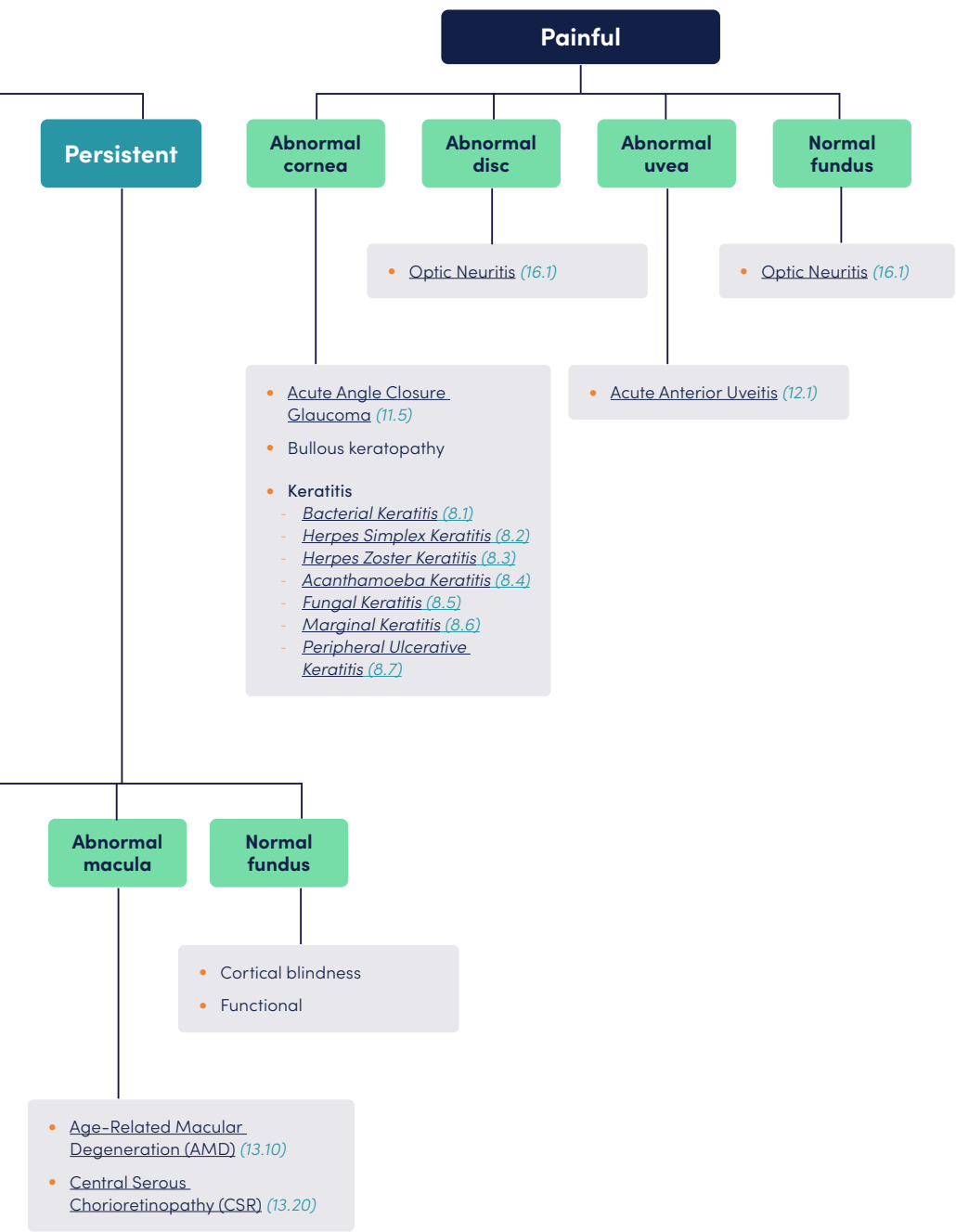


## 4.3 Sudden/Recent Loss of Vision

For best experience, view tables in two-page view



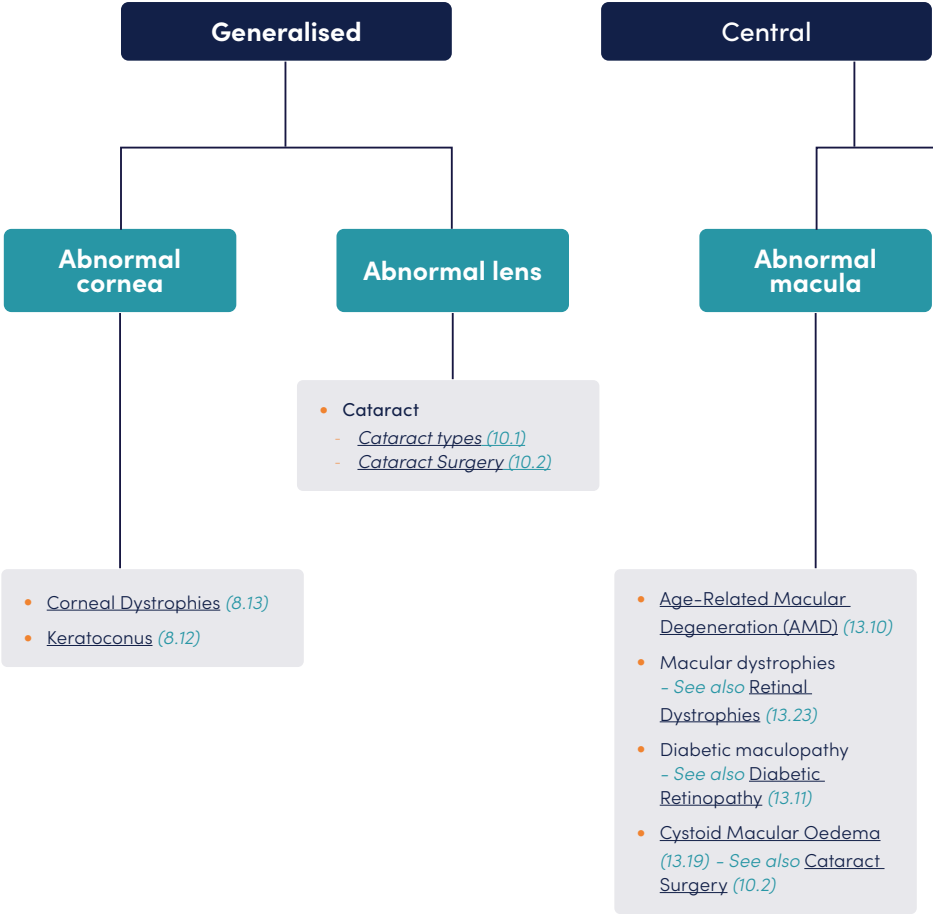
Sudden/Recent Loss of Vision (continued)



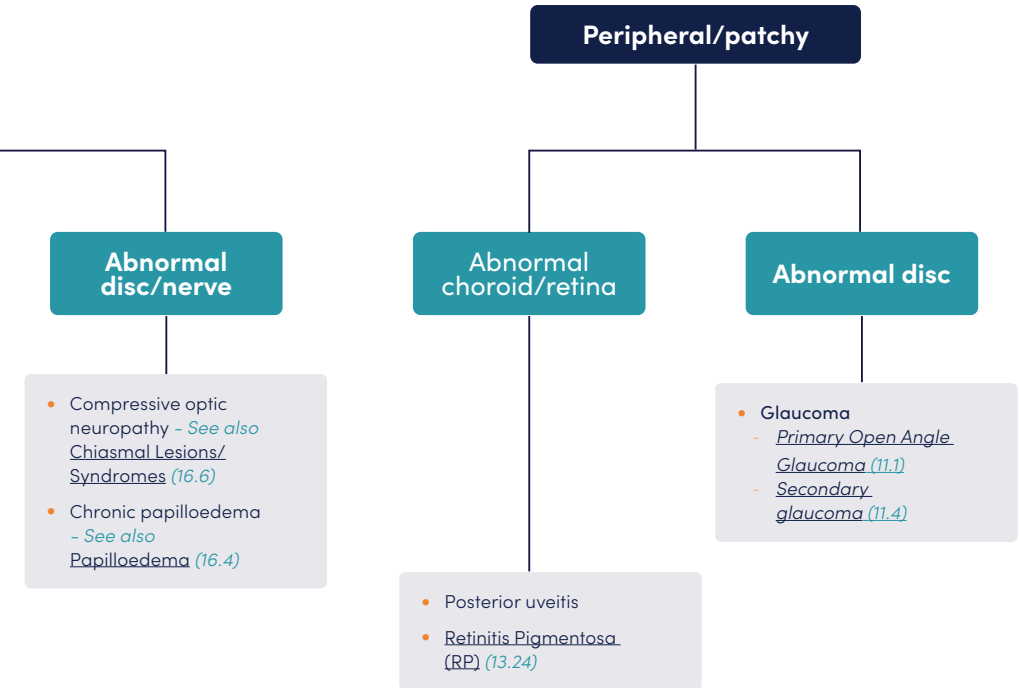


# 4.4 Gradual Loss of Vision

For best experience, view tables in two-page view

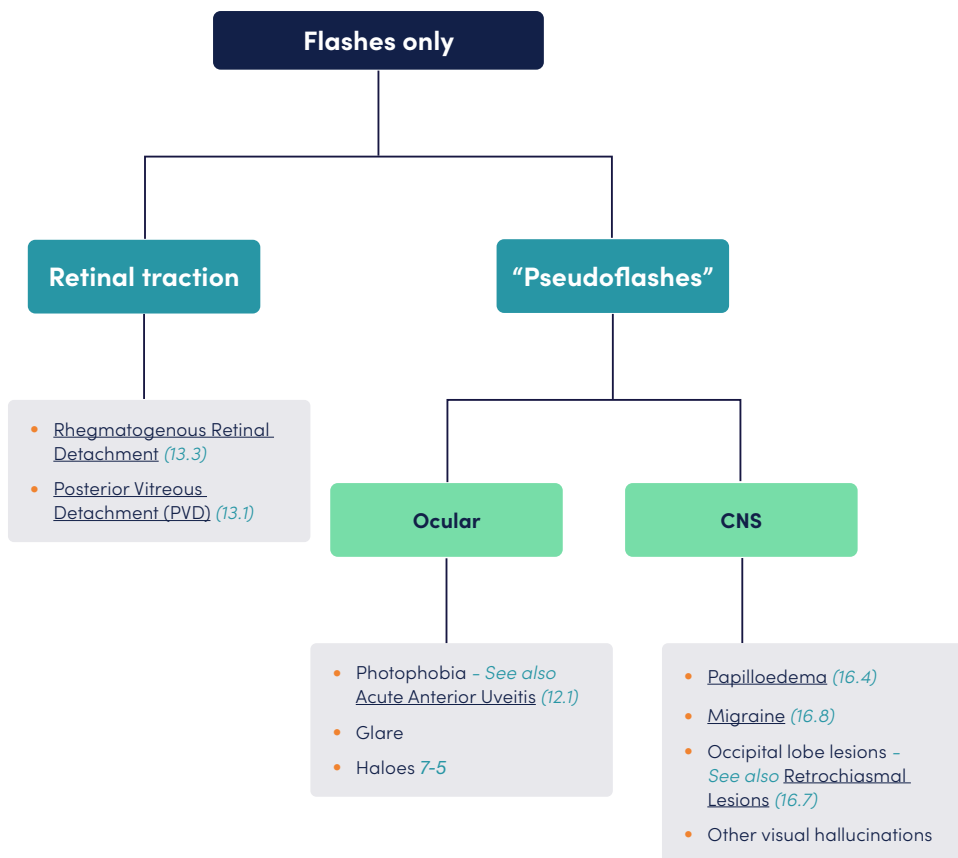


# Gradual Loss of Vision (continued)



## 4.5 Visual Disturbances

For best experience, view tables in two-page view



## Visual Disturbances (continued)

### Floaters only

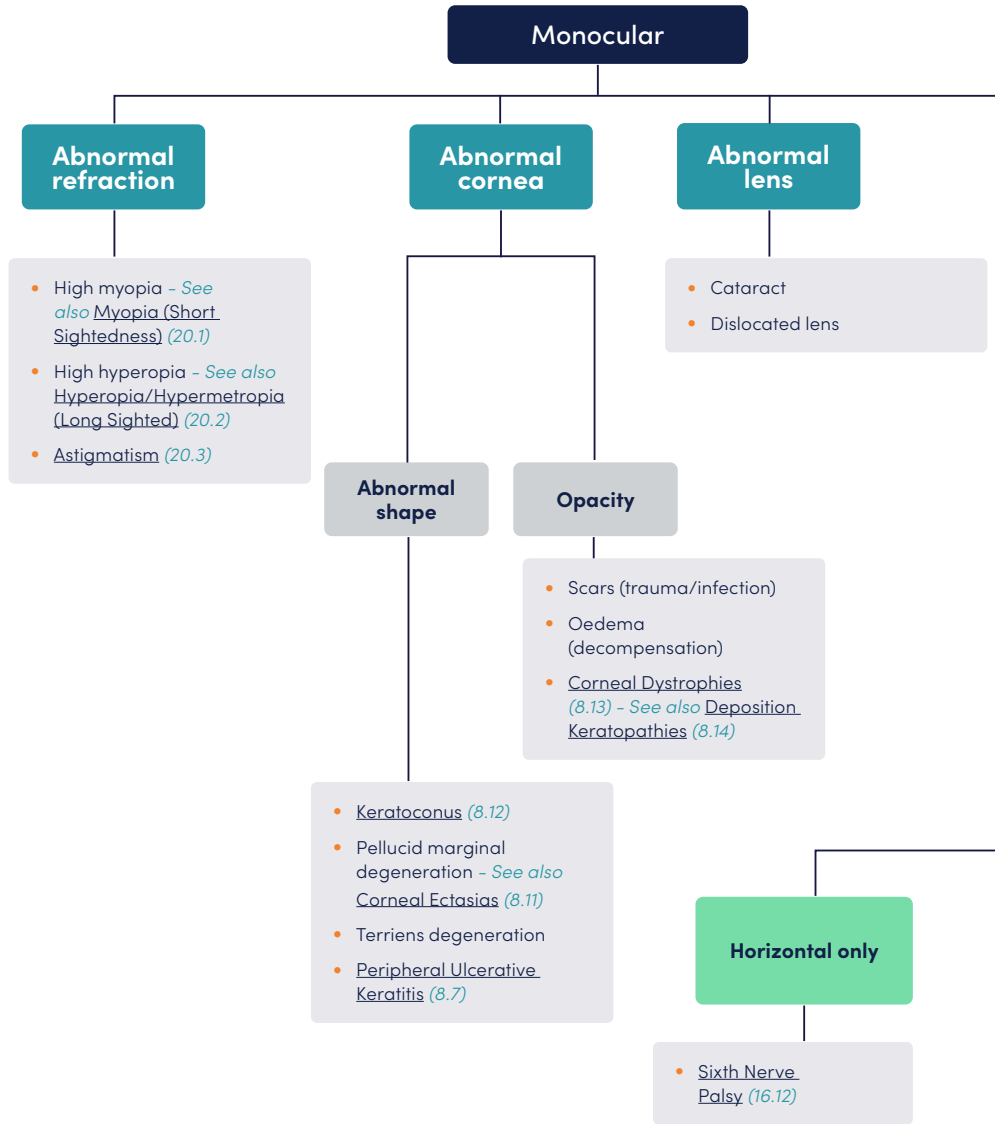
- Posterior Vitreous Detachment (PVD) (13.1)
- **Vitreous haemorrhage**
  - Retinal Breaks (13.2)
  - Diabetic Retinopathy (13.11)
  - Central Retinal Vein Occlusion (CRVO) (13.14)
- Intermediate Uveitis (12.3)
- Asteroid hyalosis
- Amyloidosis
- Tumours

### Flashes and floaters

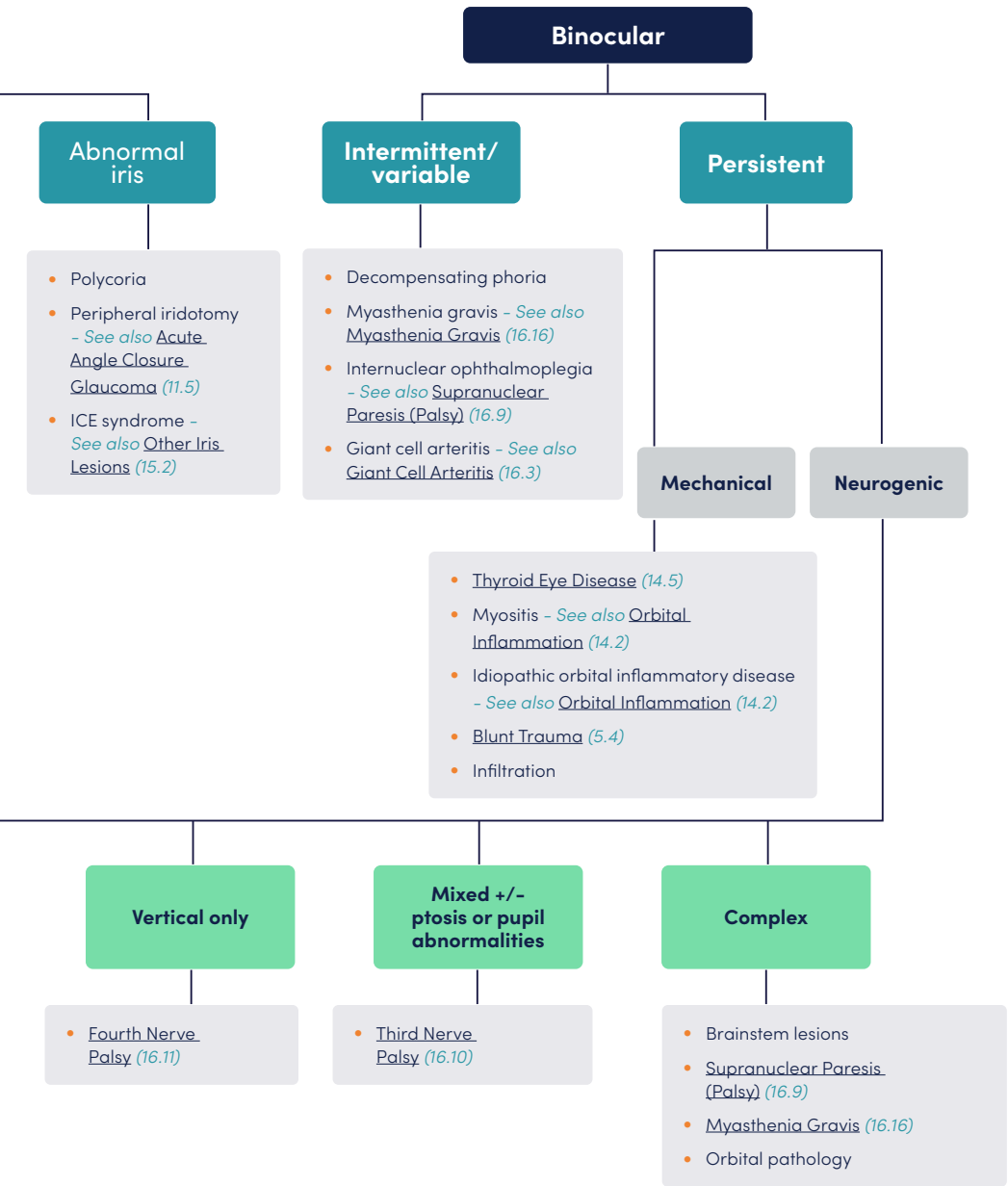
- Posterior Vitreous Detachment (PVD) (13.1)
- Retinal tear - *See also* Retinal Breaks (13.2)
- Rhegmatogenous Retinal Detachment (13.3)
- Tumours

# 4.6 Double Vision

For best experience, view tables in two-page view

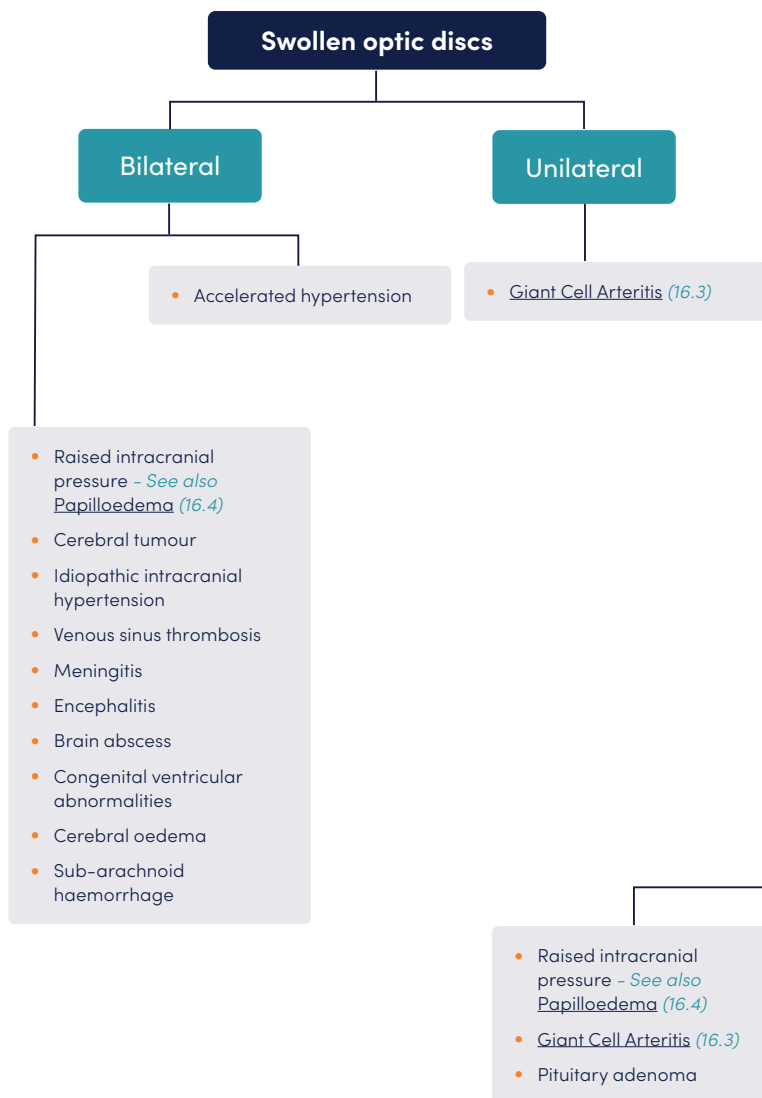


# Double Vision (continued)

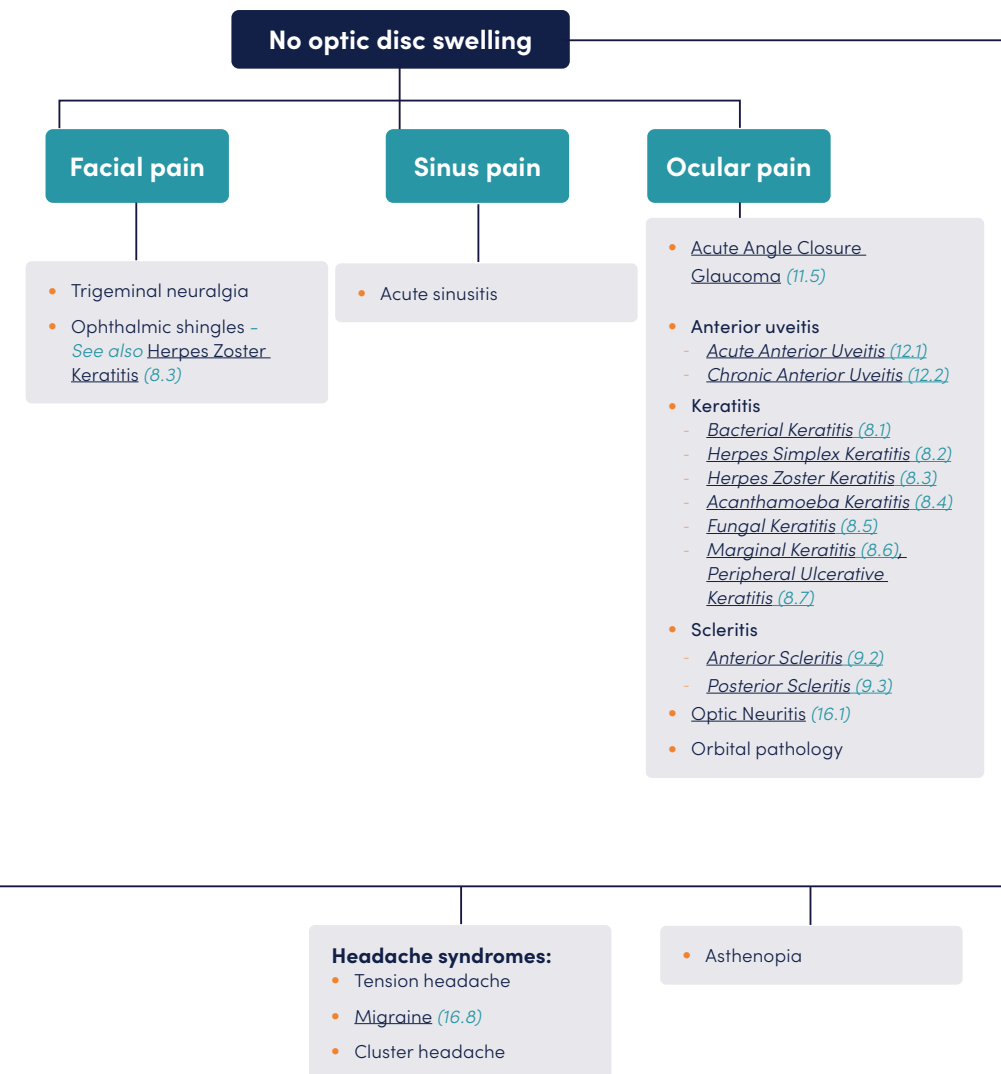


## 4.7 Headache

For best experience, view tables in two-page view



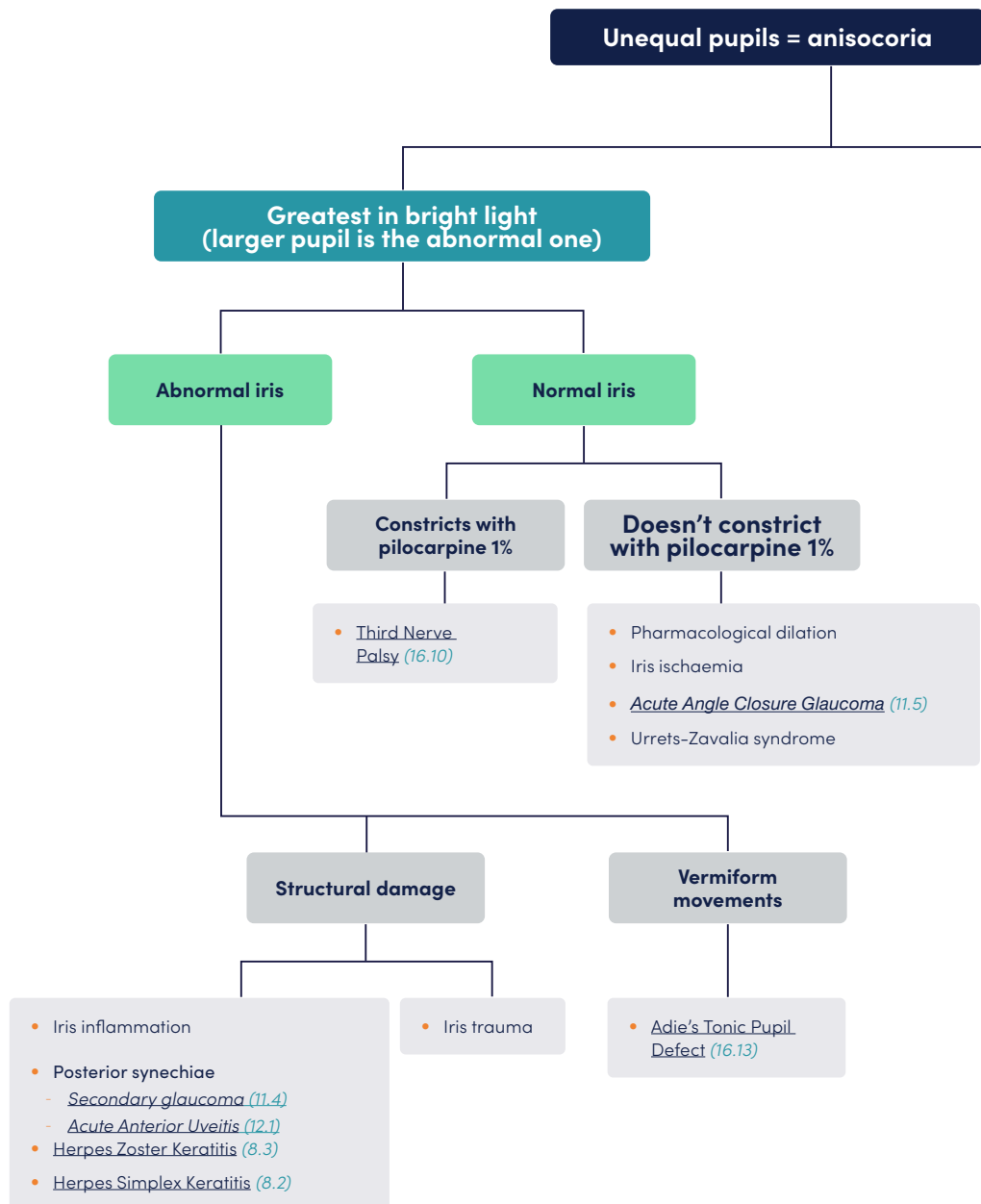
## Headache (continued)



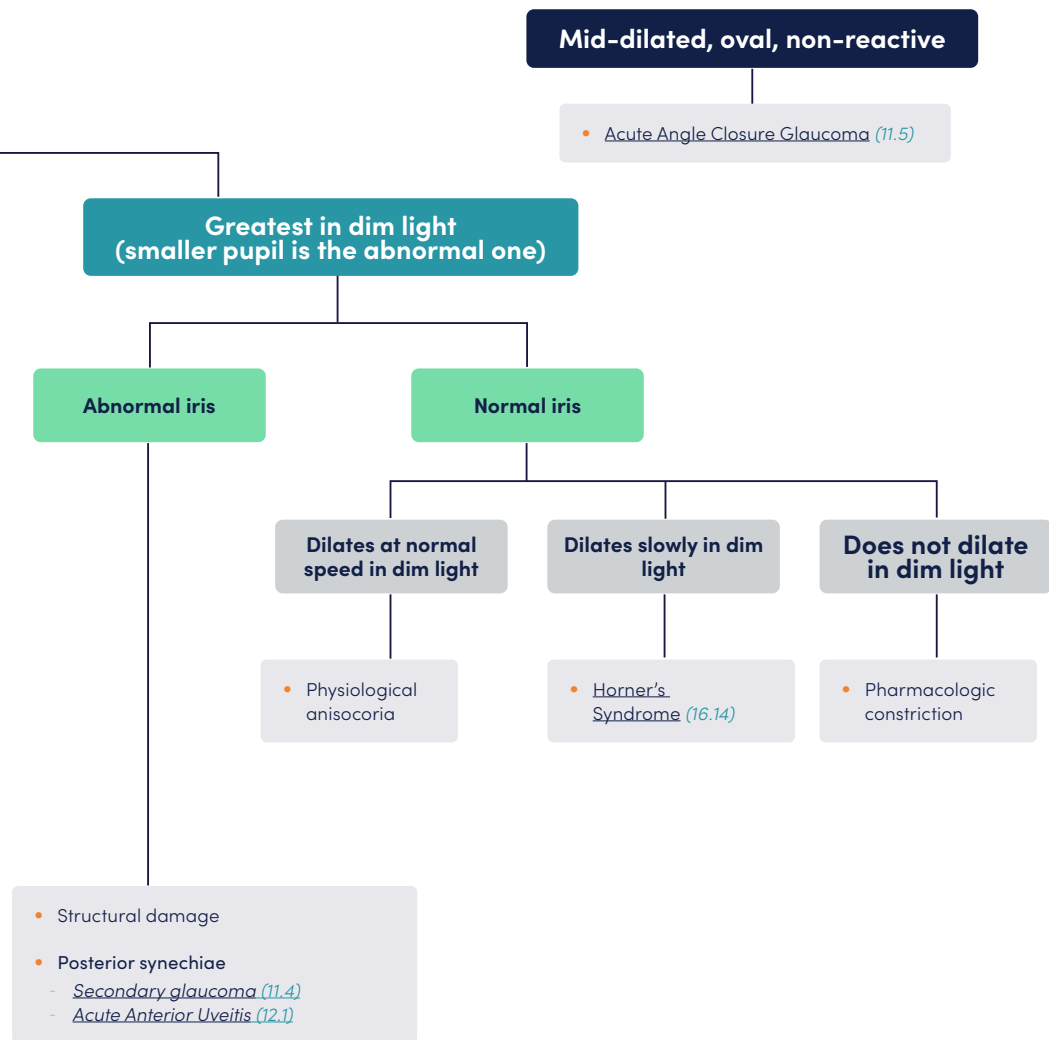


## 4.8 Pupil Abnormalities

For best experience, view tables in two-page view



## Pupil Abnormalities (continued)





# Aesthetics Clinic

## Embracing your individual nature of beauty

While we're renowned as Auckland's eye specialists, our state of the art facility in Remuera offers a comprehensive range of aesthetic treatments tailored just for you.



Anti-wrinkle injectables



Latest IPL technology



Medical grade skin care

Discover the secret to radiant skin with our expert team! Specialising in medical-grade skincare, the latest IPL technology, and anti-wrinkle injectables, we're here to help you embrace your unique beauty.

**Book your consultation today and let us help you shine!**

Q [aucklandeye.co.nz](https://aucklandeye.co.nz)  
e. [aesthetics@aucklandeye.co.nz](mailto:aesthetics@aucklandeye.co.nz)  
p. 0800 439 377



**AUCKLANDEYE**  
Life Changing Eye Care



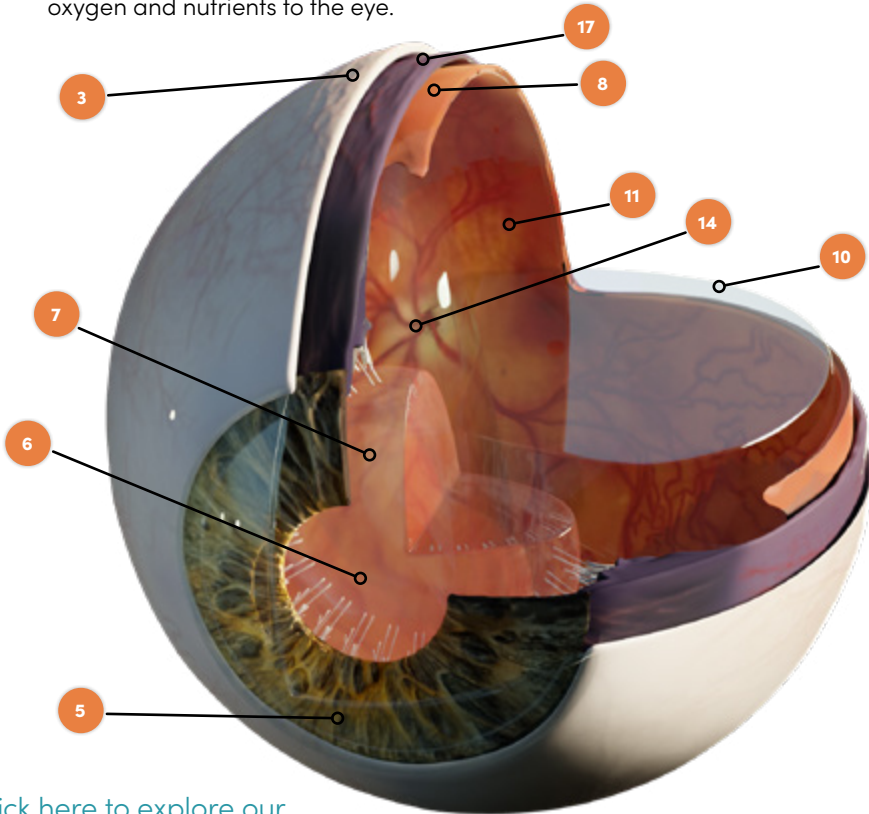
# 1 *Anatomy of the Eye*

## 1.1 Anatomy of the Eye


The human eye is a complex organ responsible for vision, composed of multiple structures that work together to focus light and convert it into neural signals processed by the brain. Here is a detailed overview of the key anatomical components:

1. **Cornea:** The clear, dome-shaped front surface of the eye that refracts light entering the eye.
2. **Conjunctiva:** The thin, transparent membrane covering the sclera and the inner surface of the eyelids, providing lubrication and protection.
3. **Sclera:** The white, fibrous outer layer of the eyeball that provides structure and protection.
4. **Anterior Chamber:** The fluid-filled space between the cornea and the iris, containing aqueous humour that nourishes the eye and maintains intraocular pressure (IOP).
5. **Iris:** The coloured part of the eye, consisting of muscular fibers that control the size of the pupil and regulate the amount of light entering the eye.
6. **Pupil:** The central opening of the iris that allows light to reach the lens. It dilates and constricts in response to light intensity.
7. **Lens:** A transparent structure that focuses light onto the retina. It changes shape to adjust focus for near and far objects (accommodation). The lens can develop *Cataract*, which are opacities that cloud the lens, leading to decreased vision.
8. **Ciliary Body:** A ring of tissue behind the iris that produces aqueous humour and controls lens shape for focusing. Dysfunction in the ciliary body can contribute to *Glaucoma*, a group of eye conditions that damage the optic nerve, often due to increased intraocular pressure.
9. **Posterior Chamber:** The small space between the iris and the lens, also filled with aqueous humour.
10. **Vitreous Body:** The clear, gel-like substance filling the space between the lens and the retina, helping maintain the eye's shape. Changes or clumping in the vitreous body can lead to floaters, small shadows or shapes seen in the field of vision.
11. **Retina:** The innermost layer of the eye, composed of photoreceptor cells (rods and cones) that detect light and convert it into electrical signals. The retina also contains several layers of neurons that process visual information. The retina is richly supplied with blood vessels, and conditions such as *Diabetic Retinopathy* can occur when these blood vessels are damaged.

- 12. **Rods:** Photoreceptors sensitive to low light levels, important for night vision.
- 13. **Cones:** Photoreceptors responsible for colour vision and visual acuity.
- 14. **Macula:** A small central area of the retina with a high concentration of cones, responsible for sharp, detailed central vision. The macula can be affected by *Age-Related Macular Degeneration (AMD)*, a condition that leads to loss of central vision.
- 15. **Optic Disc:** The region where the optic nerve exits the eye, lacking photoreceptors, creating a natural blind spot. Changes in the optic disc, such as increased cupping, can be indicative of *Glaucoma*, which can lead to optic nerve damage and vision loss.
- 16. **Optic Nerve:** The bundle of nerve fibers transmitting visual information from the retina to the brain.
- 17. **Choroid:** The vascular layer between the sclera and the retina, supplying oxygen and nutrients to the eye.



[Click here to explore our interactive eye model](#)



# Laser Surgery

**Your centre of excellence for laser eye surgery!**

At Auckland Eye we offer simple, yet long-term solutions for a wide range of common focusing problems. Our suite of safe and effective laser options includes SMILE Pro, LASIK, PRK and Presbyond.

With the confidence of knowing that each procedure is 100% customised to the patient, they can experience the life-changing benefits of laser eye surgery.



Auckland Eye is accredited by the DAA Group for quality of patient care, so you can be confident you are in the safest possible hands.

**Don't wait any longer! Discover the freedom of clear vision.**

Book a **FREE** consultation today and take the first step towards life changing eye care!

**Want to see better – better see Auckland Eye**

Q [aucklandeye.co.nz](http://aucklandeye.co.nz)  
e. [laser@aucklandeye.co.nz](mailto:laser@aucklandeye.co.nz)  
p. 0800 25 53 93



**AUCKLANDEYE**  
Life Changing Eye Care





## 5 *Trauma*



## 5.1 Chemical Injury

Chemical injuries represent the most urgent of all ophthalmic conditions and can be extremely destructive to the ocular surface.

Alkalis cause liquefactive necrosis and so can penetrate deeper into the eye. Conversely, acids cause coagulative necrosis and so impede their own progress into the eye. Irrespective, however, of the actual chemical involved, all chemical injuries are treated in the same way initially – by copious irrigation. It is important to note that chemical injuries are not always due to liquids, but can be vaporized agents, or even solid or particulate matter, such as concrete or lime.

### Symptoms

The patient is usually acutely aware of chemical injury to the eye, with significant pain, watering, and irritation, but very occasionally symptoms of pain and irritation may be somewhat delayed, particularly if a vaporised chemical is the causative agent. Patients usually present immediately but sometimes, especially in the case of milder injuries, there may be a delay of a day or two before presentation with patients only presenting when initial symptoms fail to settle spontaneously.

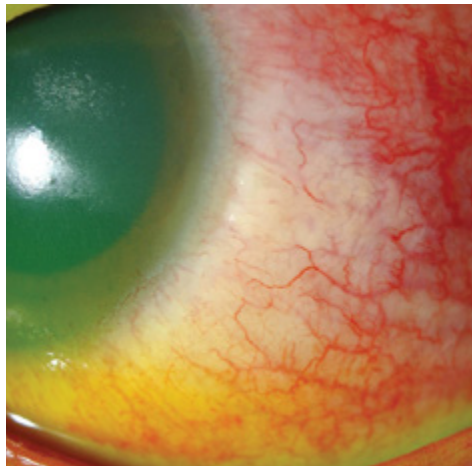
### Signs

- Redness: This is a variable sign. Very mild injuries may have very little redness, moderate injuries usually have significant redness, but paradoxically very white eyes often accompany severe injuries. This is because severe chemical injuries blanch the vessels in the conjunctiva and sclera.
- Variable fluorescein stain, from mild punctate stain to extensive corneal epithelial loss.
- Variable corneal cloudiness from clear in mild injuries to significant opaqueness in severe injuries.

### Slit lamp signs

As above, plus:

- Anterior chamber cells in moderate to severe injuries.
- Raised intraocular pressure.



Loss of conjunctival vessels causing whitening in an alkali burn.

## Immediate management

### IRRIGATE! IRRIGATE! IRRIGATE!

The prognosis of all chemical injuries is significantly dependent upon immediate irrigation. It is the single most important step in management and a delay of seconds can make a difference to the outcome. All chemical injuries should be copiously irrigated with water or a balanced salt solution. Do not waste time hunting for appropriate bags of fluid, or checking the ocular pH with litmus strips – go straight to irrigation with the nearest available water or saline. This may mean literally placing the patient's head underneath a tap or in a shower. Formal irrigation can take place subsequently, but the main aim is to achieve immediate dilution or removal of the chemical. It is important for concrete/lime/firework-type injuries to ensure all particulate matter is removed, and this requires eversion of the upper lid and careful sweeping of the upper and lower fornices with a cotton tip. Topical anaesthetic drops will aid the irrigation process but do not delay irrigation whilst looking for anaesthetic drops – commence irrigation first. When you think you have irrigated enough, irrigate some more.

## Long-term management

After copious irrigation, the following steps in management are aimed at reducing ensuing inflammation and facilitating healing. These subsequent treatments should be commenced from an ophthalmic emergency clinic.

- Steroid drops are used to reduce inflammation.
- Topical and oral ascorbic acid, topical citrate drops, and oral doxycycline are all used to reduce enzymatic destruction of tissue and aid new collagen synthesis.
- Antibiotic drops are used prophylactically until epithelial defects are healed.
- Topical and systemic intraocular pressure-lowering agents are used if intraocular pressure is raised.
- Topical lubricants can aid comfort and epithelial healing.
- In severe chemical injuries, amniotic membrane transplantation may be required to aid epithelial healing.
- Surgery may be required to deal with subsequent scarring of the cornea, conjunctiva, and lids.

## Referral guidelines

Irrigation should be performed immediately.

Subsequent to that, the patient should be sent urgently to the emergency eye clinic. In ophthalmology, there is nothing more urgent than a chemical ocular injury, and you should always err on the side of caution, referring everything but very mild injuries.

## 5.2 Corneal Abrasions

Corneal abrasions are common superficial corneal wounds, involving traumatic removal of the corneal epithelium.

They are usually caused by trauma from fingernails, leaves, twigs, corners of paper, etc. Trauma from anything larger or more forceful should always alert the clinician to the possibility of more serious ocular damage.

### Symptoms

- Significant pain and discomfort at the time of the injury.
- Watering.
- Photophobia.
- Visual acuity will be reduced if the abrasion is in the visual axis.

### Signs

- Examination will be significantly aided by the insertion of anaesthetic drops.
- Redness.
- Corneal epithelial defect that stains with fluorescein. There may be surrounding loose epithelium or epithelial tags.
- Visual acuity may be normal or reduced.

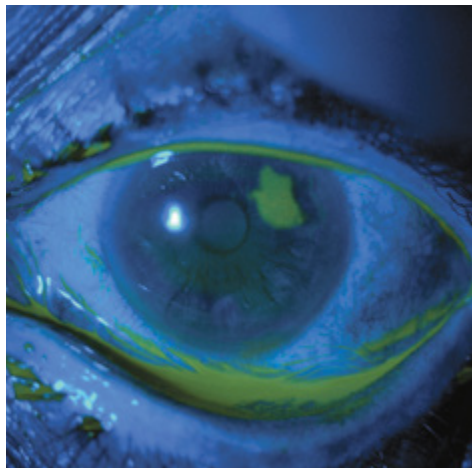
### Slit Lamp Signs

- As Above

### Immediate management

If there is any loose epithelium or epithelial tags these can be debrided with a cotton tip or a sterile needle. This aids comfort and speeds healing.

Topical antibiotics are usually prescribed as prophylaxis against infection until the epithelial defect has healed. Chloramphenicol is the most commonly used antibiotic, either in ointment or drop form. Ointment often offers more comfort, but drops are easier to instil.



Fluorescein staining green in an epithelial abrasion.

There is no clear evidence to show a beneficial effect from padding the eye in terms of speed of healing. Some patients, however, are more comfortable with a pad on and some are more comfortable without. It is therefore best to allow the patient to choose.

A dilating drop, such as cyclopentolate, instilled once at the time of consultation can improve the discomfort of photophobia.

### **Long-term management**

Corneal abrasions should heal within 12–72 hours, depending on size. If they don't then referral is indicated.

### **Referral guidelines**

- Referral is not required for most corneal abrasions.
- Abrasions not healed after 72 hours should be referred.
- If there is any suspicion that the injury is greater than a simple abrasion, the patient should be referred.

## 5.3 Corneal Foreign Bodies

Corneal foreign bodies are usually metallic, but may be plastic, glass, wood, sand, plant material, etc.

Small metallic foreign bodies from grinding are particularly common, and these usually have an associated rust ring around them.

### Symptoms

- Patients usually note a foreign body sensation immediately, but it is not unusual for symptoms to be delayed for hours.
- Watering (variable).
- Photophobia (variable).
- Reduced vision if foreign body is in the visual axis.

### Signs

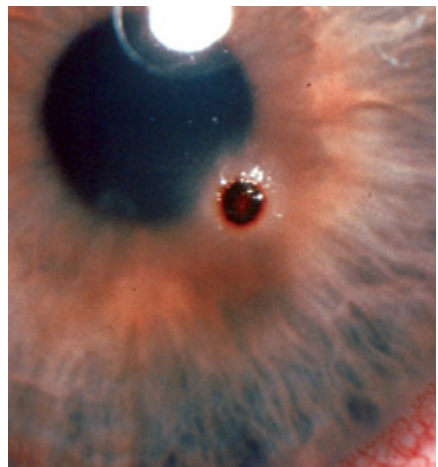- Redness.
- Foreign body usually visible on the cornea. There may be a surrounding rust ring.
- Similar symptoms are experienced by patients with sub tarsal foreign bodies so it is very important to evert the upper lid and wipe the conjunctival surface of the lid with a cotton tip to remove any possible foreign bodies.
- Sub tarsal foreign bodies often leave multiple linear fluorescein staining lines in the superior cornea.

### Slit lamp signs

- As above.

### Immediate management

- The foreign body can usually be removed with the tip of a sterile needle. Sometimes a cotton tip is used but this often only serves to further embed the foreign body in the corneal tissue and is best avoided.
- If a rust ring is present it is often difficult to remove initially, and more easily removed 2–3 days later.



Central corneal superficial foreign body.

- Topical antibiotics are usually prescribed as prophylaxis against infection until the epithelial defect has healed. Chloramphenicol is the most commonly used antibiotic, either in ointment or drop form. Ointment often offers more comfort, but drops are easier to instil.
- There is no clear evidence to show a beneficial effect from padding the eye in terms of speed of healing. Some patients, however, are more comfortable with a pad on and some are more comfortable without. It is therefore best to allow the patient to choose.
- A dilating drop such as cyclopentolate instilled once at the time of consultation can improve the discomfort of photophobia.

## Long-term management

If the eye fails to settle fully within 72 hours of foreign body removal the patient should be referred.

## Referral guidelines

Most foreign bodies do not need referral as they can usually be easily removed. There are, however, some exceptions, including:

- Foreign bodies that you are unable to remove.
- Rust rings that you are unable to remove after 3–4 days.
- “Old” foreign bodies that have been present for several days or more with surrounding corneal opacity and inflammation.
- Any foreign bodies that may have an intraocular component – these are more likely in high impact/fast impact situations, especially hammering and chiseling.

## 5.4 Blunt Trauma

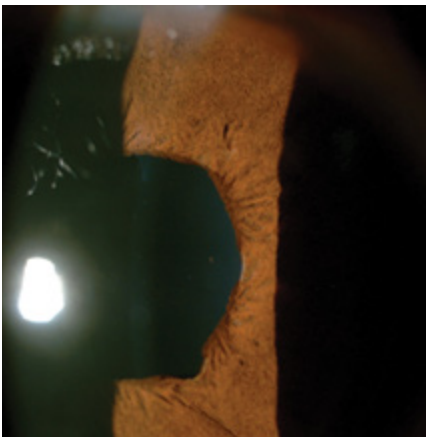
The injury caused by blunt trauma to the eye and adnexa will depend on both the extent of energy transfer and target structure.

History is useful in estimating the extent of the injury – is this the full extent of the injury or extent of energy transfer?

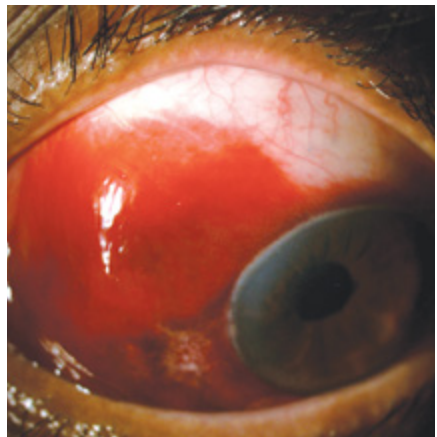### Symptoms

The signs depend on the target of the injury (orbital bones, lids, eye structures, etc.):

- The bony orbit is a relatively thin bone, except at the orbital rim, and so orbital floor or wall fractures are not uncommon. The resultant signs might include enophthalmos (eye appearing “smaller” or sunken), and restricted eye movements.
- Symptoms relate to target structure. Typically, symptoms are worse at the time of injury and then subside as inflammation lessens. Persisting symptoms such as pain and blurred vision warrant investigation to rule out foreign body and/or intraocular disruption.
- The lids may be lacerated or bruised (manifest as a black eye or lid hematoma).
- A subconjunctival hemorrhage appears bright red, obscuring part of the sclera. The association of a subconjunctival hemorrhage and low intraocular pressure may mean the globe is perforated.



Iris sphincter muscle ruptured after blunt trauma causing irregularity of the pupil margin.



Subconjunctival haemorrhage, inflammation and a distorted pupil after blunt trauma.

- Corneal trauma may be restricted to the epithelium (corneal abrasion) or affect the deeper layers, giving either a partial or full thickness laceration.
- Globe rupture may result from high-impact trauma and findings typically include markedly decreased visual acuity and low intraocular pressure.
- Intraocular trauma may result in iris injury ranging from mydriasis (large pupil) to avulsion of the iris root, as well as hemorrhage in the anterior chamber (hyphaema). Long-term implications include glaucoma.
- Kinetic energy directed to the crystalline lens may result in dislocation (subluxation) or cataract.
- Blunt trauma on the retina can produce retinal detachment and/or retinal edema. The term 'commotio retinae' is used to describe pale, thickened retinal edema caused by blunt trauma.

### Slit lamp signs

The slit lamp can be used to delineate extraocular pathology and most anterior segment signs. Red blood cells in the anterior vitreous may also be documented with the slit lamp but more posterior findings in the retina require special lenses for imaging.

### Immediate management

Initial management involves the assessment of the severity of the injury, which should include an assessment of vision. If there is a suggestion of orbital, corneal, or globe disruption, urgent referral is advised. Useful advice can usually be obtained by phoning the eye registrar or ophthalmologist on call at the local hospital.

### Referral guidelines

Referral is indicated if there is any suspicion of significant ocular, orbital, or lid injury. History and signs suggesting severe enough injury for referral include:

- Significant blunt trauma resulting in extensive periorbital hematoma.
- Blunt trauma of significant force that may have resulted in a ruptured globe.
- Diplopia (double vision).
- Reduced visual acuity.
- Hyphaema.
- Loss of red reflex.



## 5.5 Traumatic Hyphaema

The presence of blood in the anterior chamber of the eye following blunt trauma injury. The two most common causes are assault and sporting injuries, especially those involving balls and racquets.

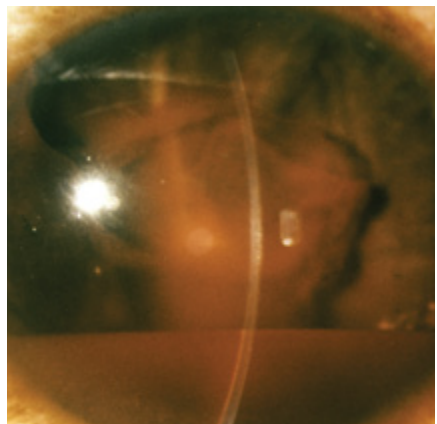
Also common are injuries from bungee cords and airbag injuries. The blood may be grossly visible (macro hyphaema) or circulating red blood cells only (micro hyphaema). Most cases of hyphaema settle without problem, although patients may be left with damage to other internal structures of the eye, especially the angle, which may suffer from what is termed angle recession, predisposing the patient to glaucoma in later life. Severe cases of hyphaema, especially those where a second spontaneous bleed occurs (rebleed), may suffer from raised intraocular pressure or corneal bloodstaining where blood is “pushed” into the cornea causing permanent opacity.

### Symptoms

- A consistent history of trauma, reduced vision, and pain. Patients may present several days after the initial injury when a rebleed occurs. A history should be taken to inquire about bleeding disorders, sickle cell, and systemic medications, especially aspirin and NSAIDs.

### Signs

- Blood may be visible in the anterior chamber as a fluid level and the level should be recorded.
- Other ocular injuries such as subconjunctival hemorrhage and globe rupture may be present.
- Orbital blow-out fracture may cause enophthalmos or restricted ocular movements.
- Head injury may also have occurred and should be excluded.



Traumatic hyphaema with disorganised iris behind it.

### Slit lamp signs

- Anterior chamber blood.
- Corneal abrasions or lacerations, and other evidence of blunt injury, including iris sphincter tears, iridodialysis (iris tearing at the root creating holes in the periphery of the iris), and lens damage (cataract or dislocation).
- Elevated intraocular pressure.

### Immediate management

- Protective shield over the eye.
- Restrict activity to essential ambulation only.
- Analgesia.
- Anti-nausea treatment, e.g. prochlorperazine.
- Urgent referral to ophthalmologist.

### Long-term management

Many patients can be managed as outpatients. Inpatient care may be considered for patients with poor social support, large hyphaema, or other ocular injuries, for treatment of elevated intraocular pressure, and for children (especially those at risk of amblyopia or where child abuse is suspected).

Further ophthalmic care will include topical mydriatic (usually atropine) and corticosteroid (usually Pred Forte), and treatment of elevated pressure with beta-blocker, alpha agonist, or carbonic anhydrase inhibitor drops, plus oral acetazolamide.

Surgical evacuation of the clot may be necessary for total hyphaema, elevated pressure despite maximal medical therapy, or for corneal blood staining.

### Referral guidelines

Refer all traumatic hyphaemas for urgent ophthalmic assessment.

## 5.6 Penetrating Eye Injury

Penetrating eye injury is the leading cause of monocular vision loss.

It primarily affects young men – most series show approximately 80% of PEIs are in males and the peak incidence is at 27 years. Injuries can occur at work, home, or recreationally and there is commonly an association with alcohol or drug consumption.

### Symptoms

There is usually a history of sudden visual loss in association with an activity involving a potential penetrating object. Common examples include car crashes, hammering metal, machinery, nail guns, falls with sharp objects (scissors, knives), and airguns or firearms.

Metal penetrating foreign body. Rarely, a penetrating object may be small and fast moving (classically hammering metal) and symptoms may be minimal, with little pain or vision loss; a high degree of suspicion must be maintained with the history of hammering metal on metal.

### Signs

Suspicious signs include poor vision, lid lacerations, or a peaked or irregular pupil.

### Slit lamp signs

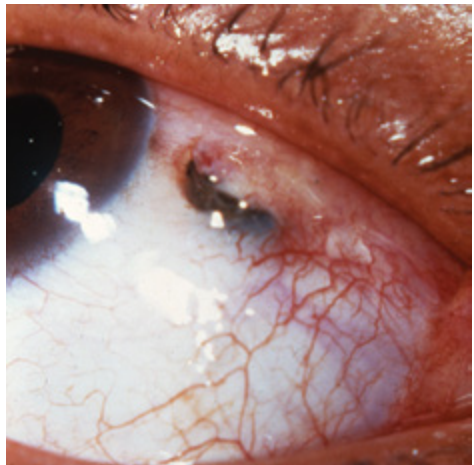
It is very important not to place pressure on the lids or eye. If there is clinical suspicion and the eye cannot be readily visualized, the eye should be protected and the patient referred.

If slit lamp examination is possible, signs may include:

- Uveal prolapse at the cornea or sclera.
- Hyphaema.
- Peaked or irregular pupil.
- Deep or shallow anterior chamber.
- Subconjunctival hemorrhage.

### Immediate management

If a penetrating injury is suspected the eye should be shielded (not padded) with rigid protection (a disposable cup taped in place will do) and the patient referred acutely to the eye department for further management.



Penetrating injury with metallic foreign body in situ.

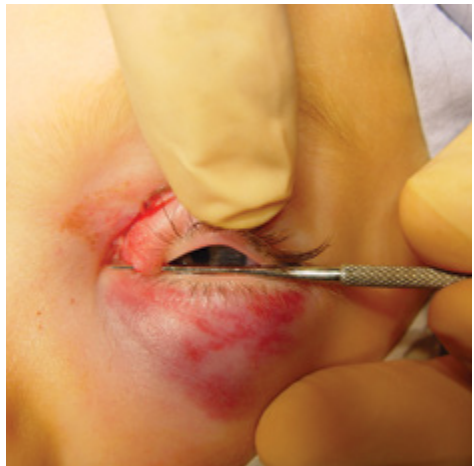## Long-term management

Long-term management involves initial repair of the ocular laceration and protection with antibiotics.

Further management depends on the site and extent of the injury and may include cataract extraction, retinal detachment repair, intraocular foreign body removal, or anterior segment reconstruction. If the eye is very severely damaged and the prospect for return of vision is poor, the eye may be removed to decrease the risk of sympathetic ophthalmia to the other eye.

## Referral guidelines

Always refer acutely to the nearest eye department if penetrating injury is suspected.



Probe entering upper punctum and exiting through torn canaliculus.

## 5.7 Canalicular Trauma

This occurs from direct trauma to the medial canthal structures, such as from a dog bite or windscreen injury, or from blunt trauma causing tearing of the medial eyelid.

### Symptoms

- Pain.
- Watering (this may be absent if only one canaliculus is affected).

### Signs

- Laceration through the medial eyelid tissue, medial to the punctum.
- Displacement of the eyelid.

### Slit lamp signs

- The cut ends of the canaliculus may be visualized.
- Ensure no injury to the eye has occurred – look for corneal abrasion, hyphaema, or other injury.

### Immediate management

- Ensure there are no other significant injuries that need treatment.
- Consider pain relief and antibiotic prophylaxis +/- tetanus prophylaxis.
- Urgent referral.

### Long-term management

- Surgical repair with stenting and meticulous approximation of the cut ends of the canaliculus within 48 hours of the injury.
- Repair of associated medial canthal and eyelid injuries.
- Surgical correction of secondary eyelid problems.
- Management of persistent watering if present.

### Referral guidelines

Urgent referral to the acute ophthalmology service (within 24 hours of injury).

## 5.8 Orbital Fractures

There are various fractures that occur around the orbit. If extensive, or involving adjacent structures such as the sinuses, these are best managed by maxillofacial, ORL, plastic, or neurosurgeons – depending on the site.

Orbital blow-out fractures of the floor or medial wall are best managed by oculoplastic surgeons.

### Symptoms

Most patients will have diplopia, which is usually mild if associated with bruising of an extraocular muscle or more severe when related to muscle entrapment. With the latter, diplopia is worst in the direction away from the fracture site, i.e., with a blow-out fracture of the orbital floor there can be markedly reduced upgaze with associated diplopia when looking up.

### Signs

- Restriction of eye movements.
- Bruising or laceration around the affected eye.
- Numbness in infra-orbital nerve distribution – over the cheek of the affected side.
- Enophthalmos (sunken eye).
- Crepitation associated with subcutaneous air – may occur if the medial orbital wall is fractured.
- Lids may swell on nose blowing.
- In 30% of cases, there are significant associated eye injuries (see below – slit lamp signs).

### Slit lamp signs

As for all orbital trauma, the affected eye should be examined, as there may be raised intraocular pressure, hyphaema, angle recession, and retinal damage, including commotio retinae and retinal detachment.

### Immediate management

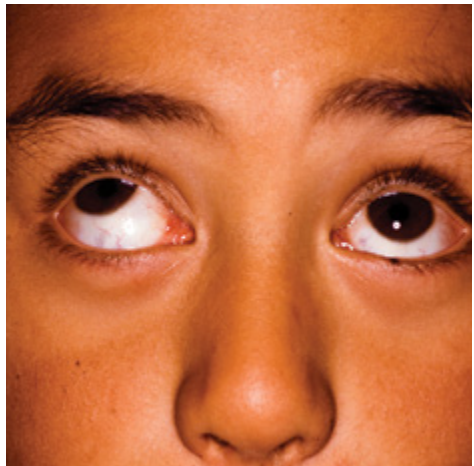While most patients don't need urgent treatment, those with "white eye" blow-out fractures should be operated on as soon as possible. This group is usually aged under 15 years with minimal signs of trauma around the orbit but inferior rectus muscle entrapment with significantly reduced elevation of the eye. The fracture is analogous to a greenstick fracture of long bones and can cause muscle ischemia if left untreated.

### Long-term management

Adults with typical blow-out floor or medial wall fractures will be reviewed within 1–2 weeks and generally surgery is performed within 1–4 weeks, if required. As the fracture enters a sinus, the patient should have systemic antibiotics and be advised against nose blowing. The two main indications for surgery are extraocular muscle entrapment and enophthalmos (greater than 2 mm) from intraorbital contents prolapsing into the sinus and being caught in the fracture site. Continued alteration of infraorbital nerve sensation is another reason for fracture reduction.

### Referral guidelines

Any patient with a suspected orbital blow-out fracture should be referred for an oculoplastic opinion within 1–2 weeks but children with reduced eye movements following trauma should be seen the same day. In most cases, CT scanning will be useful in the diagnosis and management of patients with orbital trauma.



Left blow-out fracture with muscle entrapment causing loss of upgaze.



## 6 *Lids*



## 6.1 Lid Lumps – Benign

There are many benign lesions that occur on the eyelids but the more common of these tend to be either papillomatous (squamous papilloma, verruca, seborrheic keratosis) or cystic (meibomian, sebaceous or sweat gland cysts).

### Symptoms

Generally present as painless, slow growing lumps but not uncommonly the patient will experience some irritation especially if the lashes are involved.

### Signs

Cystic lesions may trans-illuminate. The sebaceous cysts are creamy white and the sweat gland cysts contain clear fluid. Naevi can look like basal cell carcinomas but there is generally no loss of eyelashes with benign lesions and this can help to differentiate them.

### Slit lamp signs

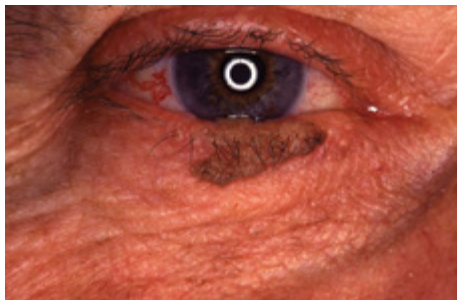
Cyst content may be more apparent and the typical variegated surface of papilloma is often seen in slit-lamp investigation. These lesions do not normally destroy the eyelid architecture but appear to extend from it.

### Immediate management

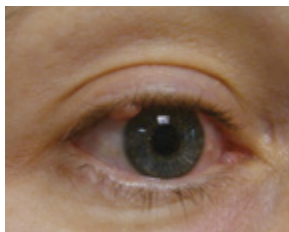Once the diagnosis of a benign lesion is made, there is no urgency for treatment unless the eye is irritated by the lesion or from misdirected lashes.

### Long-term management

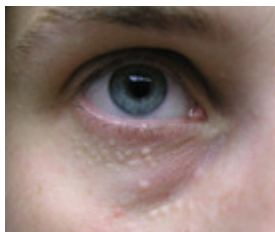
Most benign lesions do not have malignant potential and therefore do not require regular review. While a naevus can transform into a



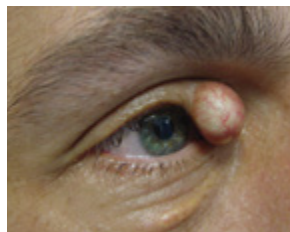
Lower lid seborrhaeic keratosis.



Upper lid naevus.



Numerous syringoma of the right lower lid.



Upper lid sebaceous cyst and lower lid xanthelasma.

malignant melanoma, this is very rare and the patient would notice the change in nature or rapid growth of the lesion.

### **Referral guidelines**

It is acceptable to refer any patient with an eyelid lesion for diagnostic reasons. Some patients will purely want reassurance whereas others may opt for removal of a lesion for comfort or cosmetic concerns.

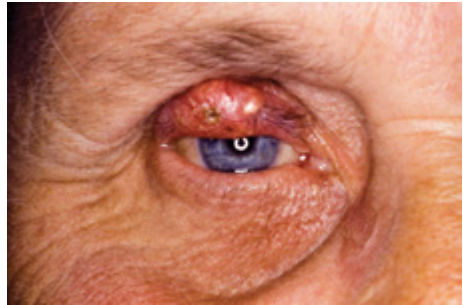## 6.2 Lid Lumps – Malignant

Malignant eyelid lesions are not uncommon and are occurring with increasing incidence. Over 90% are basal cell carcinomas (BCCs).

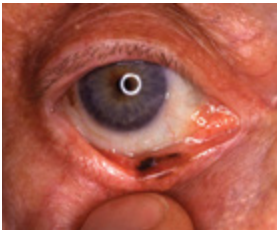Squamous cell carcinomas (SCCs) account for 2–4% and both malignant melanoma (MMs) and sebaceous gland carcinomas are very rare. Around 90% of malignant eyelid lesions occur on the lower lid.

### Symptoms

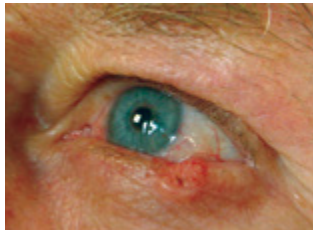
Often asymptomatic, a patient may complain of eye irritation from lid margin irregularity or eyelash misdirection (trichiasis). Generally the lesions are painless and slow growing, though the more malignant tumours, such as MMs or sebaceous carcinomas, can have rapid and destructive growth.



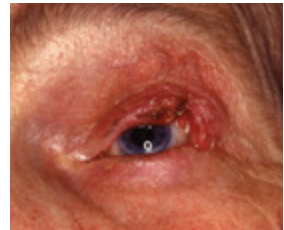
Right upper lid sebaceous gland carcinoma.



Right lower lid melanoma.



Lower lid basal cell carcinoma.



Left upper lid squamous cell carcinoma.

### Signs

Malignant eyelid lesions tend to cause alteration/destruction of the lid margin and there may be ulceration and bleeding, particularly with SCCs or morphoeic BCCs. A cardinal sign is madarosis (loss of eyelashes) and this can be a very useful feature in differentiating malignant lesions from benign ones, such as lid margin naevi.

### Slit lamp signs

Madarosis will be obvious on slit-lamp examination. Trans-illuminating the lesion by shining a small beam directly onto it can help differentiate a solid tumour (which tends to glow pink/white) from a cyst (which is fluid-filled) and glows like a lantern.

### Immediate management

Atypical lesions may require biopsy but in many cases it is reasonable to proceed with definitive treatment based on the clinical findings. Nodular BCCs can be removed with 2–3 mm gross margins but recurrent lesions, morphoeic BCCs and SCCs should have some form of margin control, such as frozen section or Mohs surgery. For MMs a ‘slow Mohs’ technique (also known as rapid paraffin sections) is used to ensure clear margins prior to reconstruction.

### Long-term management

Any incomplete or narrowly excised lesions require long-term follow-up, as do all highly malignant lesions, such as MMs and sebaceous carcinomas.

### Referral guidelines

Any suspicious lesion affecting the eyelid or orbital region should be referred for oculoplastic opinion. Suspected MMs or sebaceous carcinomas should be seen relatively urgently, i.e. within 1–2 weeks, while it is reasonable to see slow-growing nodular BCCs within 3–6 weeks.

## 6.3 Lower Lid Ectropion

An ectropion is a positional problem of the eyelid in which the margin is rotated away from the globe.

It is generally an involutional change related to laxity of the canthal tendons and lower lid retractor disinsertion. An ectropion can also be cicatricial related to skin shortage, mechanical from lid lumps, or paralytic from seventh nerve palsy.

### Symptoms

Commonly, patients have irritation from conjunctival thickening and drying. Watering relates to lid margin and punctal displacement along with secondary punctal stenosis.

### Signs

There may be an elevated tear film (increased height of tear meniscus along the lower lid margin) and conjunctival inflammation in the region of the ectropion. Laxity of the medial or lateral canthal tendons is commonly seen. In cicatricial ectropion the skin can be generally shortened from sun damage or related to a scar. A paralytic ectropion will have the associated features of a facial palsy.

### Slit lamp signs

Punctal stenosis is best seen on the slit lamp and this may also show maceration of the conjunctiva from prolonged exposure. In paralytic ectropion corneal drying, erosions and ulceration can occur from incomplete eyelid closure.

### Immediate management

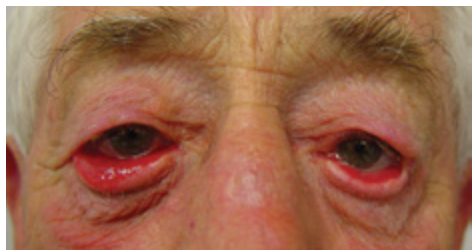For corneal drying, regular lubricants are used (Lacrilube or Polyvisc ointment at night and artificial tear drops during the day). If there is any corneal ulceration, this must be managed with appropriate topical antibiotics ([See 8.1 Bacterial Keratitis on page 65](#)). In cases of acute paralytic ectropion, the lower lid can be taped for support and Botox injected into the levator muscle to produce a temporary tarsorrhaphy.

### Long-term management

In general, ectropion is well treated with surgery aimed at rectifying the underlying causes. This may include lid-tightening procedures, punctal opening and the addition of skin.

### Referral guidelines

Most ectropions can be referred on a non-urgent basis unless there is concern regarding the health of the cornea.



Bilateral lower lid ectropion.

## 6.4 Lid Entropion

Inward rotation of the lower eyelid causing eyelashes and skin to irritate and abrade the eye.

Usually age-related changes result in orbicularis muscle overriding the tarsal plate and loss of eyelid support from the canthal ligaments.

### Symptoms

- Discomfort on blinking, pain and watering.

### Signs

- In-turned eyelid, lashes sweeping the globe, watering +/- discharge, conjunctival injection.

### Slit lamp signs

- Potential corneal abrasion or ulceration.
- Fluorescein staining of the cornea.

### Immediate management

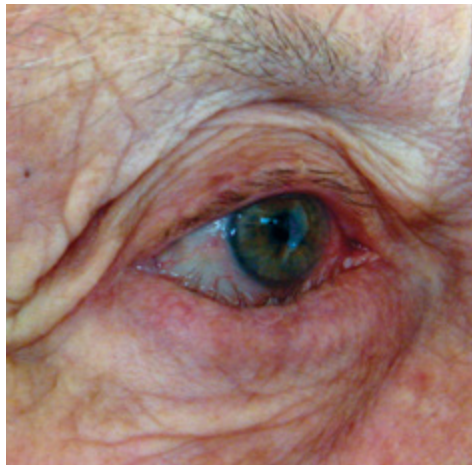
- Taping of eyelid skin.
- Topical antibiotic ointment, i.e. Oc Chloramphenicol.
- NB. epilation is not helpful.

### Long-term management

- Surgical correction of entropion to address lid laxity, stabilisation of the tarsus, and orbicularis overriding.

### Referral guidelines

- Urgent referral if corneal ulcer.
- Semi-urgent review if patient has significant discomfort.



Lower lid entropion.

## 6.5 Ptosis – Acquired

The upper lid should sit 1–2 mm below the superior limbus (upper border of the cornea). Ptosis occurs when the eyelid is lower than this, and, although there is some natural variation in position, it is commonly diagnosed when 2 mm or greater below the normal height.

Involitional ptosis is by far the most common form of acquired ptosis but other forms, such as neurogenic (third nerve palsy or Horner's syndrome), myogenic, mechanical, traumatic and myasthenic ptoses, are seen.

### Symptoms

In involitional ptosis the patient is aware of a gradual droop in the upper eyelid and this is often more noticeable in downgaze, affecting the ease of reading. Mostly this is a bilateral condition and can be associated with long-term rigid contact lens wear. Patients with neurogenic, myogenic or myasthenic ptosis may all be aware of diplopia.

### Signs

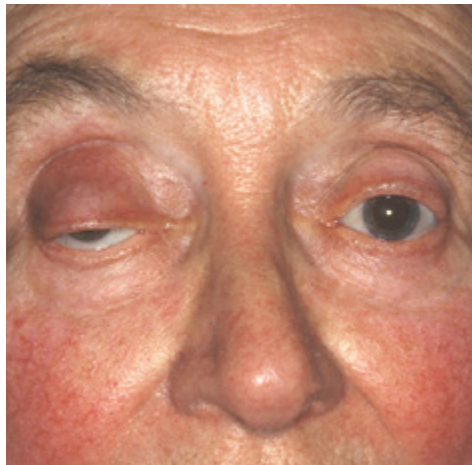- Ptosis of one or both lids
- Eyebrows may be raised in an effort to hold lids up
- Upper lid skin crease may be high or absent
- Abnormal or reduced eye movements
- If patient has abnormal lid closure as well as ptosis then the cornea may have signs of exposure – fluorescein staining over the lower third of the cornea

### Slit lamp signs

In patients with ptosis and decreased lid closure or reduced Bell's phenomenon, such as with myogenic ptosis or third nerve palsies, the cornea needs to be examined for exposure changes.

### Immediate management

It is important to secure a diagnosis in acquired ptosis. If there is no corneal concern or underlying medical condition needing to be addressed, there is generally no rush for treatment. Sudden onset of



Right involitional ptosis.

ptosis with associated eye movement abnormalities needs urgent referral. Slow onset of bilateral ptosis with other abnormalities is more likely to be involutional ptosis that can be referred routinely.

### **Long-term management**

Should the patient opt for surgery, a ptotic lid can be lifted, usually under local anaesthetic as an outpatient. The procedure is tailored to the degree of function in the levator muscle and underlying cause of the acquired ptosis.

### **Referral guidelines**

Patients presenting with neurogenic ptosis, particularly a painful third nerve palsy, need immediate urgent assessment. Most other acquired ptoses can be reviewed with less priority.



## 6.6 Trichiasis

Trichiasis is a condition in which misdirected eyelashes impinge on the eye. It is often the result of chronic blepharitis but also occurs following trauma or eyelid surgery.

### Symptoms

- Most patients will experience watering from irritation and if the lashes are directly abrading the cornea there is likely to be pain, which can be significant.
- Discomfort is worse on blinking and many patients will be regularly removing lashes.

### Signs

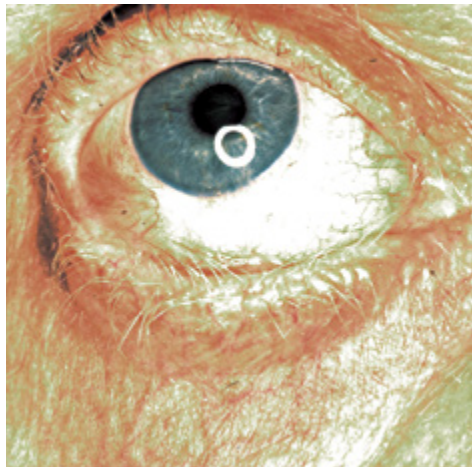
- The affected eye is likely to be red and have lashes directed towards the cornea or conjunctiva.
- Corneal abrasions or ulceration may be visible with fluorescein dye.
- If corneal infection occurs, there will be a corneal opacity, which should be visible without magnification.

### Slit lamp signs

- Misdirected eyelashes.
- Corneal staining with fluorescein.
- Corneal opacification from infection.

### Immediate management

- Epilation (removal) of offending eyelashes.
- Corneal treatment if required – Chloramphenicol ointment four times a day for abrasions.
- Urgent referral if infected ulcer – fluorescein staining of cornea, together with infiltrate or opacity in the same area of the cornea.



Misdirected lashes abrading the cornea in trichiasis.

### Long-term management

- Permanent treatment of trichiasis is performed by radiowave ablation for individual lashes or cryotherapy if they are in a clump.
- Both treatments have approx 70% success, and so often need repeating.
- In some cases it may be preferable to surgically remove an abnormal area of eyelid.

### Referral guidelines

- Some patients are happy to purely epilate the lashes every few months.
- Refer those wanting permanent eyelash removal.
- Refer urgently if corneal ulcer (within 24 hours).

## 6.7 Watery Eye in the Adult

Tear overflow (epiphora) may be related to either lacrimal or eyelid disorders. The eyelid abnormalities, such as ectropion, which produce watering, are discussed elsewhere. The lacrimal drainage issues causing epiphora are numerous but are most commonly related to either partial or total obstruction of the nasolacrimal duct.

### Symptoms

Epiphora is usually constant and persistent in total obstruction, but intermittent and often related to cold or windy conditions with partial obstructions. If a mucocoele is present there will be an accompanying muco-purulent discharge, and dacryocystitis from bacterial infection will often cause significant pain.

### Signs

The affected tear film will be elevated (raised tear meniscus along lower lid margin) and there may be a partially compressible swelling of the lacrimal sac in the medial canthus. If present, signs of dacryocystitis will include abscess with swelling and redness over the medial canthus and there may be a draining fistula.

### Slit lamp signs

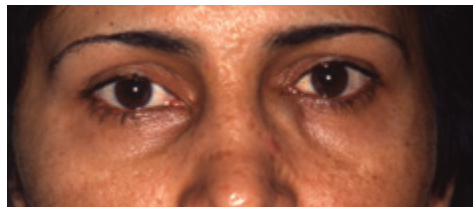
- Mucus can be seen in the tear film in patients with mucocoeles.
- There may be punctal abnormalities or eyelid malposition, both of which can contribute to watering.

### Immediate management

Dacryocystitis should be addressed promptly with systemic antibiotics often given orally but in severe infections or those progressing despite oral treatment; the patient is better treated in hospital with IV antibiotics. In some cases the infection won't adequately settle without incision and drainage of a lacrimal sac abscess.

### Long-term management

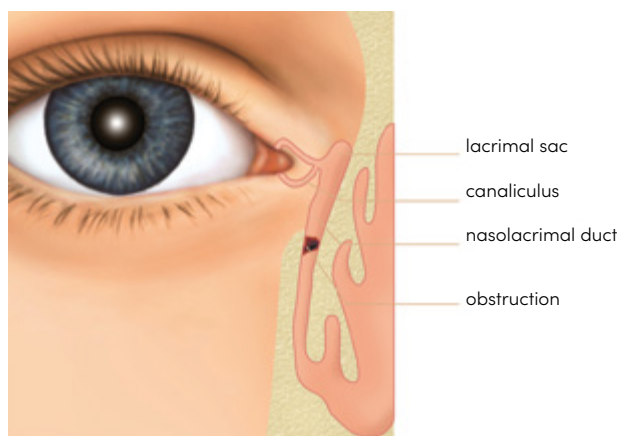
Ultimately the condition is best treated with a dacryocystorhinostomy (DCR), which is an operation to bypass the lacrimal drainage system. This is performed under local anaesthetic with sedation and has a high success rate of around 95%. The surgery will treat both the watering and infection if present.



Left lacrimal sac mucocoele.

## Referral guidelines

Any patient troubled with watering or a history of lacrimal sac infection should be referred for assessment on a non-urgent basis. Significant sac infection requires urgent referral.



## 6.8 Chalazion

A chalazion or meibomian cyst is a common problem occurring in all ages. It is due to a blockage of the meibomian oil glands, which discharge via apertures behind the lash line. These openings can become blocked and secretions of the gland build up and cause an inflammatory reaction in the lid. Secondary infection can sometimes occur.

### Symptoms

Swelling or discomfort in the upper or lower lid. Vision can occasionally be affected if there is a large cyst (particularly in the upper lid) as this can press on the eye and induce a change in focus. More than one chalazion can occur simultaneously. Develops over a week or so and may resolve or persist for some months. Most eventually resolve with conservative management.

### Signs

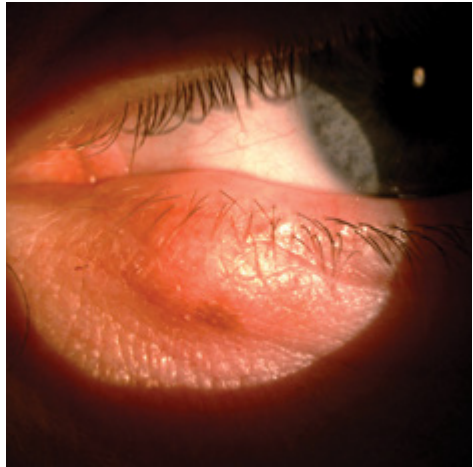
- Lid lump.
- May be associated with redness and oedema.
- Blepharitis may be present.
- Evidence of previous chalazia.

### Immediate Management

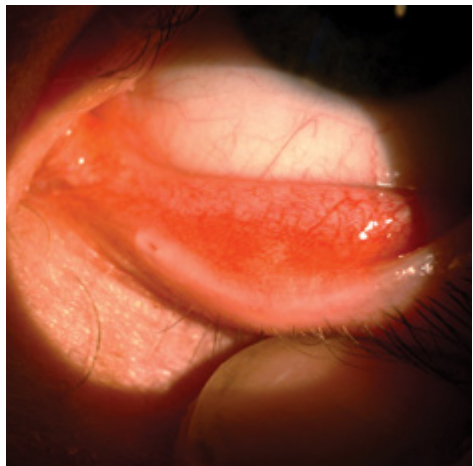
Hot compresses to unblock the gland apertures are the mainstay of treatment. If there is evidence of secondary infection consider oral antibiotics. Most will resolve but if a chalazion persists or is causing distress then it can be treated with incision and curettage.

### Long-term Management

Advise patients to treat chalazia with hot compresses followed by massage directly over the swelling, several times a day until



Lower lid chalazion.



Yellow spot on inner lower lid, demonstrating site of a chalazion.

the swelling has resolved. Long-term blepharitis care ([See 7.1 Blepharitis on page 41](#)) may reduce recurrence.

## Referral

Refer any patient who has a chalazion that needs incision and curettage or that has not responded to treatment as expected.

## 6.9 Upper Blepharoplasty

### General Description

Blepharoplasty surgery involves the removal or redistribution of eyelid tissue. These tissues include skin, muscle and fat, all of which undergo changes with ageing and in some disease processes. With ageing, the skin loses its natural elasticity. This, combined with the effects of gravity, tends to cause 'drooping' of the eyebrows and the appearance of redundant skin in the upper eyelids. Muscles around the eye may also become thickened (hypertrophic), particularly in smokers.

### Symptoms

Most patients are troubled with a feeling of heaviness in the upper lids and when there is significant overhang of skin, reduction in the superior field of vision. Women often have difficulty in applying make-up to the lashes as this may be transferred directly to the upper lid skin. Occasionally irritation occurs from resultant misdirection of the upper lid lashes.

### Signs

Skin overhang may be apparent on gross examination and formal visual field testing can show a visual field defect.

### Slit-lamp Signs

There are no specific slit-lamp signs except in the case of the skin fold impacting on the superior lashes and pushing them against the cornea. This is more common in Asian races and is similar to 'epiblepharon' seen in the lower eyelids.

### Immediate Management

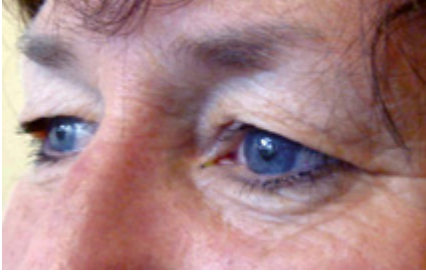Unless there is corneal irritation present the treatment is non-urgent.

### Long-term Management

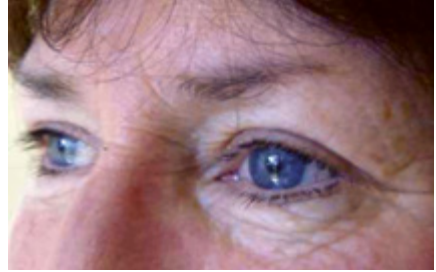The condition is treated by blepharoplasty surgery and this may include placement of a more defined skin crease. The latter is the case with 'Asian Blepharoplasty' in which the mainstay of treatment is skin crease formation (or creation of a "double eyelid").

## Referral Guidelines

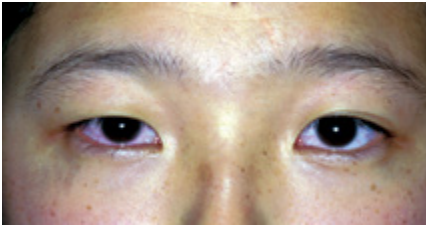
Patients troubled with excess upper eyelid skin should be referred for discussion of surgical treatment of the condition. The eyelids are an important protector of the eyes and surgery must not impact on this function. It is also important to rule out ocular conditions which could be impacted on by surgery such as dry eye and corneal abnormalities.



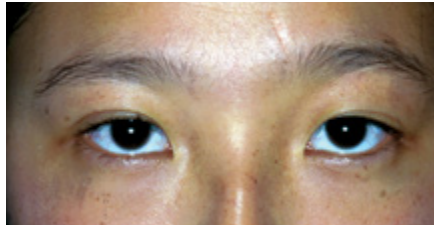
Pre-op upper blepharoplasty.



Post-op upper blepharoplasty.



Patient born with left skin crease but absent right crease.



Following right upper lid skin crease reformation



## 6.10 Lower Eyelid Rejuvenation

### General Description

The lower eyelid undergoes a number of changes with ageing. Loss of elasticity in the skin may cause some redundancy of tissue and stretching of connective tissue within the lid commonly results in fat prolapse which gives an appearance of 'bags'. Cheek descent from gravity is demarcated superiorly by the 'tear trough' and the trough is made more obvious if there is significant fat prolapse above it.

### Symptoms

Most complaints center around the tired look and 'baggy' appearance caused by ageing changes. Symptoms are more likely if there are co-existent problems with lid malposition.

### Signs

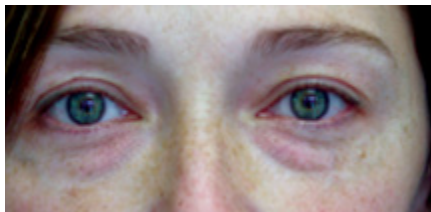
These include tissue redundancy, fat prolapse, tear trough deformity and cheek descent.

### Immediate Management

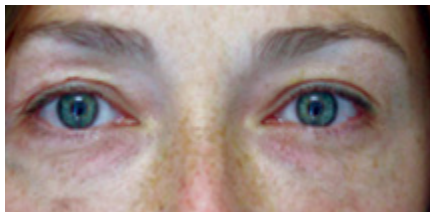
There is no urgent treatment required for lower lid changes unless there are lid positional abnormalities causing corneal trauma.

### Long-term Management

Treatment options for lower eyelid rejuvenation include both surgical and non-surgical procedures. If eyelid skin is removed it must be done conservatively to prevent dry eye complications from an immobile eyelid. Fat prolapse is generally addressed via a conjunctival approach and in some cases can be redistributed to improve the appearance of the tear trough.

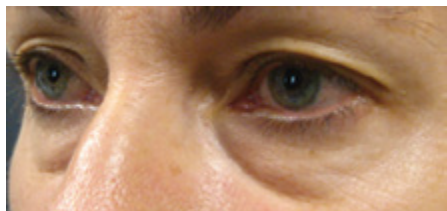

Fat prolapse in lower eyelids.

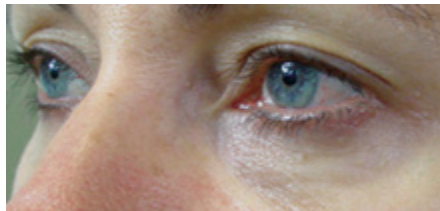


Following Restylane injections (volume replacement) above and below fat pads.

Patients may benefit purely from reduction of the tear trough without surgery and this can be achieved with the injection of soft tissue fillers. These are injected through a cannula under topical anaesthesia and in the periorbital region often last a number of years.



Lower lid fat prolapse and tear trough formation.



Lower lid appearance after debulking of fat pad.

## Referral Guidelines

Any patient concerned about the appearance of their lower eyelid region should be referred for discussion of surgical and non-surgical options of treatment. It is particularly important with lower lid surgery to avoid complications related to reduced eyelid movement as these patients can be the most unhappy with inappropriate management of their concerns.



## 7 *Conjunctivita*

## 7.1 Blepharitis

Blepharitis is a general term for inflammation of the lid, but most commonly used in relation to chronic lid margin disease. The terms anterior blepharitis and posterior blepharitis are used to differentiate the two main types seen.

- Posterior blepharitis is also referred to as meibomian gland dysfunction and is extremely common, affecting as much as 50% of the population to some degree. There is inflammation of the meibomian glands resulting in a lack of healthy meibomian secretions, which causes dry eye. It is often associated with rosacea.
- Anterior blepharitis is due to a build-up of lid commensals (mainly staphylococcus) and results in reddened inflamed lid margins.

### Symptoms

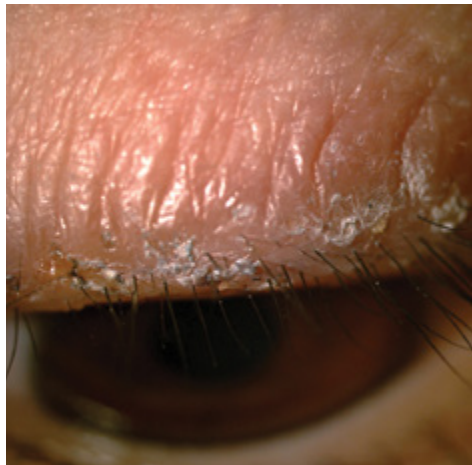- Burning, especially in the morning.
- Dryness and irritation.
- Red lids with crusting and scaling.

### Signs

- Red lid margins (anterior blepharitis).
- Scales in the lashes, loss of lashes (anterior blepharitis).
- Chalazia (anterior and posterior blepharitis).
- Notching of the lid margin (anterior and posterior blepharitis).
- Inflamed meibomian gland openings, often with thickened secretions in the gland orifice (posterior blepharitis).

### Slit lamp signs

- As above.



Debris in the base of the lashes in anterior blepharitis.

## Immediate management

**The most important treatment is correctly performed lid hygiene. This comprises three steps:**

1. Heat the lids up for at least 2 minutes (e.g. with a hot flannel, or under a hot shower).
  2. Firm pressure directly onto the lids just below the lower lashes and just above the upper lashes. This is to express the contents of the meibomian glands. The patient should not “massage” the lid skin as this merely stretches the lid skin and does not express the glands.
  3. The lid margins/lashes are then cleaned either with a commercial product, such as Sterilid or Lidcare, or with a solution of baby shampoo on a flannel.
- A course of topical antibiotic ointment may help (chloramphenicol qds or fucithalamic bd).
  - Oral doxycycline can significantly help with meibomian gland dysfunction (50mg a day for 3 months).
  - Ocular lubricants can help symptomatically. It is best to avoid drops containing the preservative benzalkonium chloride, “Gel” type lubricants give the best comfort, although they may blur the vision. Often it is helpful to get the patient to try various different types of drop to see which gives them the greatest relief.
  - In severe cases topical steroids may be used, but only when other treatments have either failed or are not possible (older patients often find lid hygiene impossible).

## Long-term management

Blepharitis is a chronic condition that is likely to recurrently plague the patient for life. Symptoms, however, can usually be controlled by continuing treatment as above.

## Referral guidelines

Refer patients to an ophthalmologist if standard treatments are insufficient and if topical steroids are being considered.

## 7.2 Dry Eye

Dry eye symptoms are usually a result of tear film instability due to blepharitis. True lack of tears creates the more severe and vision-threatening condition of keratoconjunctivitis sicca. It may be an isolated condition or part of Sjogren's syndrome.

### Symptoms

- Pain and irritation, may be severe.
- Blurring of vision.

### Signs

- There may be widespread mild fluorescein staining of the corneas.
- The tear meniscus may be visibly low.

### Slit lamp signs

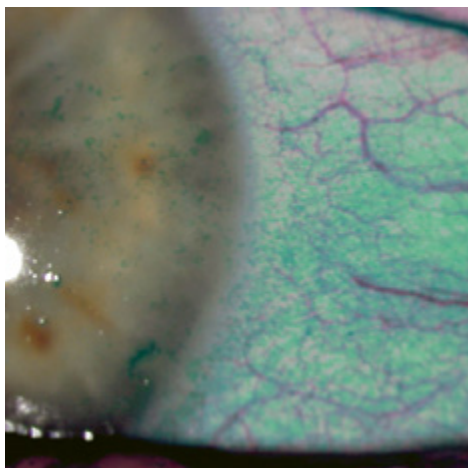
- Reduced tear meniscus.
- Punctate epithelial erosions of the corneal epithelium (dullness or roughness of the epithelium) that usually stains with fluorescein showing multiple tiny staining dots.
- Mucus strands attached to the cornea.
- In severe cases frank epithelial defects.
- In chronic and/or very severe cases corneal scarring.

**NOTE:** Auckland Eye offers Dry Eye therapy at Oasis Spa. (See [Oasis Surgical Remuera on page 381](#))

### Management

#### Tear supplementation

- The main treatment is tear supplementation with artificial tears. Low viscosity drops require very frequent application but tend not to cause blurring of the vision. More viscous drops give longer lasting relief but can blur the vision. Ointments are often too thick and can actually aggravate the symptoms. It is best to avoid artificial tears with the preservative benzalkonium chloride, and if drops are being used very frequently it is best to



Dry eye staining with Lissamine green.

use drops with no preservative at all, although these are more expensive. Often it is helpful to get the patient to try various different types of drop to see which gives them the greatest relief. Autologous serum drops can be used in patients who require very frequent drops. these are made from the patient's blood and hence have no toxic effect.

- Any concurrent blepharitis should be treated (*See 7.1 Blepharitis on page 41*).
- Cyclosporine drops (Restasis 0.05%) are beneficial in many cases but are not available commercially in New Zealand. A 0.2% ointment form of cyclosporine is available, although this is often too thick for people with significant dry eye.
- Mucolytic topical agents (acetylcysteine 5%) can help if there are significant mucus strands.

### **Tear preservation**

- Patients should avoid air-conditioned atmospheres and dehumidifiers. It can help to use a room humidifier.
- Punctal plugs can be placed in the drainage puncta to reduce tear drainage. These plugs may be temporary, or long term, and usually are placed in the lower lid puncta first, and then the upper lid puncta if insufficient effect is achieved. If too much effect is achieved and the patient suffers watering then the plugs can be removed.
- Punctal cautery is a permanent way to occlude the puncta, and is usually only done when punctal plugs have proven useful, and when the patient's condition is likely to be permanent.

### **Referral guidelines**

Refer any patients non-urgently to the ophthalmologist if lubricants and treatment of blepharitis fails to resolve the patient's symptoms.

## 7.3 Allergic Conjunctivitis

Allergic conjunctivitis is a spectrum of disease from minor and self-limited hayfever conjunctivitis through to seasonal or perennial allergic conjunctivitis.

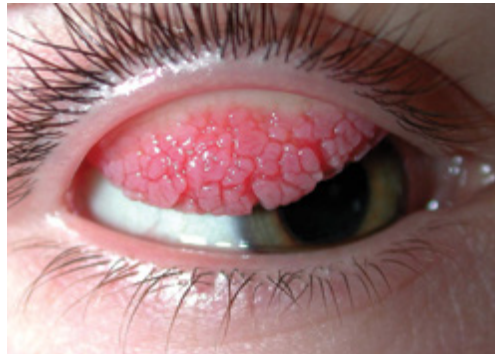Allergens include pollens and fungal spores, animal dander and, especially with perennial symptoms, the house dust mite.

Two more severe vision threatening forms also exist:

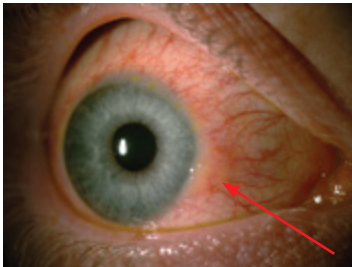
1. Vernal keratoconjunctivitis is usually seen in children and teenagers, especially boys
2. Atopic keratoconjunctivitis is seen in adults and strongly associated with other atopy, especially allergic eczema of the face

### Symptoms

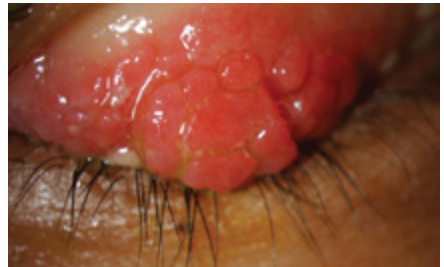- Itching is a very important symptom.
- Lids may be swollen.
- Watery discharge (hayfever conjunctivitis) or thick ropy mucoid discharge (vernal keratoconjunctivitis).
- Bilateral symptoms but may be asymmetrical.
- Photophobia especially if there is any corneal involvement.
- History of atopy often present.
- May be seasonal – worse in spring and summer.



Giant 'cobblestone' papillae in vernal conjunctivitis.



Swelling of the limbus in vernal allergic conjunctivitis.



Giant papillae.



## Signs

- Diffuse conjunctival injection, chemosis (conjunctival oedema) and red swollen lids.
- Corneal ulceration may complicate severe disease.
- Absence of pre-auricular adenopathy (which would normally suggest viral infection).
- Visual acuity may be reduced from corneal epithelial irregularity or ulceration.
- Keratoconus is associated with atopy and eye rubbing and may also reduce the vision.

## Slit lamp signs

- Papillae on inside of lids: multiple fine red lumps (velvet appearance) or larger “cobblestone” lumps.
- Limbal papillae (at margin of cornea and sclera) also occur, especially in pigmented races and may mimic other limbal pathology such as pterygium.
- Raised white dots at the limbus (Horner-Trantas dots), which consist of degenerate eosinophils.
- Corneal epithelial micro-erosions stain in a punctate pattern with fluorescein.
- Corneal shield ulcers are a larger area of epithelial breakdown with a mucous plaque preventing epithelial repair.

## Immediate management

- Rule out corneal involvement and refer if present.
- Avoid allergen if known.
- Avoid rubbing the eyes as this releases more histamine.
- Artificial tears and cold compresses for comfort.
- Topical antihistamine drops (as below).
- Oral antihistamines may relieve itch and swelling.

## Long-term management

- Avoid using drops with vasoconstrictor action (Albalon, Naphcon) as these create rebound problems with redness on cessation.
- Most patients with chronic symptoms are best maintained on mast cell stabilisers or on dual action agents, which have antihistamine plus mast cell stabilising activity.
- Mast cell stabilisers are used for prevention and need to be taken regularly to work. They include sodium cromoglycate qds, or Lodoxamide tds. It takes 2

weeks to get full effect, and ideally they should be started 2 or 3 weeks before the expected season of symptoms starts.

- Ideally dual action agents should also be used regularly but can have more immediate symptomatic relief than mast cell stabilisers and can therefore be used as needed if preferred. They include Olopatadine 0.1% (Patanol) and Ketotifen, and are routinely used twice a day.
- Topical corticosteroids may be used under specialist supervision (to monitor for side effects such as raised intraocular pressure which occurs in 10% of patients).
- Topical Cyclosporine ointment may be used (but is not commercially available so needs to be organised either through the hospital or private ophthalmology clinic).
- Systemic immunosuppression is occasionally required for severe vision-threatening disease.
- Surgical treatments include excision of tarsal papillae and superficial keratectomy for shield ulcer.

### Referral guidelines

- Most seasonal and perennial allergic conjunctivitis can be managed in general practice.
- If severe symptoms are not relieved by topical treatment with mast cell stabilisers or dual action agents, refer.
- Vision threatening forms, i.e. vernal and atopic keratoconjunctivitis, should be referred for initial assessment and will need ongoing review.
- If corneal disease such as shield ulcer is suspected, refer urgently.

## 7.4 Bacterial Conjunctivitis

Bacterial conjunctivitis is a common and usually benign cause of red eye. Common organisms causing conjunctival infection are *Staphylococcus aureus* and *epidermidis*, *Streptococcus pneumoniae*, *Haemophilus influenzae*, and *Pseudomonas aeruginosa*. Rare but severe hyperacute onset may be due to *Neisseria gonorrhoea*.

### Symptoms

- Sticky discharge (often with lids glued together on waking).
- Moderate lid swelling.
- Mild irritation rather than sharp or aching pain.
- Vision usually remains good, unless reduced by presence of discharge.
- May be unilateral or bilateral.

### Signs

- Diffuse conjunctival hyperaemia especially in the fornices.
- Chemosis (conjunctival oedema).
- Purulent discharge.

### Slit lamp signs

- Examine cornea for marginal keratitis, which may be associated with staphylococcal infection.
- Secondary corneal ulceration may occur as, although rare, gonococcus and pseudomonas can rapidly penetrate an intact cornea.

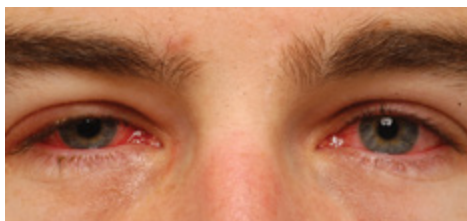### Immediate management

- Swab for culture not indicated prior to initial therapy.
- Start topical antibiotic drops or ointment: either chloramphenicol 0.5% drops (hourly at first, reducing to qds for 5–7 days) or 1% ointment qds. Or, if milder, fucithalamic ointment bd.

### Long-term management

#### If infection is not responding to treatment:

1. Ensure patient has been using



Bilateral injected conjunctiva in bacterial conjunctivitis.

drops frequently enough.

2. Consider differential diagnoses (virus, Chlamydia, allergic).
3. Stop all treatment for 24 hours and swab for bacterial, viral and chlamydial culture.
4. Refer.

### Referral guidelines

- Refer only if recurrent or chronic, or if diagnosis not clear, or if corneal signs suspected.
- Urgent referral required if Gonococcal conjunctivitis suspected (very rare).

## 7.5 Adenovirus Conjunctivitis

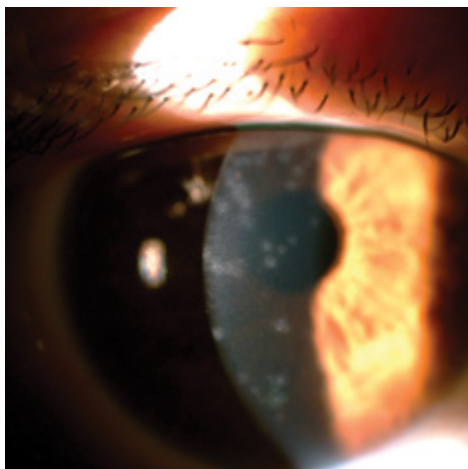
- A common cause of infectious conjunctivitis not responding to topical antibiotic treatment
- Most cases are mild self-limiting infections but some may cause more severe vision-threatening complications.
- Pharyngo-conjunctival fever consists of fever, sore throat and follicular conjunctivitis and is usually caused by adenovirus types 3, 4 or 7. Symptoms generally last 1–4 weeks.
- Epidemic keratoconjunctivitis consists of follicular conjunctivitis and keratitis and is usually caused by adenovirus types 8 and 19. Symptoms may last for more than 3 months.

### Symptoms

- Red eyes.
- Irritation (from mild to severe).
- Watery or serous discharge.
- Lid swelling (from mild to severe).
- Photophobia.
- May have blurred vision if cornea affected.
- May be preceded by a prodrome of fever, sore throat.
- Often starts in one eye but usually becomes bilateral within a few days.

### Signs

- Conjunctival injection.
- Subconjunctival haemorrhages.
- Conjunctival pseudomembranes (sheets of white/yellow material lining the lids and fornices which can be wiped or peeled off easily with a cotton tip).
- The conjunctival discharge is thinner and less copious than in bacterial conjunctivitis.
- Pre-auricular adenopathy.
- Vision may be reduced down to 6/12 or 6/18 if keratitis develops.



Sup-epithelial corneal opacities in adenovirus conjunctivitis.

## Slit lamp signs

- Conjunctival follicles (yellow/pink lumps on inside of lids).
- Conjunctival pseudomembranes.
- Conjunctival scarring and symblepharon (adhesions between conjunctiva of lid and conjunctiva on eyeball) in severe cases.
- Epithelial keratitis – superficial punctate uptake of fluorescein.
- Stromal keratitis – small, round, grey, “granular” scattered sub-epithelial infiltrates develop later and may persist for months.

## Immediate management

- Advise precautions to reduce transmission: wash hands after instilling drops, no sharing of towels, utensils etc. The condition is very contagious via airborne droplets, direct contact, or fomites/surfaces. Viral particles are shed for up to 1 month after onset.
- Advise patient to stay home from work or school until discharge is settled.
- Cold compresses for comfort.
- Artificial tears for comfort.
- Prophylactic topical antibiotic drops or ointment (chloramphenicol qds or fucithalamic bd).
- Pseudomembranes may be removed with forceps at the slit lamp.

## Long-term management

- Most cases will resolve with the above treatment.
- Topical corticosteroids (Pred Mild, FML or Flucon qds) may be used if conjunctival scarring or symblepharon are present, and sometimes in the situation of keratitis affecting the central cornea and reducing visual acuity. Steroid use should only be instigated by a specialist as it can be harmful in the case of misdiagnosis, and there can be problems with rebound inflammation/keratitis on cessation.

## Referral guidelines

- Most viral conjunctivitis can be managed in general practice.
- Refer if uncertain of diagnosis, if any corneal signs, for removal of pseudomembranes, or if steroid therapy contemplated.

## 7.6 Chlamydial Conjunctivitis

Chlamydial conjunctivitis (also known as inclusion conjunctivitis) is an acute to chronic conjunctivitis seen especially in sexually active young adults and caused by the organism *Chlamydia trachomatis*.

Serotypes A, B, C cause trachoma and serotypes D to K cause inclusion conjunctivitis. As a sexually transmitted disease it may be associated with urethritis, cervicitis, etc. The organism is also the commonest cause of neonatal conjunctivitis, acquired in the birth canal.

### Symptoms

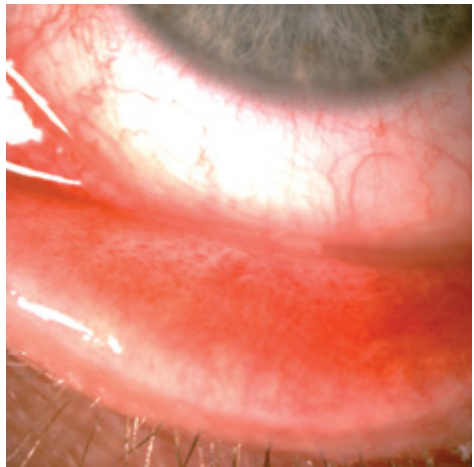- Red eyes, mucopurulent discharge, irritation, although there may be minimal symptoms.
- Bilateral or unilateral.
- Key feature is non-responsiveness to topical antibiotics, with prolonged duration of symptoms.
- Often sub-acute onset and may be 3 weeks or more before diagnosis is made.

### Signs

- Conjunctival hyperaemia.
- Serous or mucoid discharge.
- Pre-auricular node.

### Slit lamp signs

- Tarsal conjunctival follicles.
- Small peripheral or central greyish corneal infiltrates.
- Diffuse corneal epithelial haze and punctate uptake of fluorescein.



Follicles in chlamydial conjunctivitis.

### Immediate management

- Swab for direct Chlamydial immunofluorescence test or for Chlamydial culture.
- Treat if clinically suspicious: Azithromycin 1gm po stat., Doxycycline 100mg po bd for 7 days or Erythromycin 500mg qid po for 7 days.

### Long-term management

- Follow up at 2 to 3 weeks to check for resolution and discuss culture results.

### Referral guidelines

- Refer patient and sexual partners for STD evaluation if the conjunctival swab confirms the organism.



## 7.7 Pingueculum and Pterygium

Both are benign degenerations of the conjunctiva related to sun exposure. They occur more in men than women, rarely in children and are more common in those with outdoor occupations and in countries closer to the equator.

### Symptoms

- Irritation and occasionally painful.
- Occasionally reduced vision from a large pterygium that is affecting corneal curvature or transparency.

### Signs

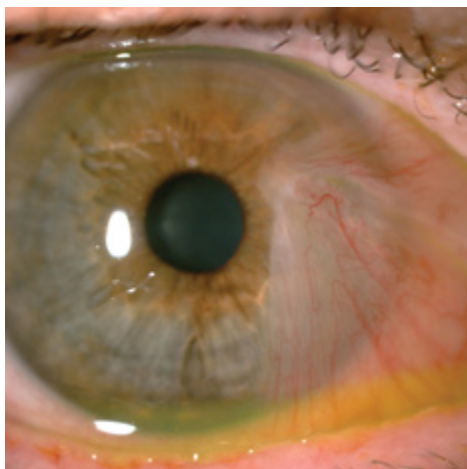
- Redness and thickening of the conjunctiva over the sclera up to the limbus, extending on to the cornea in the case of pterygium.
- Pingueculum occurs both nasally and temporally.
- Pterygium is more common on nasal conjunctiva but may occur temporally.

### Slit lamp signs

- Pingueculum shows a roughly triangular area of conjunctival thickening with creamy or yellowish subconjunctival tissue adjacent to the limbus. It may become inflamed with engorged vasculature.
- Pterygium shows a tongue-shaped area of conjunctival thickening, scarring and vascularisation, extending from the bulbar conjunctiva across the limbus and on to the cornea.

### Immediate management

- Sun protection with sunglasses and hat.
- Lubricant eye drops.
- Short course of steroids for marked inflammation.



Pterygium extending close to the visual axis of the right eye.

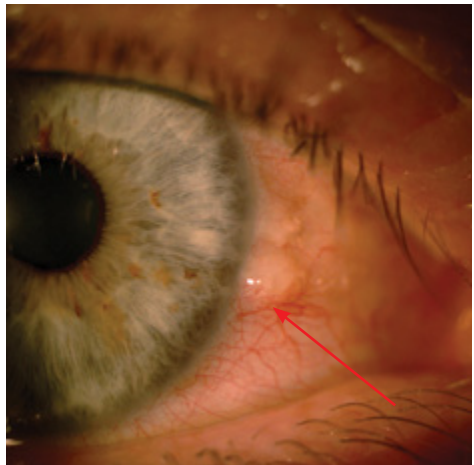
## Long-term management

- Excision of the lesion under local anaesthetic.
- Pterygium may recur months or years following excision. Combining excision with a free conjunctival autograft taken from superior conjunctiva reduces the rate of recurrence to about 2%. Grafts may be secured with sutures or tissue glue.
- Very large pterygium extending across the visual axis may require superficial keratectomy or lamellar corneal grafting to restore vision.

## Referral guidelines

Pterygium and pingeculum causing cosmetic embarrassment or significant symptoms of irritation may be referred at the patient's request.

Pterygium affecting the vision should be referred to prevent more permanent corneal damage.



Pingueculum with mild inflammation around it.

## 7.8 Ocular Surface Squamous Neoplasia

This includes pre-invasive conjunctival intraepithelial neoplasia (CIN), and invasive squamous cell carcinoma (SCC). It occurs especially in white males, middle-aged and older, and incidence increases closer to the equator.

Other risk factors are smoking, HIV and Xeroderma Pigmentosum.

### Symptoms

- Usually asymptomatic and first noted as a visible lesion on the eye.
- Corneal lesions may present with reduced vision.
- Sometimes the patient may experience mild irritation in the eye.

### Signs

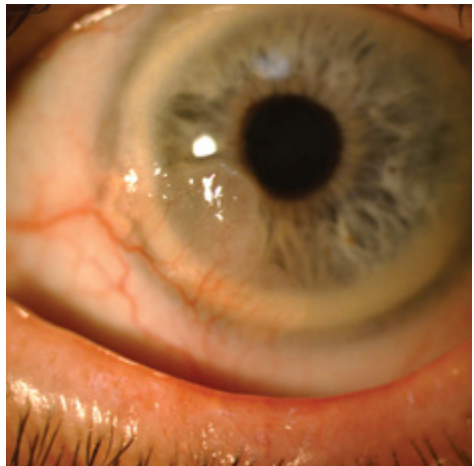- Grey-white or pink, flat or fleshy lesion, seen especially at the limbus or on the exposed bulbar conjunctiva.
- May occasionally be seen in the fornices or palpebral conjunctiva.

### Slit lamp signs

- Conjunctival limbal or corneal lesion with gelatinous or fernlike appearance, superficial corkscrew vessels.
- May show leukoplakia (keratinisation of the conjunctiva seen as a white patch). Subtle lesions may only be identified with the aid of staining drops such as Lissamine green.
- Intraocular or orbital extension in advanced cases.

### Immediate management

- Referral for clinical identification and biopsy for histological examination.



Ocular surface squamous neoplasia – note the irregular surface and the feeder vessels.

### Long-term management

- Small lesions should be completely excised at biopsy, with cryotherapy to surrounding conjunctiva.
- Larger lesions may additionally need topical therapy with Mitomycin-C or Interferon alpha-2-beta eye drops to shrink the lesions or for treatment of recurrences.
- Specialist long-term follow-up is needed because of a significant rate of recurrence or new lesions.

### Referral guidelines

- Any acquired suspicious conjunctival lesion should be referred and should be seen within a few months.

## 7.9 Pigmented Conjunctival Lesions

### **Naevus, Primary Acquired Melanosis (PAM) and Malignant Melanoma (MM)**

Naevi commonly become visible during puberty and may remain benign and enlarge or may rarely undergo malignant transformation.

- Primary Acquired Melanosis (PAM) appears in middle-aged Caucasians. 20% will undergo malignant transformation.
- Malignant Melanoma (MM) is a rare lesion seen in elderly Caucasians, either arising de novo or from a pre-existing naevus or PAM.

### **Symptoms**

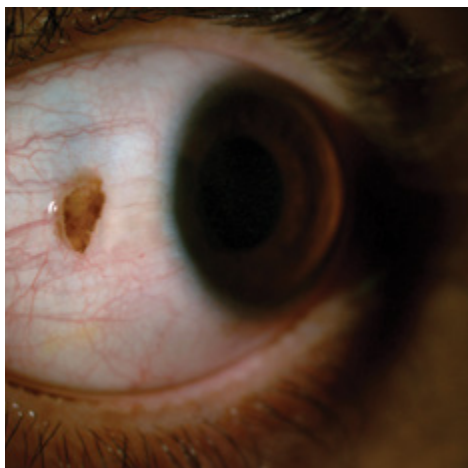
- Visible conjunctival pigmentation usually without other symptoms.

### **Signs**

- Naevi may be pigmented or amelanotic. They are common on the conjunctiva over the sclera (bulbar conjunctiva) but rare on conjunctiva lining the lids (tarsal conjunctiva).
- Primary Acquired Melanosis appears as flat, brown scattered pigmentation anywhere in the conjunctiva, but most commonly on the bulbar conjunctiva.
- Malignant melanoma is a nodular brown or black mass on bulbar or tarsal conjunctiva. May have feeder vessels and may be mobile or fixed to underlying sclera. Pigmentation is normally more dense than naevi or PAM.

### **Slit lamp signs**

- Naevi usually have small clear cysts within the pigmentation, and are located superficially.
- Primary Acquired Melanosis pigmentation usually has a granular appearance and is located superficially.
- Malignant melanoma is often a nodular brown or black mass on bulbar or tarsal conjunctiva. May have feeder vessels and may be mobile or fixed to underlying sclera.



Conjunctival naevus.

## Immediate management

- Photography for documentation and observation is appropriate for lesions thought to be benign.
- Suspicious lesions will be biopsied for histological examination and for small lesions excisional biopsy may be curative.
- Primary acquired melanosis with atypia (pre-malignant) is treated by excision, cryotherapy or topical mitomycin-C depending on extent.
- Malignant melanoma is treated by excisional biopsy. Orbital or intraocular spread requires exenteration (removal of entire contents of orbit including conjunctiva, eye, lids, and muscles).

## Long-term management

- Long-term ophthalmic follow-up is necessary as recurrence or progression may occur at the same site or elsewhere on either eye.
- Co-management with an oncologist is required for melanoma as metastasis may occur, especially to the liver.

## Referral guidelines

- Refer any acquired or changing pigmented conjunctival lesion for specialist assessment.

## Differential diagnosis

- Mascara deposits.
- Long-term Dipivefrine use.
- Scleromalacia with visible ciliary body: see anterior scleritis.
- Episcleral pigment spots at site of perforating vessels: small grey spots in each quadrant that are a normal finding.
- Racial pigmentation.

## 7.10 Ocular Cicatricial Pemphigoid

A rare autoimmune conjunctival inflammation that may produce relentless scarring resulting in eventual blindness. Its occurrence is unusual in patients younger than 55 years of age.

The diagnosis should be considered in any case of chronic remitting/relapsing conjunctivitis. Definitive diagnosis and systemic immunosuppression is essential to prevent progression.

### Symptoms

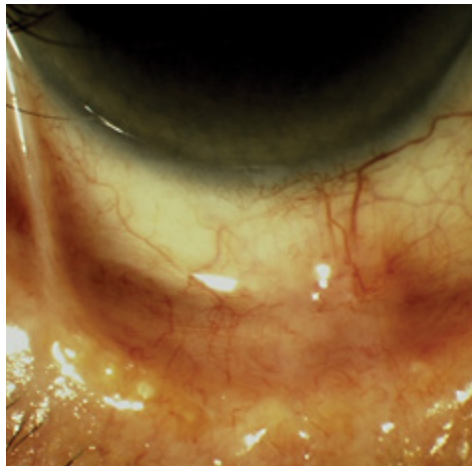
- Chronic remitting and relapsing bilateral redness, irritation, watering, photophobia, blurred vision.

### Signs

- Associated blistering and scarring may affect other mucosal surfaces (oral, nasal, pharyngeal, anal, genital) and also the skin.
- Enquiry about symptoms such as oesophageal stricture, mucosal ulceration should raise the possible diagnosis.

### Slit lamp signs

- Scarring of bulbar conjunctiva especially in the medial canthus.
- Fibrosis of the conjunctival fornices leading to shortening of the distance between the limbus and the fornix (forniceal shortening).
- Symblepharon: adhesion between bulbar and tarsal conjunctivae, progressing eventually to ankyloblepharon (adhesion between the lids) or total fusion of the lids to the globe.
- Lid changes with entropion and trichiasis.
- Disruption of the tear film.
- Corneal scarring, vascularisation and keratinisation.



Adhesions between the lower lid and the globe, known as symblepharon.

## Immediate management

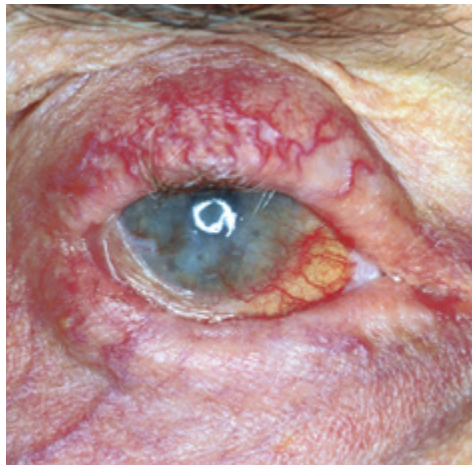
- Topical antibiotic, corticosteroid and artificial tear drops for relief of symptoms.
- Conjunctival biopsy will be carried out to confirm the diagnosis using fluorescent immunostaining to demonstrate specific inflammatory changes at the level of the epithelial basement membrane.

## Long-term management

- Referral to clinical immunologist for systemic immunosuppression.
- Lid surgery for trichiasis and entropion.
- Mucous membrane grafting for reconstruction of the fornices.
- Any surgery on the conjunctiva may precipitate a flare up the inflammation and further scarring so should be delayed if possible until the patient is immunosuppressed.

## Referral guidelines

- Any chronic conjunctivitis not responding to topical treatment should be referred. Earlier diagnosis allows immunosuppression to halt the disease at a less severe stage.



Severe cicatrizing conjunctivitis.



## 7.11 Stevens Johnson Syndrome

A rare autoimmune skin and mucous membrane blistering condition occurring especially in children.

It may be precipitated by infection (Mycoplasma, HSV), drugs (salicylates, antibiotics, many others), radiotherapy or malignancy. The clinical course is characterised by a period of acute inflammation and scarring. Once this has settled the conjunctiva does not show ongoing primary inflammation, but any damage will continue to have secondary effects on the tear film, cornea, etc.

### Symptoms

- Acute onset of fever, red eyes, rash, arthralgia, respiratory symptoms.

### Signs

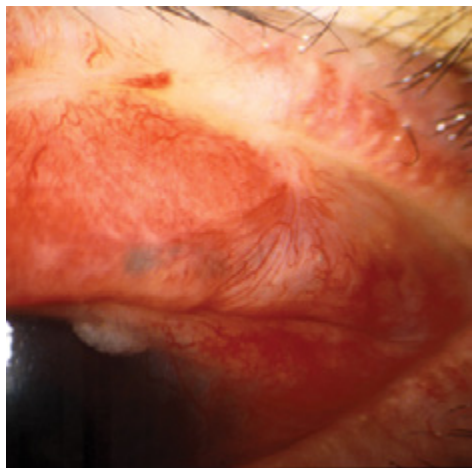
- Target skin lesions and oral mucosal ulceration.
- Patients are usually hospitalised by the severity of the systemic disease and there is up to a 33% mortality rate.

### Slit lamp signs

- Acute: conjunctivitis, conjunctival pseudomembranes, symblepharon formation (adhesions between eyelid conjunctiva and eyeball conjunctiva), iritis.
- Chronic: conjunctival scarring, tear abnormalities, lid deformities, trichiasis, corneal scarring, vascularisation or perforation.

### Immediate management

- Topical antibiotic ointment. Glass rodding to prevent symblepharon formation. Topical steroid drops.
- Conjunctival scarring may be reduced by intravenous Methylprednisolone.



Marked scarring of the inside of the upper lid (tarsal conjunctiva) in cicatricial conjunctivitis.

### Long-term management

- Dry eye symptoms require lifelong specialist ophthalmic management with artificial tear drops and ointments, punctal plugs, moist chamber spectacles, and topical steroids.
- Secondary lid malposition, entropion and trichiasis may require lid surgery.
- Mucous membrane grafting for reconstruction of the fornices.

### Referral guidelines

- Hospitalisation and referral to ophthalmic services during initial acute episode is essential.



## 8 *Cornea*

## 8.1 Bacterial Keratitis

Bacterial infection of the cornea usually presents as a corneal ulcer with white infiltrative change associated with an epithelial defect. Common organisms include *Staphylococcus aureus*, *Staphylococcus epidermidis*, *Streptococcus pneumoniae*, and *Pseudomonas aeruginosa*.

- This is a sight-threatening emergency.

### Symptoms

Pain, foreign body sensation, redness, photophobia, often discharge. Variable reduction in vision, sometimes severe. A risk factor normally exists:

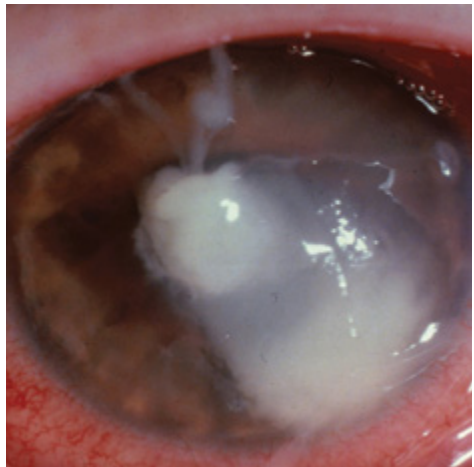
- Trauma.
- Contact lenses (especially if slept in).
- Steroid drop use.
- Surgery.
- Lid problems such as ectropion causing exposure, or entropion causing abrasion.
- Other existing corneal or ocular surface disease, e.g. dry eye, blepharitis.

### Signs

- Red eye – usually limbal injection.
- White opacity or opacities visible on cornea (infiltrates).
- Fluorescent staining of cornea.
- There may be a hypopyon if severe keratitis, or if rapidly progressing.

### Slit lamp signs

- Corneal opacity will be visible, with overlying epithelial defect (staining with fluorescein)
- Cells in anterior chamber.



Hypopyon and corneal opacity in bacterial ulcer.

## Immediate management

### Suspected bacterial keratitis is an emergency.

- No treatment should be initiated as diagnostic corneal scrapes and swabs may be required, and the use of any topical medication can affect the results.
- Patient should be referred urgently (within 8 hours), particularly if they are contact lens wearers as these patients are at risk of pseudomonas infection, which can progress very rapidly.

## Long-term management

- After diagnostic corneal scrapes, treatment with intensive topical antibiotics is commenced. This is usually done as a hospital inpatient, and treatment is either a combination of Cefuroxime and Tobramycin drops, or Ciloxan drops as a single agent. When the keratitis is settling topical steroids may be required but this should only ever be instigated by a specialist.
- If corneal scarring remains then surgical procedures may be required, including corneal transplantation.

## Referral guidelines

- If suspected, refer urgently (within 8 hours).

## 8.2 Herpes Simplex Keratitis

The causative agent is normally Herpes Simplex Virus (HSV) serotype 1, but rarely can be HSV2.

70–90% of the population are seropositive for HSV1, primary infection usually occurring in childhood. Occasionally primary infection may have accompanying self-limiting blepharoconjunctivitis with vesicular rash on the lids and red eye. HSV keratitis is very rare at the time of primary infection.

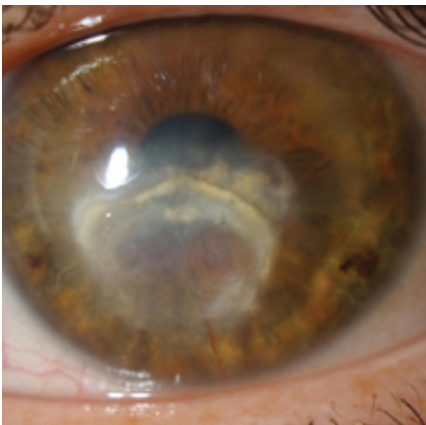HSV remains latent in trigeminal ganglion after primary infection and may reactivate with migration to the cornea causing keratitis. The different forms of HSV keratitis are:

- Epithelial (usually dendritic ulcer)
- Stromal
- Endothelial (disciform keratitis)
- Neurotrophic (*See 8.10 Neurotrophic Keratitis on page 84*)

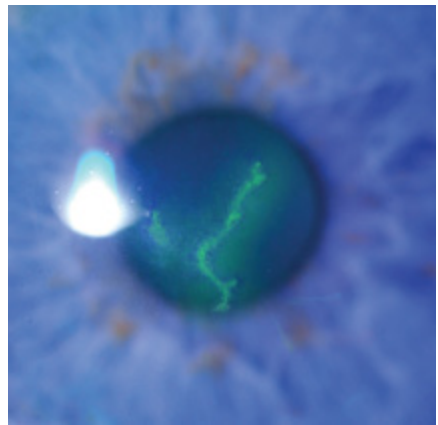
### Symptoms

Variable degrees of discomfort and vision loss:

- Dendritic ulcers have foreign body sensation and moderate discomfort, although vision tends to be unaffected unless ulcer is in visual axis.
- Stromal and endothelial keratitis have moderate discomfort and mild to severe visual loss depending on severity of keratitis.
- Neurotrophic ulcers classically have no discomfort and present when the ulcer affects the visual acuity.



Disciform keratitis in Herpes Simplex keratitis.



Dendritic ulcer in Herpes Simplex keratitis.

## Signs

- Redness usually occurs with all types of HSV keratitis as well as a variable reduction in vision
- Dendritic ulcer: semi-opaque ulcer on cornea, classical branching shape, stains with fluorescein.
- Geographic ulcer: “map” shaped ulcer, which represents the advanced form of dendritic ulcer, normally only seen when patient has been treated inappropriately with steroid drops.
- Stromal keratitis – white/milky area on cornea. Usually does not stain with fluorescein
- Endothelial/disciform keratitis – slightly hazy cornea, usually centrally. No stain with fluorescein.
- Neurotrophic ulcer – central oval ulcer, stains with fluorescein. Corneal sensation will be absent (test with a cotton tip or corner of tissue paper – compare to the other eye).

## Slit lamp signs

- Stromal keratitis is easier to define on slit lamp as depth of corneal opacity can be located more easily. There may also be corneal blood vessels to the opaque area.
- Endothelial/disciform keratitis will have keratic precipitates (collections of inflammatory cells) on the endothelium. And the overlying corneal stroma will be hazy and oedematous.
- Neurotrophic ulcer – edge of ulcer has a thickened grey appearance and there may be associated corneal blood vessels.

## Immediate management

- If classical dendritic ulcer (especially if past history of HSV keratitis) then Zovirax ointment 5 times per day for up to 2 weeks. Significant improvement should be noted after a week.
- All other types of HSV keratitis require referral for treatment. This usually involves topical steroid for endothelial/disciform keratitis, and sometimes involves topical steroid for stromal keratitis. The use of steroid drops whilst necessary for these types of HSV keratitis are very dangerous if there is any epithelial breakdown or ulcer. Steroids should only be prescribed by a specialist.
- ALL cases of HSV keratitis require Acyclovir ointment 5 times per day.
- Neurotrophic ulcers may require either a temporary tarsorrhaphy or a Botox ptosis, and hence need referral.

## Long-term management

- Epithelial keratitis is usually short-lived.
- Stromal and disciform keratitis can be much more prolonged, and often require a very slow taper of topical treatment over many months (and sometimes years).
- Patients with repeated recurrences benefit from long-term Acyclovir 400 mg bd or Valacyclovir 500mg daily to help reduce the number of recurrences.

## Referral guidelines

- Refer all stromal, endothelial, disciform and neurotrophic ulcers urgently (within 24 hours)
- Refer epithelial/dendritic keratitis if not improving on topical Acyclovir 5 times per day after 1 week.



## 8.3 Herpes Zoster Keratitis

Reactivation of dormant varicella zoster virus in the sensory ganglion results in herpes zoster (shingles) of the innervated dermatome. 15% of cases involve the ophthalmic branch of the trigeminal nerve resulting in herpes zoster ophthalmicus (HZO).

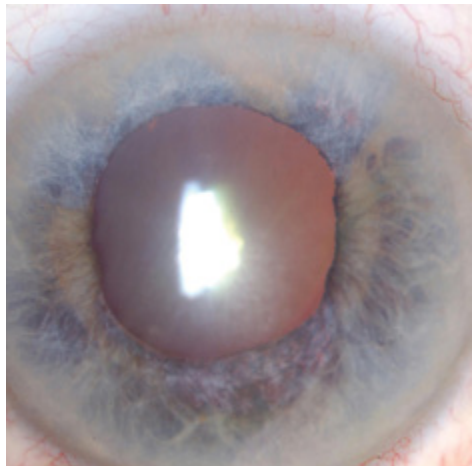
The eye itself is affected in less than 40% of cases, and usually presents with keratouveitis, although patients may less commonly develop conjunctivitis, glaucoma, retinitis, scleritis, optic neuritis, or cranial nerve palsies. Once the eye is affected with keratouveitis the condition can become chronic, recurring each time treatment is ceased, and sometimes recurring years after settling.

### Symptoms

- Initial event: Viral prodrome, tingling or pain, rash (papules → vesicles → pustules → scabs) in the V1 dermatome. If the tip of the nose is involved it implies the nasociliary nerve is involved which increases the likelihood of ocular complications.
- Any ocular involvement is not usually evident for 1–2 weeks after onset of the rash. Patients usually present with redness, discomfort in the eye, and reduced vision due to keratitis.
- Long-term recurrences present typically with reduced vision and redness. Pain is often not a feature as the cornea tends to become irrevocably anaesthetic after the initial keratouveitis.

### Signs

- Initial rash (papules → vesicles → pustules → scabs) in the V1 dermatome.
- Red eye.
- Corneal haze or opacity.
- Irregular or sluggish pupil in patients with recurrences.



Loss of iris pigment in herpes zoster inflammation, note pale periphery.

### Slit lamp signs

- Conjunctival injection
- Corneal stromal opacities, and sometimes pseudodendrites (raised linear or branching opacities), on the corneal surface.
- Possible corneal oedema (or thickening) with underlying keratic precipitates (disciform keratitis).
- Long-term recurrences have similar appearance.
- Pupil irregularity and iris transillumination in long-standing or recurrent cases.

### Immediate management

- If diagnosed within a few days of development of rash treatment with oral Acyclovir 800 mg 5 times per day for 5 days should be given, or Valacyclovir 1 gram tds for 1 week.
- For keratouveitis the standard treatment is topical steroid, initially Pred Forte, tapering to Pred Mild or FML. This treatment should only be instigated by a specialist as complications can occur in the presence of any epithelial defect.
- This condition is not to be treated with Zovirax ointment.

### Long-term management

- Once started on topical steroid drops patients may be on treatment for many months, or even years. During that time patients need to be regularly monitored to ensure control of keratouveitis as well as for complications from long-term steroid use, such as glaucoma and cataract.

### Referral guidelines

- Referral not required if only rash present.
- Refer if redness or soreness of the eye itself develops, or if vision drops. This may not be apparent until 2 weeks after initial rash. If ocular involvement suspected refer within 24 hours.

## 8.4 Acanthamoeba Keratitis

Acanthamoeba are ubiquitous free-living protozoa that are found in soil, dust, sea water, fresh water and chlorinated water. They encyst in order to survive adverse environments, including extreme temperature.

Acanthamoeba keratitis is rare but the incidence is increasing. Early treatment is associated with full recovery, but late diagnosis can lead to profound corneal scarring and ocular inflammation with ultimate blindness.

The main risk factor is contact lens wear, especially in cases of poor hygiene, or exposure of the contact lenses to tap water, or whilst swimming. Trauma is another risk factor, especially in an agricultural setting.

### Symptoms

- Initial foreign body sensation and mild reduction of vision.
- This is followed by increasing pain, and in particular intense photophobia (usually beyond what would be expected judging purely by ocular signs).
- If untreated then profound inflammation, pain and reduction of vision.

### Signs

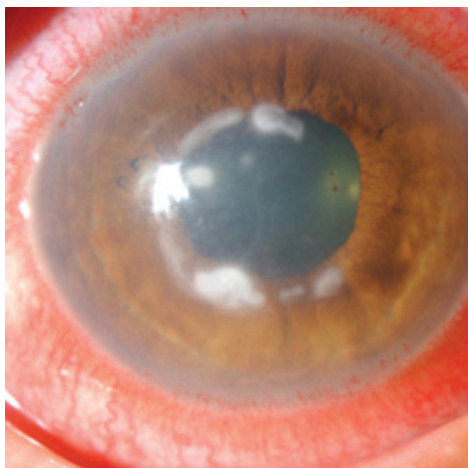
- Photophobia.
- Corneal hazing or infiltrate/opacities.

### Slit lamp signs

- **Early signs:** punctate corneal change, redness, perineural infiltrates (opacity and apparent thickening along the corneal nerves).
- **Later signs:** increasing redness, corneal infiltrates/opacities, often in a ring shape.

### Immediate management

- In any presumed infective keratitis, corneal scrapes are taken to send to microbiology to establish the causative gent. PCR may also be used to identify the organism.



Acanthamoeba ring infiltrate.

- If *acanthamoeba* is suspected then confocal microscopy is a quick and non-invasive test that can show *acanthamoeba* in the cornea. There is only one confocal microscope in New Zealand, owned by the University of Auckland and based at Greenlane Hospital, Auckland. Access to this microscope can be arranged by any ophthalmologist.
- Treatment is started empirically after scrapes are taken, and usually comprises admission to hospital for hourly Brolene drops, together with either hourly chlorhexidine drops or hourly polyhexamethylene biguanide drops.

### Long-term management

- Mild cases usually fully resolve on standard treatment, although usually require drops for several months to ensure the *acanthamoeba* has been eradicated.
- Long-term management of moderate to severe cases can be very complex and protracted. These eyes become very inflamed and develop severe corneal scarring as well as other complications of severe inflammation such as iris damage, glaucoma, cataract and scleritis. Corneal transplantation is normally required. Ideally this would occur once the eye has settled with the aim of restoring vision, but occasionally in severe disease transplantation is required as an emergency procedure to save the eye, such cases still have a poor prognosis.

### Referral guidelines

- Any contact lens wearer (or any patient who suffers corneal trauma) who develops a red or painful eye, especially if a corneal opacity is noted, should be referred urgently in less than 8 hours. The final prognosis in any infective keratitis is significantly affected by the speed of diagnosis and instigation of appropriate treatment.

## 8.5 Fungal Keratitis

Relatively uncommon cause of keratitis. Usual organisms are *Fusarium*, *Aspergillus* and *Candida*.

### Risk factors:

- Trauma with contamination from organic matter.
- Immunosuppression, particularly topical steroid drops.

### Symptoms

- Varies from insidious to rapid
- Redness.
- Soreness.
- Photophobia.
- Reduced vision.

### Signs

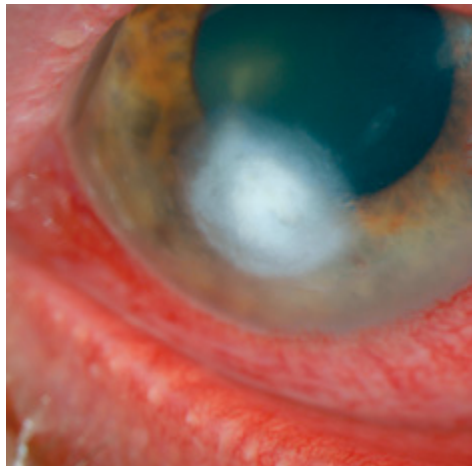
- Redness.
- Opacity (infiltrate) visible on cornea, usually associated with fluorescein stain.

### Slit lamp signs

- Infiltrate on cornea often grey in colour, and frequently has feathery edges.
- May have smaller "satellite" lesions around it.
- Usually has associated fluorescein stain.
- Commonly has anterior chamber reaction with cells and flare.

### Immediate management

- Immediate referral is required for diagnostic corneal scrapes to be taken, plus treatment with appropriate antifungals to be started (e.g. natamycin, amphotericin, fluconazole, itraconazole – as indicated by scrape results).



Corneal opacity with classic fluffy margins typical of fungal keratitis.

### Long-term management

- Fungal keratitis often follows a very protracted course, with patients on antifungals for many months.
- Occasionally corneal transplantation is required to either control progressive disease or to remove residual scarring once settled.

### Referral guidelines

- Any patient who suffers corneal trauma who then develops a red or painful eye, especially if a corneal opacity is noted, should be referred urgently – in less than 8 hours. The final prognosis in any infective keratitis is significantly affected by the speed of diagnosis and instigation of appropriate treatment.

## 8.6 Marginal Keratitis

Common inflammatory reaction due to hypersensitivity to staphylococcal exotoxin on the peripheral cornea. Usually seen in patients with chronic blepharitis or rosacea.

### Symptoms

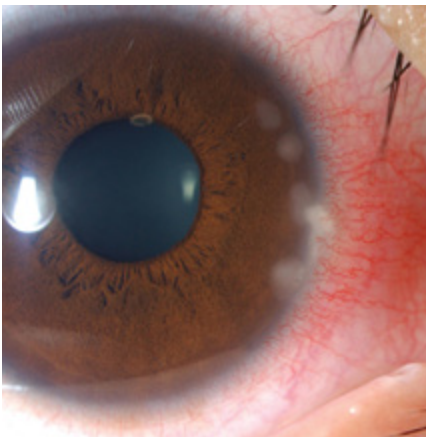
- Redness, irritation, pain, foreign body sensation and photophobia.
- Vision is not usually affected.
- Patient may have suffered similar symptoms before.

### Signs

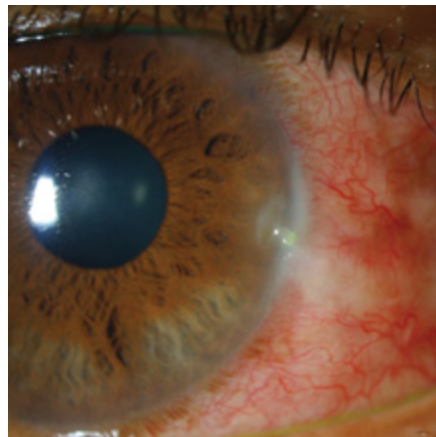
- Redness, often in one area of the limbus (most commonly in the 2, 4, 8, and 10 o'clock positions).
- An opacity may be seen in the peripheral cornea adjacent to the area of redness.

### Slit lamp signs

- Redness, often in one area of the limbus (most commonly in the 2, 4, 8, and 10 o'clock positions).
- Infiltrate/opacity seen in the peripheral cornea, usually with a clear zone of cornea between the infiltrate and the limbus. The infiltrate usually does not stain with fluorescein – if it does stain then it raises the suspicion that the infiltrate is infective keratitis, rather than staphylococcal hypersensitivity.



Multiple peripheral corneal opacities from marginal ulcers causing scars from 2-4 o'clock.



Peripheral corneal opacity and injection from marginal keratitis.

### Immediate management

- Treat blepharitis (*See 7.1 Blepharitis on page 41*).
- Antibiotic ointment, e.g. chloramphenicol qds, or fucithalamic bd for a week.

### Long-term management

- If symptoms fail to settle on initial treatment then topical steroids may be considered by an ophthalmologist. This is not without risk as if the diagnosis is incorrect and the corneal infiltrate is infective then steroids can cause significant worsening, and even corneal perforation.

### Referral guidelines

- If not settling with antibiotic treatment and blepharitis treatment after 1 week then refer to an ophthalmologist semi-urgently (within 3 days).



## 8.7 Peripheral Ulcerative Keratitis

An aggressive sight-threatening keratitis affecting the corneal periphery.

It is usually associated with an underlying systemic disease such as rheumatoid arthritis, Wegener's granulomatosis, systemic lupus erythematosus, polyarteritis nodosa, relapsing polychondritis, Churg-Strauss syndrome. It can also be idiopathic and in that situation is often termed Mooren's ulcer.

### Symptoms

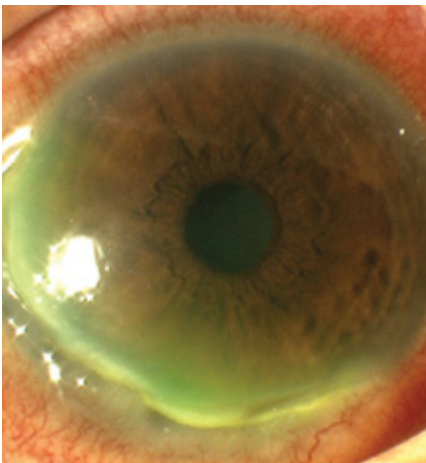- The patient normally suffers pain (which can be severe) and redness.
- Visual acuity may be reduced, but is often normal.

### Signs

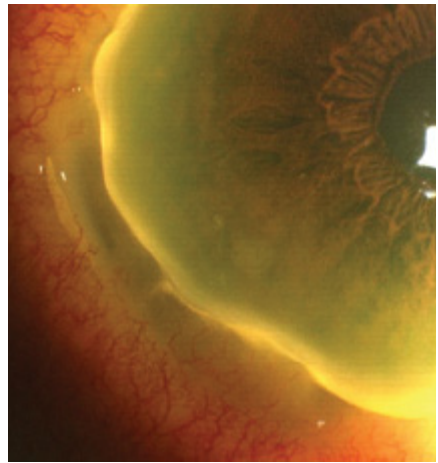
- Redness, particularly near the limbus. As the condition advances this can become severe due to associated scleritis.
- Peripheral corneal epithelial breakdown which stains with fluorescein.
- Opacity of the cornea peripherally may also be noted.

### Slit lamp signs

- Peripheral corneal thinning and epithelial breakdown, often with associated corneal opacities/infiltrates.
- Adjacent intense conjunctival/limbal injection.



Peripheral ulcerative keratitis.



Peripheral thinning in peripheral ulcerative keratitis.

### Immediate management

- If secondary bacterial infection is suspected then diagnostic scrapes are taken and intense topical antibiotic treatment is started.
- Full history and screen for underlying conditions – systemic immunosuppression is the mainstay of treatment in these cases and the patient is usually managed in conjunction with an immunologist or rheumatologist.
- In general, topical steroids are contraindicated as these encourage further corneal melting and potential perforation.
- If corneal perforation occurs, emergency surgery involving either a full-thickness or partial-thickness (lamellar) corneal transplant is required.

### Long-term management

- These patients often have a long and difficult course. Peripheral ulcers can often be recurrent and patients often require significant levels of systemic immunosuppression to control inflammation and corneal melting.
- Patients who require corneal surgery in general have a poor prognosis with disease recurrence and other associated ocular morbidity.

### Referral guidelines

- If suspected refer urgently within 24 hours.

## 8.8 Recurrent Erosion Syndrome

This condition in the epithelial surface of the cornea repeatedly breaks down. Usually the patient has a predisposing condition that weakens the attachment of the epithelium to the underlying layers of the cornea.

This is usually map-dot-fingerprint dystrophy, also called epithelial basement membrane dystrophy, which is an otherwise harmless hereditary corneal dystrophy affecting around 1:15 of the population. Usually the precipitating event is a traumatic scratch or abrasion, which heals rapidly. Subsequently, the area of weakened epithelium can stick to the inside of the eyelid as the patient sleeps, and on entering REM sleep, or on waking, the weak area of epithelium tears off. This process can repeat every day, with the epithelium healing during the daytime, and tearing off again overnight.

### Symptoms

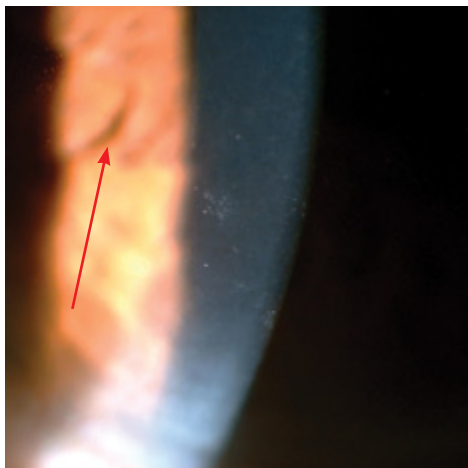
- Typically the patient experiences intense pain in the eye on waking in the morning, or is woken from sleep in the middle of the night with intense pain. This generally settles over an hour or two, but recurs the next night. If the area of recurrent erosion is in the visual axis the vision may also be reduced.

### Signs

- Often there may be no obvious signs. If the patient is seen early in the morning, shortly after an episode, then an area of epithelial loss may still be visible with fluorescein stain.
- Diagnosis is normally made on the typical history given by the patient

### Slit lamp signs

- If the patient is examined within a couple of hours of an episode, an epithelial defect will be present
- In general, however, there may be very little to see except for the small microcysts and epithelial ridges typical of underlying map-dot-fingerprint dystrophy



Sub-epithelial microcysts in Map-Dot-Fingerprint Dystrophy.

## Immediate management

- If an epithelial defect is present then padding may make the eye more comfortable, although some patients are less comfortable with a pad – it is generally best to leave the choice to the patient
- Prophylactic antibiotic drops such as Chloramphenicol qds may be considered. Some patients prefer ointment, and clinically there is little to choose between drops and ointment.

## Long-term management

Prevention of recurrence is the key to long-term management. If the patient can avoid an episode of erosion for several months (6–12 months) then they can usually form the required anchoring hemidesmosomes and achieve a cure.

The sequence of treatment is:

1. Copious ointment at bedtime – this creates a greasy barrier between the lid and the epithelium and prevents sticking between the two. It needs to be used every night for several months, and most patients will achieve a cure. Lacrilube, Polyvisc or Vita-Pos are good options.
  2. If the patient has significant blepharitis then that must be also be treated ([See 7.1 Blepharitis on page 41](#))
  3. Doxycycline 50mg a day for 3 months, and a short course of mild topical steroid (e.g. Pred Mild qds) or FML BD are added for resistant cases
  4. If erosions continue then a bandage contact lens is usually the next step. These are lenses that are placed in the eye for a month at a time. The lens is not removed at night, and it creates a mechanical barrier between the lid and the cornea. Every month the lens is changed and lenses are worn for 6–12 months in total.
- If all other treatments fail then excimer laser photo-therapeutic keratectomy (PTK) is performed. The loose epithelium is mechanically removed and the excimer laser is used to remove around 5 microns of corneal tissue. This in effect “roughens” the surface of the cornea, and when the epithelium grows back over it tends to stick more firmly.
  - Alcohol application to the corneal surface following epithelial debridement is an alternative to PTK with similar results.

## Referral guidelines

- Refer suspected cases to be seen within 2 weeks.

## 8.9 Exposure Keratopathy

Exposure keratopathy is a failure of the lids' normal wetting mechanism, with consequent drying of the cornea, and damage to the epithelium. Causes are:

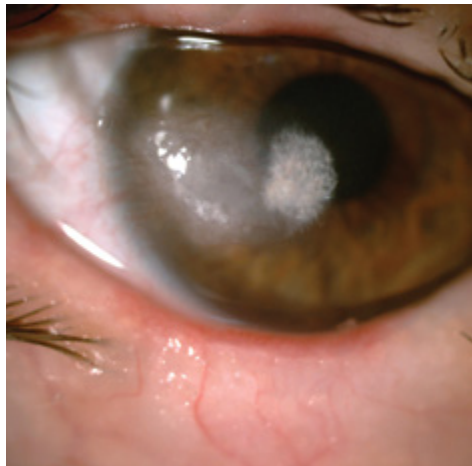
- Nocturnal lagophthalmos: incomplete closure of the lids at night. This is the commonest cause, and prevalent in a significant proportion of the population to varying degrees.
- Incomplete blink: another very common cause, and often overlooked.
- Lid abnormalities: ectropion, traumatic or surgical lid defects and scarring, floppy eyelid syndrome.
- Seventh nerve palsy: Bell's palsy, stroke, Ramsay-Hunt syndrome, tumours, surgery.
- Orbital disease: proptosis, thyroid eye disease.

### Symptoms

- Irritable, sore, dry, red eyes. May be worse in the morning if due to nocturnal lagophthalmos.

### Signs

- Epithelial disturbance of the cornea (looks dull) in the exposed area, usually inferior third/half of the cornea.
- In severe/neglected cases, especially if corneal sensation is reduced, corneal ulcers may form in the exposed area and secondary infection may occur.
- Check lid closure by getting the patient to close their eyes. Areas of incomplete closure may be immediately evident, although the patient may need to sit with closed eyes for many minutes before lagophthalmos becomes evident.



Central corneal scar and opacity associated with exposure keratopathy.

- Watch the patient carefully to assess the completeness of their natural blink – an important cause of exposure that is often overlooked as the patient can overcome it and achieve full closure when consciously trying. Check corneal sensation as reduced sensation is often a cause of reduced blink and unhealthy epithelium.

### Slit lamp signs

- Initially punctate epithelial change in the area of exposure (commonly the inferior third/half of the cornea). This progresses to thickened hazy epithelium.
- More severe cases may show epithelial breakdown or frank epithelial defects, and possibly corneal opacities or infiltrates in the case of secondary infection.

### Management

- Intensive lubrication is the mainstay of treatment, usually with ointment such as Lacrilube or Polyvisc at night, and an artificial tear drop frequently (at least every 2 hours or more) during the day (*See 7.2 Dry Eye on page 43*). It is advisable to use lubricants that do not contain benzalkonium chloride preservative.
- With severe corneal changes lid closure with either a temporary tarsorrhaphy or botulinum toxin ptosis is indicated.
- If there is little chance in improvement of lid function in the long term then more permanent surgical procedures are indicated such as permanent lateral tarsorrhaphy or central tarsorrhaphy, gold weights in the upper lid, or, in the case of thyroid eye disease, orbital decompression.
- If secondary microbial keratitis is suspected, the patient is treated with diagnostic corneal scrapes and intensive broad spectrum antibiotics (*See 8.1 Bacterial Keratitis on page 65*).

### Referral guidelines

- If suspected, refer within 48 hours.

## 8.10 Neurotrophic Keratitis

Corneal sensation is provided by the ophthalmic division of the trigeminal nerve.

- Reduction of corneal sensation results in:
- Loss of the normal feedback required to maintain a healthy epithelium.
- Predisposition to trauma and opportunistic infection.
- Impairment of epithelial repair.
- Delay in presentation.

The causes of corneal hyposthesia/anaesthesia:

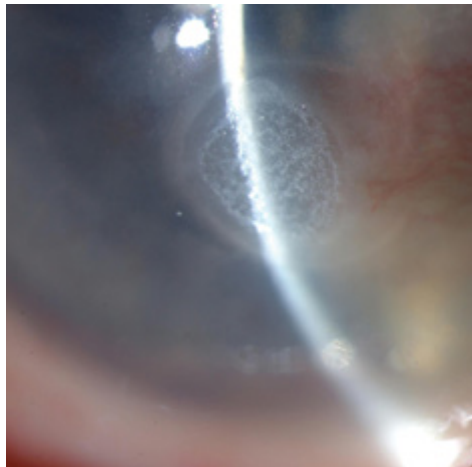
- Acquired (most common): herpes zoster virus, herpes simplex virus, surgical or traumatic division of the nerve, compression or infiltration of the nerve, diabetes.
- Congenital (rare): familial dysautonomia (Riley-Day syndrome).

Keratitis normally follows a pattern:

- Initial unhealthy/irregular epithelium.
- Development of epithelial breakdown and ulcer formation.
- Vascularisation of the cornea, and potential secondary infection.
- Perforation of the cornea in severe/prolonged cases.

### Symptoms

- Patients often present late as pain does not develop until advanced with inflammation or infection.
- Often the first symptom is reduced vision, although this won't be noticed by patients in whom the eye already has poor vision.
- Some patients notice redness of the eye as the first symptom.



Longstanding neurotrophic ulcer with associated neovascularisation. Also note white ciprofloxacin deposits in base of ulcer.

## Signs

- Epithelial irregularity (cornea looks dull).
- An ulcer that stains with fluorescein may be evident. This is typically oval-shaped and relatively central.
- The eye may be red.
- Corneal sensation will be absent – check this by applying the corner of a piece of tissue paper gently to the periphery of each cornea, and compare the patient's response in each eye. In acquired conditions reduced sensation is usually unilateral.

## Slit lamp signs

- Punctate epithelial change.
- Central/paracentral epithelial defect, classically with thickened, grey, rolled epithelial edges.
- Corneal vascularisation may be evident in more advanced cases.
- Sensation should be checked as above.
- Advanced cases may have accompanying corneal infiltrates (if secondary infection) or anterior chamber inflammation.

## Immediate management

- In the early stages when the epithelium is unhealthy but hasn't broken down then copious topical lubricating drops are used. Ideally these should not contain the preservative benzalkonium chloride ([See 7.2 Dry Eye on page 43](#)).
- If secondary bacterial infection is suspected then corneal scrapes are taken and empiric treatment with intensive broad spectrum antibiotic drops is commenced (e.g. Cefuroxime and Tobramycin hourly day and night).
- If the patient has known or suspected herpes simplex infection then topical Zovirax ointment 5 times a day is used.

## Long-term management

Ultimately, irrespective of the aetiology or the possibility of secondary infection, neurotrophic ulcers only heal when the lids are closed by either a temporary tarsorrhaphy, or by a botulinum toxin ptosis. In severe recurrent cases a permanent tarsorrhaphy may be considered.

## Referral guidelines

- If suspected, refer urgently within 24 hours.



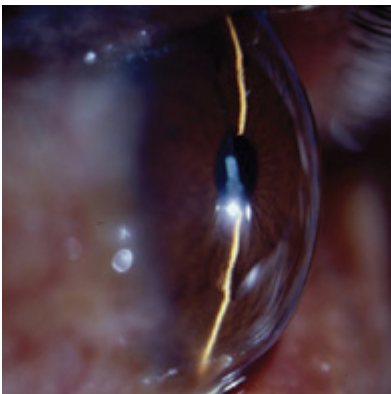
## 8.11 Corneal Ectasias

This is a group of conditions characterised by thinning and distortion of the cornea.


Keratoconus: (See 8.12 Keratoconus on page 87)

Pellucid marginal degeneration: a relatively rare progressive ectasia of the inferior peripheral cornea. It tends to present in mid-life with increasing astigmatism. At first this is correctable with glasses, but usually progresses to requiring contact lenses. As the condition progresses further it becomes increasingly difficult to tolerate contact lenses. Surgical options at that point are unpredictable. Penetrating keratoplasty or wedge excision may be considered, although the results can often be disappointing. If the patient has early cataract then often a better option is to do [Cataract Surgery](#) and implant a high-powered toric contact lens, which helps to overcome the astigmatism.

**Keratoglobus:** a very rare bilateral ectasia where the entire cornea thins. Management is difficult involving special contact lenses, or special corneal transplantation techniques.



Peripheral inferior steepening in pellucid marginal degeneration.



Computer generated image of a cornea with pellucid marginal degeneration. Note warmer colours inferiorly showing peripheral steepening.

## 8.12 Keratoconus

This is a relatively common disorder with progressive conical distortion of the cornea due to ectasia (thinning).

This results in increasing myopia (short-sightedness) and astigmatism. The aetiology is unclear although there is a tendency for keratoconus to run in families, and a definite link to eye rubbing has been established. It is believed to be more common in atopic patients. Presentation is usually in teens or early adulthood, during which time the condition may progress. Most cases are stable and non-progressive by the time the patients are in their mid-30s, although there are exceptions to this rule. The condition is usually bilateral but may be markedly asymmetric.

### Symptoms

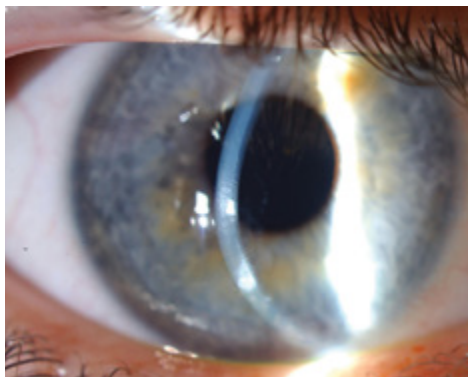
- Increasing blurring of visual acuity, often starting in teenage years. This becomes increasingly hard to correct with glasses.
- Severe cases may develop hydrops where Descemet's membrane splits and the cornea becomes very oedematous. This causes a rapid profound drop in vision, a visibly cloudy cornea, and variable discomfort.

### Signs

- Significant ectasia and cone shape may be visible to the naked eye.
- Central (or "apical") corneal scarring may be visible.
- Munson's sign can be present in moderate keratoconus. This is where, on downward gaze, the lower lid contour is distorted from its normal regular curved shape into a triangular shape.
- "Oil droplet" shadow in the red reflex on ophthalmoscopy.
- "Scissoring" of the reflex in retinoscopy may be seen – this is a test done to check a patient's refractive error, usually only by optometrists or ophthalmologists.

### Slit lamp signs

- Thinning and cone shape of cornea may be visible in moderate keratoconus.
- Central (or "apical") corneal scarring may be visible.



Distorted corneal light reflex in keratoconus. Note how the slit is curved in an oval shape, coming to a central 'peak'.

- Vogt's striae – vertical lines or wrinkles in the posterior corneal stroma, which disappear when pressing on the eyeball.

Ultimately the diagnosis (especially in early or mild cases) is made by corneal topography machines such as the Orbscan.

## Management

### **Mild keratoconus with good unaided vision:**

- Monitoring by ophthalmologist or optometrist.

### **Mild to moderate keratoconus with reduced unaided vision:**

- Glasses help some cases, but most patients need contact lenses. These may be soft "toric" contact lenses (CLs) that correct astigmatism, but more usually patients require hard contact lenses (or RGPs – rigid gas permeable lenses). Sometimes hard and soft lenses may be worn simultaneously (piggyback lenses) and sometimes special lenses such as semiscleral lenses are required.

### **Mild to moderate keratoconus in patients who are contact lens intolerant:**

- Intrastromal corneal rings (plastic semicircle segments inserted into the tissue of the cornea) may be used to improve the shape of the cornea, to improve contact lens tolerance, or to make glasses an alternative option to contact lenses. These include Intacs and Kerarings.

### **Moderate to severe keratoconus in patients in whom contact lenses don't improve vision, or who are CLs intolerant:**

- Corneal transplantation, either full thickness, or partial thickness (lamellar, or deep anterior lamellar keratoplasty – DALK) (*See 8.16 Corneal Transplants (Grafts) on page 96*).

A new treatment called corneal collagen cross-linking is now available. This treatment involves the creation of cross-links between individual corneal fibres in order to stabilise the condition and prevent progression. It is therefore advisable to regularly monitor patients with topography up to age of around 30, and if progression is noted, treatment is advisable. This monitoring can be done by either the ophthalmologist or optometrist.

## Referral guidelines

- All newly diagnosed keratoconic patients should be referred to an ophthalmologist non-urgently for counselling and assessment of the need for collagen cross-linking.
- Patients suffering acute loss of vision or a painful red eye (especially if a contact lens wearer) should be referred urgently within 24 hours.
- All patients with an existing corneal transplant who develop any new symptoms of reduced vision, redness or discomfort should be referred urgently within 24 hours to exclude graft rejection.

## 8.13 Corneal Dystrophies

Corneal dystrophies are a diverse group of inherited disorders affecting the anterior, stromal or posterior layers of the cornea.

Symptoms range from recurrent corneal erosions (4-8) to progressive clouding of the cornea and loss of vision that may require transplantation (4-19).

### Anterior Dystrophies

#### Epithelial Basement Membrane Dystrophy also called Map-Dot-Fingerprint Dystrophy or Cogan's Dystrophy

- The most common dystrophy affecting 5% of the population.
- Usually presents in early adulthood/midlife.
- Due to abnormal attachment of the epithelium to the underlying Bowman's membrane
- The epithelium shows map shapes, dots (microcysts in the epithelium) and fingerprint shapes.
- The dystrophy itself is asymptomatic but predisposes the patient to developing corneal erosion syndrome ([See 8.8 Recurrent Erosion Syndrome on page 80](#)).

#### Reis-Buckler Dystrophy

- Autosomal dominant dystrophy with progressive degeneration of Bowman's layer and subepithelial collagen deposition.
- Presents with recurrent corneal erosions in early life, with increasing central opacity resulting in reduction of vision later.

#### Meesman's Dystrophy

- Rare, autosomal dominant dystrophy, presents in adulthood.
- Characterised by epithelial vesicles, starting centrally and spreading peripherally.

## Stromal Dystrophies

### Lattice Dystrophy

- Rare, autosomal dominant dystrophy with progressive deposition of amyloid in the stroma.

### Granular dystrophy

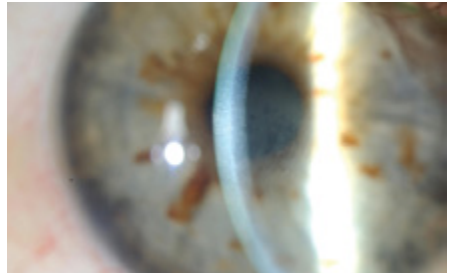
- Rare, autosomal dominant dystrophy presenting in adulthood with deposition of hyaline material in the stroma.

### Avellino dystrophy

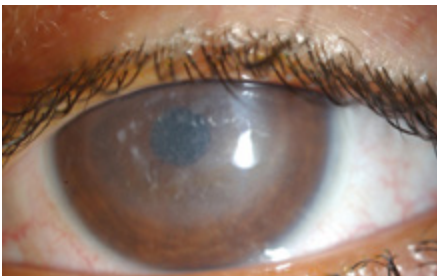- Very rare, autosomal dominant dystrophy with bilateral granular type opacities in the anterior stroma and lattice-like lines in the deeper stroma.

### Macular dystrophy

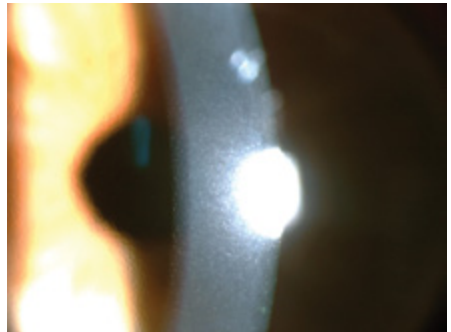
- Rare, autosomal recessive dystrophy with deposition of glycosaminoglycan in the stroma and loss of corneal translucency from early adulthood.



Thickened hazy cornea in Fuch's Dystrophy.



Corneal macular dystrophy with central hazy cornea.



Guttata (small excrescences) on the posterior surface of the cornea in Fuchs Dystrophy.

## Posterior Dystrophies

### Fuch's endothelial dystrophy

- Common with increasing age.
- Primary endothelial dysfunction results in progressive corneal oedema.
- In early stages corneal guttata are seen (small dots seen on the endothelium with the slit lamp). In later stages the cornea becomes increasingly thickened and cloudy, and eventually bullae (small blisters) develop on the surface.
- Early symptoms are reduced vision, sometimes worse in the morning. As the condition progresses the vision deteriorates, and in later stages pain is experienced when bullae develop.
- In early stages no treatment is required. Patients may find that blowing air (from a hairdryer with a cool setting) on the cornea can help to improve the vision (by reducing corneal oedema). Topical hypertonic agents (5% NaCl) occasionally may also help. In later stages corneal transplantation is indicated, traditionally full thickness keratoplasty, but more recently endothelial transplantation has become the standard approach (*See 8.16 Corneal Transplants (Grafts) on page 96*).

### Congenital hereditary endothelial dystrophy (CHED)

- A usually autosomal recessive condition that causes bilateral corneal oedema in neonates, with severely reduced vision, amblyopia and nystagmus.

### Posterior polymorphous dystrophy

- An autosomal dominant condition with variable expression. Appearance of the cornea is variable but often clusters or lines or vesicles are seen on the endothelium.

## 8.14 Deposition Keratopathies

### Vortex keratopathy

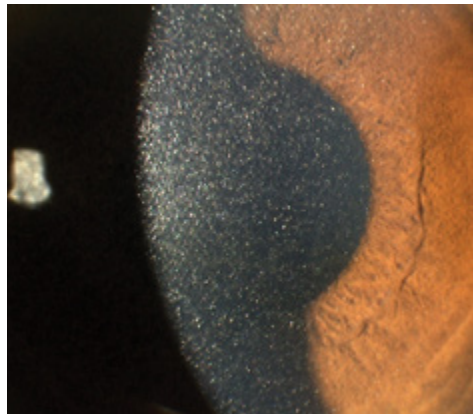- Deposits in the corneal epithelium caused by certain drugs. Also seen in Fabry's disease.
- Causative drugs include amiodarone (most common), chloroquine, indomethacin, tamoxifen, chlorpromazine.
- Patient is usually asymptomatic. Very rarely, if severe deposits, the vision may be slightly reduced.
- On examination with the slit lamp brown/grey lines are seen to radiate out from a point in the lower central cornea.
- Cessation of the causative drug leads to resolution of the deposits, although this is not usually required as the condition is usually asymptomatic.

### Wilson's Disease (Hepatolenticular degeneration)

- Rare autosomal recessive condition with a deficiency in a copper binding protein leading to low levels of ceruloplasmin and copper deposition throughout the tissues.
- The patient does not usually have any ocular symptoms.
- A brownish ring is seen deep in the peripheral cornea at the level of Descemet's. The presence of this ring is often an aid to the diagnosis of Wilson's disease.

### Crystalline keratopathies

- Infectious crystalline keratopathy presents with feathery stromal opacities with no significant inflammation. It is usually due to *Streptococcus viridans*, and also occasionally due to *Staphylococcus epidermidis*, *Pseudomonas aeruginosa*, or *Candida* sp.
- Non-infectious crystalline keratopathy includes:
  - lipids in lipid keratopathy.
  - immunoglobulins in multiple myeloma, Waldenstrom's macroglobulinaemia, lymphoma.
  - urate in gout.
  - cysteine in cystinosis.
  - deposition of gold (in systemic treatment in rheumatoid arthritis).



Refractile deposits in the cornea in cystinosis keratopathy.

## 8.15 Contact Lenses

Contact lenses are mainly worn to correct refractive errors, but they are also worn for cosmetic purposes (coloured lenses) and therapeutic purposes (bandage contact lenses).

There are several different materials that lenses are made from, but the ideal lens transmits oxygen well.

### Contact lens types

#### Hard lenses

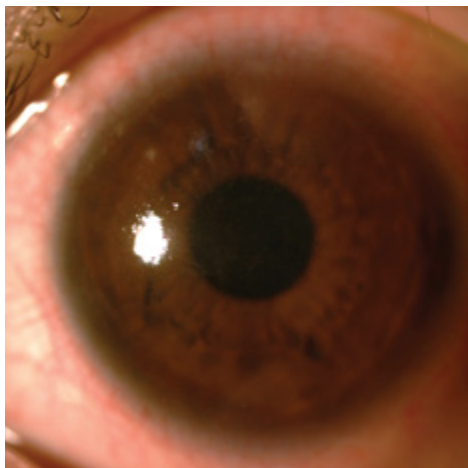
- Originally made of glass, and subsequently of PMMA.
- Excellent optical properties but transmit oxygen poorly.
- No longer used.

#### Rigid gas permeable (RGP) lenses

- Rigid in nature, made of complex polymers (silicone, PMMA, others).
- Good transmission of oxygen, but can be uncomfortable to wear.
- Because of their rigidity the space between the lens and the cornea becomes filled with tears (the “lacrimal lens”), which neutralises corneal astigmatism and surface irregularities and hence they are the lens of choice for patients with keratoconus ([See 8.12 Keratoconus on page 87](#)) and corneal scars.
- Special lenses such as “semi-scleral lenses” are made of RGP materials, but are larger than normal RGPs and are for conditions such as advanced keratoconus.

#### Hydrogel lenses

- Made of polymers of hydroxethyl methacrylate, and are soft in nature making them much more comfortable to wear than RGP lenses.
- These are the most common type of contact lens for correcting refractive error, and also for cosmetic lenses. Commonly they are of the monthly disposable variety (removed each night for cleaning and sleeping, and discarded after one month) or



Markedly injected conjunctiva in contact lens intolerance.



the daily disposable variety (removed each night and discarded, with a fresh lens the next day).

- Because of their soft nature they are not so useful for keratoconus or corneal irregularities. Astigmatism may require special “toric” lenses.

### **Silicone hydrogel lenses**

- These have the advantages of hydrogel lenses, but are more permeable to oxygen. It is possible to wear them therefore overnight. “Extended wear” contact lenses are silicone hydrogel lenses that are worn day and night and replaced each month. When worn as extended wear there is a significantly higher risk of infective keratitis.

### **Complications of contact lens wear**

Any symptoms of discomfort or red eye in a contact lens wearer indicate microbial keratitis until proven otherwise.

#### **Microbial keratitis**

- Symptoms include pain, redness, and sometimes reduced vision.
- Usually there is a white infiltrate in the cornea, often with an overlying epithelial defect that stains with fluorescein.
- Contact lens wearers are particularly at risk of infection with *psuedomonas* (which can be very aggressive) or *acanthamoeba* (which can be difficult to diagnose and have a poor prognosis if not diagnosed correctly; see 4-4).
- Because of the poor prognosis if not treated early, most contact lens wearers with symptoms of redness, pain, and the presence of any corneal infiltrate or opacity are treated as infective until proven otherwise. For management see 4-1.

#### **Sterile keratitis**

- Symptoms include pain, redness, and sometimes reduced vision.
- Usually there are multiple small hazy opacities or infiltrates, and these usually do not stain with fluorescein.
- Despite the sterile nature these patients are often treated as infective keratitis due to the poor prognosis if infection is missed and the fact that the two conditions are often difficult to differentiate.
- If the diagnosis of sterile keratitis is clear then the condition usually resolves with a holiday from contact lens wear, possibly a change in the type of contact lens

or cleaning solution used, and management of any concurrent blepharitis (See [7.1 Blepharitis on page 41](#)).

### **Giant papillary conjunctivitis**

- A reaction to contact lenses (usually RGP lenses) that results in the formation of giant papillae on the tarsal (underside) of the upper lids. These appear as large red “cobblestone” lumps, and cause itching and mucus discharge.
- Treatment in mild cases is with mast cell stabiliser drops (e.g. sodium cromoglycate qds) or with combined antihistamine/mast cell stabiliser drops (e.g. patanol bd), but in more severe cases may require cessation of contact lens wear.

### **Referral guidelines**

- Contact lens infective keratitis is an ophthalmic emergency.
- Any contact lens wearer who presents with pain or redness of the eye should be referred urgently for assessment to an ophthalmologist (within 6 hours).

## 8.16 Corneal Transplants (*Grafts*)

Grafts are more commonly performed electively to replace scarred or distorted corneas to improve vision, but they are also performed as an emergency to replace corneas with perforations (tearful grafts).

- The commonest and most successful of all transplantation procedures.

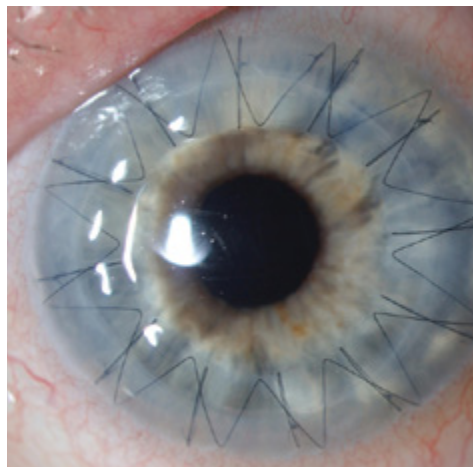
### Types of corneal transplant

#### Penetrating keratoplasty

- This is where the full thickness of the cornea is replaced, usually the central 7–9mm.
- Until recently this was the most common type of graft, although newer partial thickness (lamellar) grafting techniques have superseded it for many conditions. It remains the graft of choice for full-thickness trauma and scars of the cornea, for corneal perforations, and for advanced keratoconus.
- In general excellent results are achieved, with good prognosis for long-term visual recovery. The main disadvantages compared to lamellar graft techniques are longer recovery period, higher levels of astigmatism (which may need further surgery) and a 25% chance of rejection. The ultimate final best corrected vision, however, may be better than with a lamellar graft.
- Poor prognostic factors include pre-existing corneal vascularisation, reduced corneal sensation, active inflammation, herpetic disease, ocular surface disease and uncontrolled glaucoma.

#### Deep anterior lamellar keratoplasty (DALK)

- This is a partial-thickness graft used for conditions where the patient's own endothelium/Descemet's layer is healthy. Only the stroma and epithelium are replaced.
- Keratoconus is the most common indication, but stromal dystrophies and anterior corneal scars are also suitable. It is not possible in advanced cases of keratoconus where Descemet's has already been damaged.
- The main benefit over a penetrating keratoplasty is a



Corneal graft (penetrating keratoplasty) with sutures.

much lower risk of rejection (5% rather than 25%), and also slightly increased structural integrity of the eye.

### Superficial lamellar keratoplasty

- This is a partial thickness graft where only the anterior stroma is replaced.
- It is used for superficial scars, and has the same benefits as a DALK.

### Endothelial keratoplasty

- Also known as Descemet's stripping endothelial keratoplasty (DSEK).
- This is where only the endothelium and Descemet's layer are replaced, and is used in conditions where the endothelium has failed but the corneal stroma is normal. The most common conditions are Fuch's endothelial dystrophy, and pseudophakic bullous keratopathy (endothelial failure after [Cataract Surgery](#)).
- The main benefit is much more rapid recovery and no problems with astigmatism (as the majority of the cornea is not affected). The rejection rate, however, is the same as with a penetrating keratoplasty, and the long-term survival rate of the graft may be poorer. The patient may also need early reoperation to reposition the graft.

### Triple procedure

- This is where [Cataract Surgery](#) and intraocular lens implantation are carried out at the same time as a graft procedure.

## Management of a patient with a corneal transplant

### Early management

- Patients are treated with intensive topical steroid drops (e.g. Pred Forte drops hourly) and topical antibiotics (e.g. chloramphenicol drops qds).
- The main risk of serious infection (endophthalmitis) is greatest in the first week, but infection still remains a risk for as long as sutures are in the eye (up to 18 months).
- The risk of rejection is low in the first 2–4 weeks.

### Long-term management

- Antibiotic drops are usually discontinued after roughly a month, but topical steroid drops are reduced slowly over time, and may be used for 6–12 months (and in some patients long term). There is no requirement for systemic immunosuppression, except in the case of graft rejection.
- Most sutures are removed after 15–18 months, but loose sutures or overly tight sutures (causing astigmatism) may be removed anytime from a month post-op.
- Most patients will have multiple post-op visits in the first 18 months, with repeated topography and refractive assessments.

## Complications

### Rejection

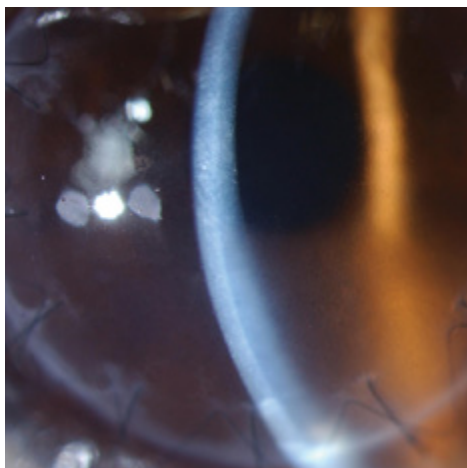
- The commonest cause of graft failure. Usually the endothelium is rejected but the stroma and epithelium can also be rejected. If treated early full recovery can be expected, but even a short delay in diagnosis and treatment can lead to irreversible graft failure.
- Symptoms are variable (and often mild) but include reduced vision, redness, and pain. All graft patients are advised to seek immediate help if they suffer any of these symptoms.
- On examination usually an area of corneal oedema (cloudiness) can be seen, often with a line of keratic precipitates on the endothelium (Khodadoust line), but sometimes in early cases only a few anterior chamber cells may be seen.
- Because of the poor prognosis if the diagnosis is not made early, any graft patient presenting with these symptoms is treated as rejection until proven otherwise. Treatment is with IV methylprednisolone, and intensive topical steroid (Pred Forte).

### Suture problems

- Loose sutures can lead to corneal infection and abscesses, which in turn can provoke graft rejection. All patients with irritation in the eye should have their sutures assessed and loose ones removed. If infection is already present it is treated as bacterial keratitis ([See 8.1 Bacterial Keratitis on page 65](#)).

### Referral guidelines

Any patient with a corneal transplant who presents with symptoms of redness, irritation, pain or reduced vision should be referred urgently to an ophthalmologist (within 12 hours).



Inferior thickening and haze in corneal graft rejection.

# Macular Degeneration

## State of the art early diagnosis of Macular Degeneration

Auckland Eye provides state of the art care and early detection services to help preserve your vision and maintain your quality of life. Don't let Age related Macular Degeneration (AMD) hold you back from enjoying the moments that matter.

Our experienced ophthalmologists offer thorough evaluations to diagnose and catch issues early.

These could be signs of AMD, a condition that can significantly affect your daily life.



Difficulty recognising  
familiar faces?



Noticing wavy  
straight lines?



Seeing dark spots in the  
centre of your vision?

Take action today! If you're noticing any of these symptoms, it's time to prioritise your vision.

**Safeguard your sight for a brighter tomorrow!**

Q [aucklandeye.co.nz](https://aucklandeye.co.nz)  
e. [admin@aucklandeye.co.nz](mailto:admin@aucklandeye.co.nz)  
p. 0800 25 53 93



**AUCKLANDEYE**  
Life Changing Eye Care



## 9 *Sclera*

## 9.1 Episcleritis

A benign inflammation of the episclera (the vascular layer between the conjunctiva and the sclera). Seen most commonly in young adults (females more than males) and usually self limiting, although it may be recurrent. It is usually idiopathic but may occasionally be associated with systemic diseases similar to those associated with scleritis.

### Symptoms

- Area of redness on white of eye.
- Mild to moderate discomfort but may be painless.
- No significant itch, discharge or photophobia.

### Signs

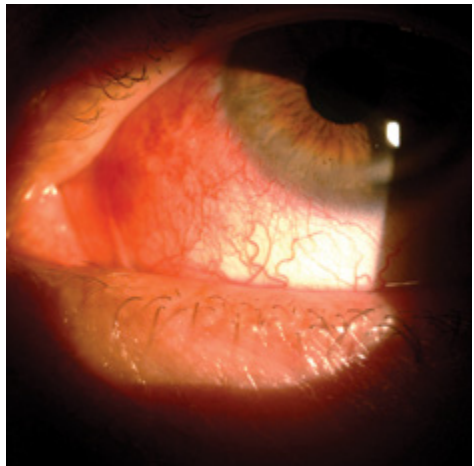
- Redness of the bulbar conjunctiva – this may be diffuse or sectorial, or may be in the form of a localised nodule of thickened inflamed episclera. There is no conjunctival discharge or lid swelling.
- Normal visual acuity.

### Slit lamp signs:

- Episcleral and overlying conjunctival vessels will be inflamed.
- Differentiating between episcleritis and scleritis may be difficult, but scleritis generally has a more violaceous hue, along with scleral swelling and thickening.
- To assist in differentiation, phenylephrine 2.5% drops may be used. Phenylephrine will blanch episcleral vessels but not scleral vessels.

### Immediate management:

- Most cases will resolve in 2–3 weeks without treatment, although it may last 2–3 months in some cases.
- Topical artificial tear drops may give comfort, and non-steroidal anti-inflammatory drops



Marked sectorial injection of the conjunctiva and deeper tissues in episcleritis.



(Diclofenac Sodium 0.1% bd to qds, or Ketorolac 0.4% bd to qds) may help speed resolution.

### Long-term management:

- If moderate to severe symptoms, consider scleritis and investigate for systemic disease: connective tissue disease, inflammatory bowel disease, gout, herpes zoster.
- Oral NSAIDs or topical weak corticosteroids may be useful.

### Referral guidelines:

- Refer if not responding to simple treatment or if diagnosis is uncertain.
- Refer if considering topical steroid therapy.
- Consider other differential diagnoses including anterior uveitis, severe pain and tenderness suggests scleritis.

## 9.2 Anterior Scleritis

- Inflammation of the sclera anterior to the equator of the globe.
- May be associated with posterior scleritis.
- Exists in various forms: diffuse, nodular, destructive with inflammation, and apparently non- inflamed scleromalacia perforans.
- 50% are associated with systemic disease, especially connective tissue disorders.

### Symptoms

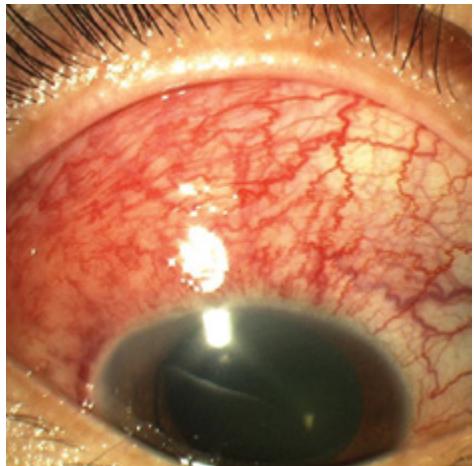- Pain, which may be severe, is the usual presenting complaint.
- Redness of the eye.
- Blurred vision.

### Signs

- Bulbar redness.
- Dark areas of uvea visible through the sclera in some cases.

### Slit lamp signs

- Bulbar injection with a violaceous hue. Scleral swelling beneath conjunctiva and episclera.
- Phenylephrine 2.5% drops may be used to blanch the more superficial episcleral and conjunctival vessels. If eye remains red then it suggests a diagnosis of scleritis.
- Peripheral corneal melt if associated keratitis.
- Scleromalacia: dark ciliary body pigment visible through thinned sclera.
- Leak of aqueous if perforated: hypotonous eye with flat anterior chamber.
- Uveitis.



Extensive injection of all levels of vessels in diffuse anterior scleritis.

### **Immediate management**

- Referral for ocular examination including B-scan ultrasonography, and investigation for systemic disorders.

### **Long-term management**

- Systemic anti-inflammatory therapy: oral non-steroidal anti inflammatory drugs, oral prednisone, other immunosuppression.
- Specific management of associated systemic disorder if any.

### **Referral guidelines**

- Referral mandatory: semi-urgent or if associated melt or perforation then urgent referral.

## 9.3 Posterior Scleritis

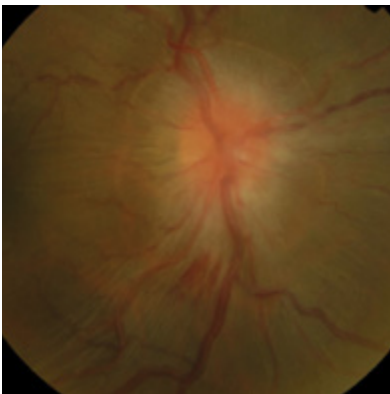
- Inflammation of the sclera posterior to the equator of the globe which may be severe and destructive.
- It may be associated with anterior scleritis (where it is commonly associated with connective tissue disorders) or may exist alone (where it is less commonly associated with systemic disease – the most common associations being ankylosing spondylitis and herpes zoster).
- Both forms may cause uveitis, exudative retinal detachments, choroidal folds, swelling of the disc, and inflammation outside the globe.

### Symptoms

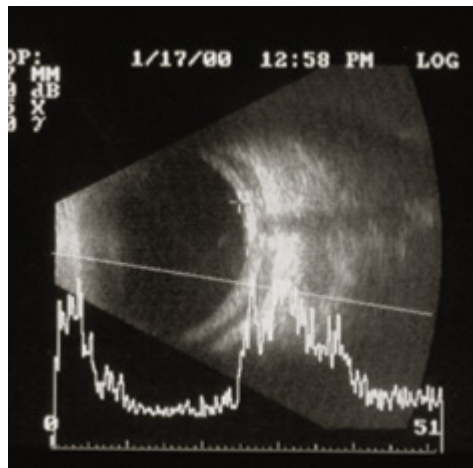
- Pain, which may be severe, is the usual presenting complaint.
- Blurred vision may result from involvement of the inner coats of the eye, particularly uveitis.
- Diplopia may result from contiguous inflammation of eye muscles.

### Signs

- May be no external signs.
- Vision may be reduced.
- Redness in some case.
- Occasionally proptosis secondary to adjacent orbital inflammation.
- Ptosis may be present.



Optic nerve swelling in posterior scleritis.



Ultrasound scan (B-scan) of an eye with posterior scleritis showing thickened sclera and fluid behind the sclera (so-called 'T-sign').

### Slit lamp signs

- Some have associated anterior scleritis with redness and tenderness.
- Intraocular examination may show uveitis, exudative retinal detachment, disc swelling.

### Immediate management

- Pain relief.
- Referral for ocular examination including B-scan ultrasonography, and investigation for systemic disorders.
- Oral steroids 1mg/kg with slow taper. In very mild cases, NSAIDs may be sufficient to treat scleritis.

### Long-term management

- Slow taper of steroids. Approximately one-third of patients develop a chronic disease course, and may require disease-modifying agents (e.g. Methotrexate or Azathioprine) to control scleritis. Specific management of associated systemic disorder if any.

### Referral guidelines

- Referral mandatory. Semi-urgent.

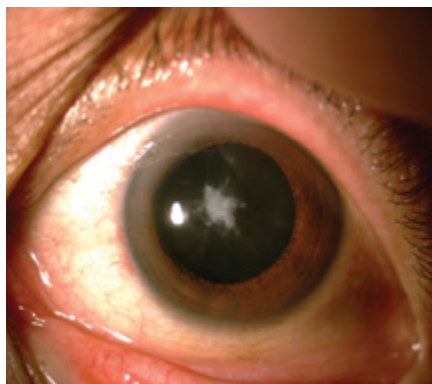


## 10 *Cataract*

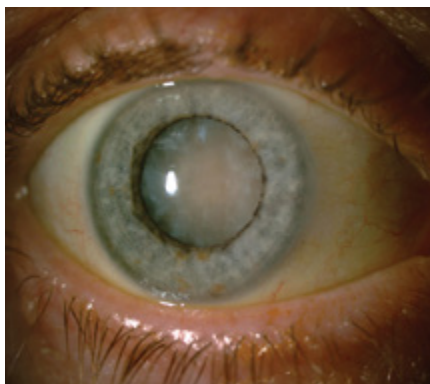## 10.1 Cataract types

A cataract is an opacity in the crystalline lens of the eye. Even though minor opacities can be seen on optometric/ophthalmological examination when young (age 30 onwards), symptoms of a cataract are not usually noticed until 60–70 years of age.

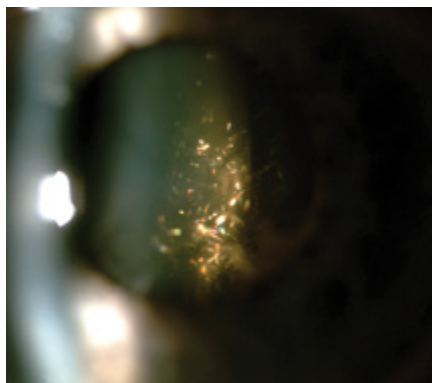
Some people may experience symptoms of decreasing vision due to cataract much earlier as a result of a familial tendency, myopia, trauma, metabolic causes (especially diabetes), or inflammation.



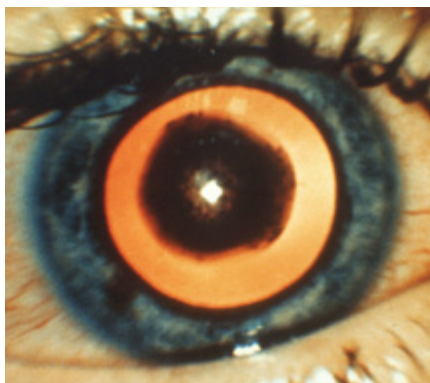
Anterior cataract seen as a central white opacity in the lens.



Dense nuclear sclerosis causing cataract



Christmas tree cataract with colourful refractile opacities in the lens.



Loss of red reflex with a nuclear cataract.

## Types

- **Congenital Cataract:** if this is significant at birth it must be removed promptly in order to allow for visual development, otherwise dense amblyopia occurs ([See 19.1 Amblyopia on page 270](#)).
- **Nuclear Sclerosis (NS):** this is a progressive hardening and brunescence of the central lens structure. Initially, this often causes improved reading vision (also known as second sight) along with a reduction in distance vision. Glasses may initially improve vision but the improvement in vision achieved lessens over time.
- **Cortical Cataract:** this may be quite advanced before it affects visual acuity, but can be a significant cause of disabling glare for some people.
- **Posterior Subcapsular Cataract:** this is more common in metabolic or inflammatory disease, and may also be a cause of glare.

## Symptoms

- Gradual reduction of visual acuity (VA) – this is the most common way of quantifying the impact on vision.
- Reduced contrast acuity – this causes reduced vision in low light/foggy/misty conditions.
- Reduced colour vision – nuclear cataract will reduce the ability to perceive violet-blue colours.
- Increased glare – often to levels causing visual impairment, especially in sunlight or car headlights.

## Clinical signs

- Reduced red reflex or shadows in the red reflex.

## Long-term management

Once glasses can no longer provide functional vision (or vision required for an individual's daily visual demands), the only way to improve vision is by surgical removal of the cataract and replacement with an intraocular lens.

## Referral guidelines

Patients should be referred for an opinion on the pros and cons of [Cataract Surgery](#) when glasses/contact lenses no longer provide adequate vision, or when other visual symptoms, such as disabling glare arise.

### Cataract surgery may be considered in any patient with:

1. Decreased vision that can't be improved with glasses.
2. Frequent updates of glasses prescription in patients over 50.
3. Vision less than legal driving standard (6/12) in patients who wish to drive.
4. Increasing intolerable glare.
5. Worsening reading vision exacerbated by bright light.



## 10.2 Cataract Surgery

This involves the surgical removal of the opacified lens and in most cases, the replacement with an intraocular lens (IOL).

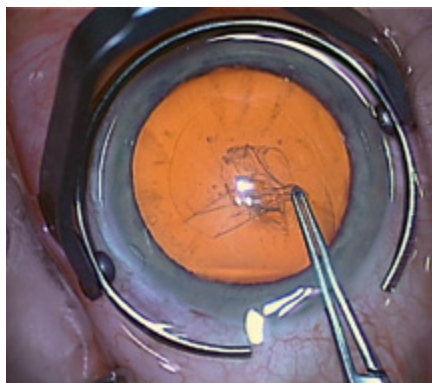
### Indications

- Reduced visual acuity, glare symptoms, monocular diplopia, reduced contrast sensitivity that is related to an increase in cloudiness of the lens.
- Lens-induced glaucoma (phacomorphic glaucoma – angle closure due to a large lens).
- An opacified lens that prevents the adequate screening of retinal or optic nerve diseases.

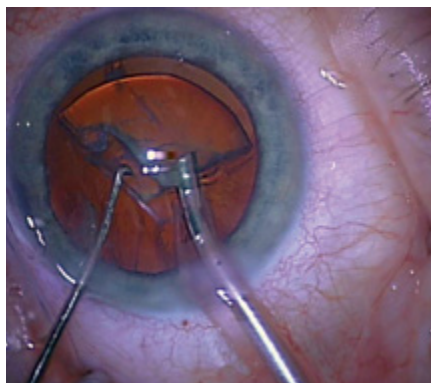
### Surgical techniques

This is a rapidly developing field with new techniques and instrumentation becoming available. Surgery is generally performed under local anaesthesia, such as, subtenons regional blocks and topical anaesthesia.

1. **Phacoemulsification:** Currently this is the most common surgical technique performed. It typically involves a 1.8–2.6mm corneal incision at the limbus, the creation of an opening in the anterior lens capsule (capsulorhexis), and the introduction of an ultrasound probe that emulsifies and aspirates the lens material. The IOL that has been matched and chosen for the patient's needs is then injected through the corneal wound into the capsular bag. The corneal wound is usually self-sealing and sutures are not usually necessary. This surgery usually takes 15–30 minutes to do, and visual acuity is frequently excellent on the first post-operative day.



Continuous curvilinear capsulorhexis forming an opening through the anterior capsule of the lens.



Removing a lens fragment with phacoemulsification.

2. **Femtosecond Laser Cataract Surgery:** This is the most recently introduced technique of surgery that combines the use of the femtosecond laser ([See 20.5 Laser In-Situ Keratomileusis \(LASIK\) on page 314](#)) and phacoemulsification. The femtosecond laser is used to create precise and more secure corneal wounds and to create a precisely sized and positioned capsulorrhexis. The laser is also then used to fragment the lens nucleus before phacoemulsification. This technique gives a greater likelihood of achieving the targeted refractive outcome.
3. **Extracapsular Cataract Extraction:** This technique is less commonly performed now, having been largely superseded by phacoemulsification. It is effective for those patients with very hard cataracts that may be too hard to be removed by phacoemulsification and aspiration. It involves creating a 10–12mm scleral wound that requires suturing, close followup and a longer recovery period. Not uncommonly this technique is still used in some Pacific Islands and developing countries.
4. **Refractive Lens Exchange:** This operation resembles [Cataract Surgery](#). The objective is to relieve some patients who do not have cataract of dependence on glasses and contact lenses when other treatments are not suitable.

## Postoperative Course

Two post-operative visits are usually necessary, the first within the first to third post-operative days, and the second at 3–6 weeks.

Patients are treated with a combination of topical steroid eye drops (e.g. Pred Forte tds), topical antibiotics (e.g. Chloramphenicol tds) and a topical non-steroidal anti-inflammatory (e.g. Voltaren tds). The latter has been found to reduce the risk of post-operative cystoid macular oedema. The treatment is typically continued for a four-week period.

## Possible complications

The risk of a severe complication such as endophthalmitis, choroidal haemorrhage, or retinal detachment is approximately 1:1000. The success rate with modern phacoemulsification surgery is about 98%.

### Intraoperative complications:

- **Posterior capsular rupture:** this is where the capsule of the lens is broken during surgery, allowing vitreous from behind the lens to enter into the anterior chamber.
- **Zonular dehiscence:** here the suspensory ligament of the crystalline lens is weak and makes surgery difficult as well as making secure positioning of the IOL difficult.
- **Dropped nucleus:** this is when pieces of the lens nucleus drop through to the posterior part of the eye, either through a hole in the capsule, or through an area of zonular dehiscence.

### Post-operative complications

- **Cystoid Macular Oedema (CMO)** (*See 13.19 Cystoid Macular Oedema on page 195*). This is the commonest complication seen, occurring in 1–5% of patients.
- **Endophthalmitis:** this rare complication (1:1000) of post-op infection inside the eye can be devastating with loss of vision or even the eyeball.
- **Persistent post-operative uveitis:** routinely topical steroids are used post-operatively for 2–4 weeks but occasionally inflammation may recur on cessation of these drops.

### Long-term outcomes

Once a patient has arrived at a satisfactory result after *Cataract Surgery*, the outcome should last forever, assuming no other ocular pathology. A common treatable cause of decreased vision occurring usually within the first 2 years after surgery is posterior capsular opacity and this is easily and painlessly treatable with YAG laser capsulotomy.

### Post-operative referral guidelines

- A patient with pain and reduced vision in the post-operative period should be referred urgently.
- A patient with painless reduced vision after the first few weeks post-op should be referred semi-urgently (within 3 days).

## 10.3 Intraocular Lenses (IOLs)

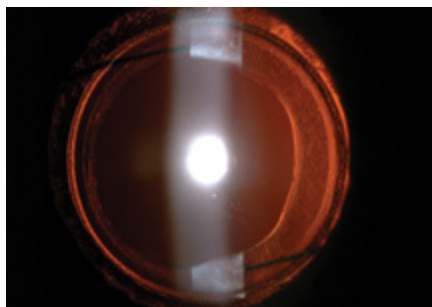
Intraocular lenses are placed in the eye to replace the natural lens at the time of lens replacement surgery (*Cataract Surgery*).

They come in many different strengths or powers, and the strength of lens required for an individual patient is determined based on measurements of the corneal curvature and the axial length (length of the eye). The collective term for these measurements is biometry. They can also correct astigmatism as of c. 2005 and are generally offered to patients with over 0.75D of astigmatism. There has been an explosion of IOL designs now able to extend range of visual focus thereby reducing the need for patients to wear glasses for near tasks such as computers and books. The terminology of these IOLs is evolving.

### IOL Types

#### Standard monofocal IOLs

- These are usually made of acrylic or silicone, and can be rolled or folded to allow insertion through very small 2–3mm wound, despite the fact that when in place they are 5–6mm in diameter. The “optic” is the central focusing part of the IOL, and the “haptics” are little legs that extend from the optic to hold the lens in position. They can provide extremely high quality vision if the correct strength of IOL is selected. In even the very best ophthalmic units in the world 20% of patients will have a significant focusing error requiring correction with spectacles to achieve optimal focus and clarity.



Monofocal IOL sitting in capsular bag.



Multifocal IOL showing diffraction rings.

- Monofocal lenses, as the name implies, have only one focus distance, and a decision must be made by the patient whether they would prefer good unaided distance vision and need glasses for reading, or whether they would prefer good unaided reading vision and need glasses for distance. Some patients may choose to have a distance lens in one eye, and a reading lens in the other eye – this is called monovision. For many patients this may give overall good vision from near to distance (and hence independence from spectacles), the brain automatically preferentially concentrating on the eye with the best vision for any particular distance. Patients who are myopic (short-sighted) prior to surgery often tolerate monovision well.
- Monofocal IOL implantation for both eyes will almost always mean a pair of glasses will be necessary for reading tasks. This pair of glasses may not be suitable for other near tasks such as embroidery (very close) or computer work (further away). There are other glasses options that may be suitable but as one does not look down for computer work, progressive or bifocal glasses may not provide a satisfactory option for patients post lens replacement. All types of bifocals may also put patients at potential risk for falls as when looking down to judge steps and contours there may be distortions resulting in misjudgement of footfall. As IOL designs to extend the functional range of vision have improved, the traditional advice encouraging the use of monofocal IOL's must be carefully considered.

### Toric IOLs

- These are similar to monofocal IOLs in that they only have one focus distance, but they also incorporate correction for astigmatism. 20% of all patients undergoing cataract surgery have sufficient astigmatism in their cornea to benefit from a toric IOL.
- A Toric IOL will only correct the vision at one plane – distance, intermediate or near. The benefits of a toric IOL must therefore be considered in the context of advice on monofocal IOL's as above.

## Presbyopia correcting IOLs

- This area of IOL technology has exploded in the last decade. In 2010, the percentage of these IOL's being implanted was less than 1%. It is currently 10% and predicted to be 20% by 2020. Why has this growth occurred? Partly because of better IOL technology, but also the increasing demands of our patients on near and intermediate tasks in their daily lives.
- The biggest development has been in the area of EDOF IOL's. These are different to traditional/diffractive multifocals and there is currently a great degree of confusion amongst patients, optometrists and ophthalmologists alike. These IOL's have changed the patient experience of lens replacement surgery and upwards of 80% can look forward to much reduced dependency on glasses for daily visual tasks.
- The use of newer presbyopia correcting IOL's requires patient and surgeon to be completely frank about the benefits of choosing a premium (more expensive) IOL. In all cases, it is necessary for a surgeon to be able to provide adequate post IOL surgery care which most commonly takes the form of laser vision correction. This may be necessary in up to 8% of patients to attain optimal visual outcomes. Any patient seeking advice on a presbyopia correcting IOL should be clear about the post surgery costs and service that may be required to optimise their visual outcome.
- All presbyopia correcting IOLs have subtle nuances regarding visual function and may not restore the quality of vision experienced by most people in their earlier years. They do, however, now offer a good chance of spectacle independence after [Cataract Surgery](#). Potential drawbacks with these lenses include night vision disturbances, and limited near vision. Patients who are hyperopic (long-sighted) prior to surgery often tolerate presbyopia correcting IOLs, but newer technologies make this option more suitable for all motivated patients.



## 11 *Glaucoma*

## 11.1 Primary Open Angle Glaucoma

Glaucoma is an optic neuropathy that has classical visual field and optic nerve head thinning.

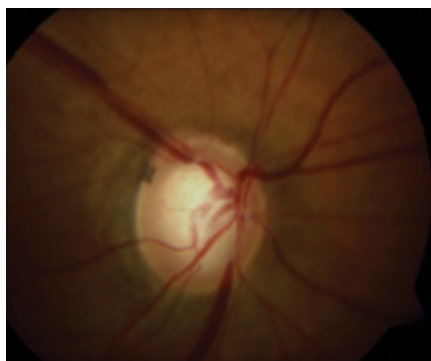
In many cases the intraocular pressure (IOP) is elevated above normal with no cause identified (primary open angle glaucoma (POAG), but 25–30% of glaucoma in New Zealand is 'normal tension' where nerve damage occurs even though the IOP is always within the normal range.

Lowering of the IOP is the main way that we can prevent glaucoma progression, even in 'normal tension' patients.

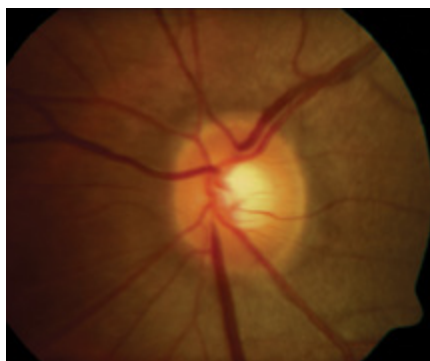
Treatment is also recommended in patients who have elevated IOP without any evidence of glaucoma (ocular hypertensives) if the risk of conversion to glaucoma is unacceptable.

### Incidence

- Incidence: 2–3% of people over 60 years, 5–10% over 80 years.
- Glaucoma is the second leading cause of blindness worldwide after cataract and the leading cause of preventable blindness in New Zealand.



Right  
Optic nerve cupping in right eye compared to normal nerve in left eye. Note kinking of vessels over cupping.



Left



### **Risk factors (including secondary causes):**

- Elevated IOP
- First degree relative with glaucoma
- Van Herick  $<1/4$ , or any iridotrabecular contact on gonioscopy
- Signs of secondary glaucoma causes (pseudoexfoliation syndrome, pigment dispersion syndrome, uveitis, iris/angle new vessels)
- Central corneal thickness  $<510$  microns
- Optic disc margin haemorrhage
- History of blunt eye injury with hyphaema or vision loss
- Increase in measured IOP over time by 50% or more
- Medications at risk of increasing IOP e.g. steroids (topiramate and antidepressants in narrow angles).

### **Symptoms**

- Primary open angle glaucoma are usually asymptomatic until advanced visual field loss has occurred, which is why screening is so important. Screening is recommended every 5 years from the age of 40, every 3 years from the age of 50 and every 2 years from the age of 60. If there is a family history of glaucoma then greater diligence is required.

### **Signs**

- IOP may be elevated ( $>21$ mmHg with a normal central corneal thickness).
- Exclusion of secondary causes of elevated IOP such as pseudoexfoliation, pigment dispersion and angle closure
- Normal Ishihara colour plate testing (unless colour deficient)
- Neuroretinal thinning of the optic nerve head that can be focal (most likely to occur inferotemporally and superotemporally) or global. The remaining neuroretinal rim should be pink, not pale.

### **Immediate management**

- Stratification of the patient into normal (no glaucomatous optic neuropathy) with risk factors (as above, e.g. elevated IOP), glaucoma suspects (suspicious optic nerve/OCT or repeatable visual field defect) and definite glaucoma.
- Consider referral for higher risk normal patients (IOP  $> 25$ mmHg, or IOP 22-25mmHg with a risk factor), glaucoma suspects, and those with definite glaucoma
- IOP lowering with eyedrops can be commenced if there is moderate-advanced glaucoma, extremely elevated IOP, or a significant delay from referral to seeing the ophthalmologist.

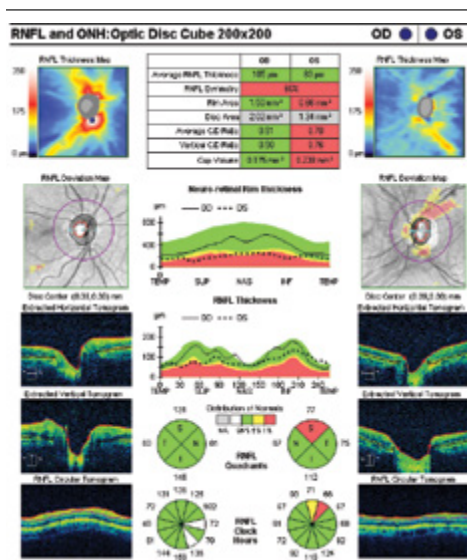
## Long-term management

- Once significant IOP reduction has been achieved, monitoring for glaucoma stability to determine if further IOP reduction is necessary occurs at intervals dependent on the glaucoma severity and patient's age.
- Clinical markers of instability include an increase in cv rim thinning, presence of disc haemorrhage, OCT progression and visual field progression.
- The overarching goal is to maintain quality of life by balancing the burden of treatment (e.g. eyedrop side-effects) and the threat of visual disability from glaucoma (e.g. loss of legal driving vision).
- Stopping smoking and maintaining a healthy diet are likely to help the optic nerve maintain better resistance to glaucomatous damage.



## 11.2 Primary Open Angle Glaucoma – Investigations

### Tests

- Intraocular pressure (IOP) – usually assessed with the Goldmann tonometer at the slit lamp. Hand-held devices such as the Perkins tonometer, Icare tonometer or Tonopen can be helpful for children or debilitated adults. Measured in mmHg and pressures up to 21 are generally considered normal.
- Corneal Thickness/Pachymetry – a thin cornea is an independent risk factor for glaucoma and it also leads the tonometer to underestimate the true IOP. Adjustments also have to be made if the cornea is unusually thick as this will lead to an overestimate. The normal range is 520–570  $\mu\text{m}$ .
- Visual field analysis – this is done with an automated visual field machine in which each eye is tested separately and the threshold light sensitivity is determined in a series of positions in the peripheral vision. There are certain patterns of sensitivity loss which are typical for glaucoma including arcuate, paracentral scotomas and nasal steps. In the early stages the visual fields may be normal. A commonly used machine for measuring the visual field is the Humphrey field analyser.
- Optic nerve and macular analysis – optical coherence tomography (OCT) of the peripapillary retinal nerve fibre layer and macular layers (e.g. ganglion cell layer and nerve fibre layer) are particularly useful for diagnosing glaucoma, excluding retinal pathology (e.g. branch retinal artery occlusions) and for progression monitoring.
- Selective laser trabeculoplasty (SLT) is the favoured primary option as evidence suggests it has more effective IOP control with less disease progression, compared to eyedrops. Interim eyedrop treatment is acceptable while waiting for SLT. When SLT is insufficient for IOP control, the best eyedrop regimens have simple dosing with minimal side effects.



OCT of the optic nerves showing loss of the left nerve fibre layer typical in glaucomatous damage.



Progressive visual field loss in the left eye from glaucoma.

## 11.3 Primary Open Angle Glaucoma – Management

The aim of medical (generally topical, sometimes oral) treatment for glaucoma is to lower the intraocular pressure (IOP).

Selective laser trabeculoplasty (SLT) is the favoured primary option as evidence suggests it has more effective IOP control with less disease progression, compared to eyedrops. Interim eyedrop treatment is acceptable while waiting for SLT. When SLT is insufficient for IOP control, the best eyedrop regimens have simple dosing with minimal side effects

### Treatments

#### First line agent Prostaglandin analogues.

- Administered as one drop at nighttime to the eye(s)
- Topical side effects of initial hyperaemia, eyelash length growth, changes in iris colour (especially in hazel irides which may become darker), local skin pigmentation (more common in pigmented skin types), and fat orbitopathy.
- Rare systemic side effects
- Three available agents:
  - Latanoprost (Hysite)
  - Travaprost (Travatan)
  - Bimatoprost (Lumigan)

#### Second line agents

##### Beta blockers

- Can be used either daily or twice daily
- Minimal topical side effects (stinging/dry eyes)
- Significant systemic side effects (asthma, airways disease, bradycardia, central nervous system depression, dreaming)
- Available agents:
  - Timolol 0.25–0.5%
  - Timoptol XE 0.25–0.5%
  - Levobunolol (Betagan)
  - Betaxolol (Betoptic S)

### **Alpha agonists**

- Used twice daily
- Topical side effects of hyperaemia and local allergic reaction in 5–10%, often months after starting treatment
- Minimal systemic side effects of dry mouth. Contraindicated for children under 10 as causes drowsiness.
- Available agents:
  - Brimonidine (Alphagan)
  - Alphagan P (different preservative, Purite)
  - Iopidine

### **Carbonic anhydrase inhibitors**

- Used twice daily
- Topical side effects of hyperaemia, stinging, unpleasant taste
- Uncommon systemic side effects
- Poorer IOP lowering so usually second line treatment
- Available agents:
  - Dorzolamide (Trusopt)
  - Brinzolamide (Azopt)

### **Pilocarpine**

- Use 3–4 times daily
- Topical side effects of stinging/pain/miosis/headache
- Minimal systemic side effects
- Available agents: Pilocarpine 1, 2, 4% (Isopto-carpine)

### **Other treatment options**

- Many glaucoma patients require more than one topical agent to lower IOP to a safer level. Combination eyedrop preparations are preferred due to improved compliance and to side-effects from preservative/excipient load.
- Available preparations include: Lattim once a day (latanoprost + timolol), Dortim twice a day (dorzolamide + timolol), Combigan (timolol + brimonidine), Duotrav (timolol + travaprost)

### Oral agents

- The only oral medication used to treat glaucoma is the oral form of carbonic anhydrase inhibitor, Acetazolamide (Diamox) 250 mg tabs
- Can have quite effective IOP lowering
- Limited by systemic side effects of gastro-intestinal discomfort, pins and needles, diuresis, taste perversion, renal stones, and hypokalaemia
- Usually only used as short-term temporary treatment up to 2 x 250 mg qid, but side effects dramatically limit use.

### Additional notes

- IOP lowering by at least 25–30% of the presenting IOP is an ideal target, but due to diurnal IOP fluctuation, this can be challenging to determine especially in normal-tension patients.
- The rate of progression and their disease severity are most important in determining how much IOP lowering is required and if glaucoma surgery is required.
- Compliance remains a major issue, but is improved with less frequent dosing and the use of agents with fewer side effects. Education about the asymptomatic nature of the disease and that treatment is to save vision rather than improve it are important concepts. Mobile phone timers and family assistance can be valuable tools to consider.
- Topical agents have preservatives which may be responsible for allergic reactions and limiting use. Non-preserved single-use minims may be available but are expensive
- Elderly patients may have difficulty instilling drops and a variety of bottle designs and appliances can help with this

## 11.4 Secondary glaucoma

Secondary glaucoma is a group of conditions where there is an obvious cause for raised intraocular pressure. There are many causes of secondary glaucoma.

### Steroids

For some people there is a genetic predisposition that means they get an increased intraocular pressure (IOP) with topical (and rarely oral) steroids. It can occasionally arise from steroid creams around the eyes and even steroid nasal sprays. Those with the predisposition also have an increased risk of Primary Open Angle Glaucoma (POAG) and should be particularly vigilant about having regular checks with their optometrist. If steroid drops are required for uveitis or some other eye condition then the patient may need concurrent IOP-lowering treatment.

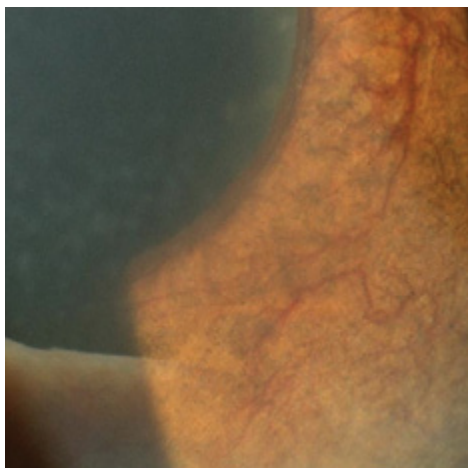
### Uveitis

Inflammation can cause glaucoma in various ways:

- Inflammation and swelling of the trabecular meshwork.
- Inflammatory cells clogging the trabecular meshwork.
- Inflammation causing synechial scarring of the peripheral iris to the posterior cornea (peripheral anterior synechiae) – a type of secondary angle closure.
- Posterior synechiae with the pupil adherent to the lens preventing aqueous flow through the pupil. The iris bows forwards (iris bombé) and blocks the angle – another type of secondary angle closure. This is treated with a laser iridotomy.
- Steroid response to iritis treatment – as above.

### Trauma

Blood from a hyphaema can block the trabecular meshwork and increase the IOP. Blunt trauma can stretch and tear the anterior chamber angle causing angle recession. This can cause a temporary IOP elevation, which then settles, but anyone with angle damage is at long-term risk of raised IOP and needs at least annual review.



Iris neovascularisation in rubeotic glaucoma.



## Other ocular conditions

### Pseudoexfoliation

This is a basement membrane disease that manifests in the eyes. It produces flakiness on the anterior capsule of the lens and this material blocks the trabecular meshwork and causes pressure elevation. Anyone with this condition needs regular monitoring. The disease also softens the lens zonules and increases the likelihood of zonular dehiscence as a complication of [Cataract Surgery](#). The risk of glaucoma is about 10% over a decade.

### Pigment dispersion

Usually in myopes 30–50 years old, where the iris bows backwards and the posterior pigment layer rubs on the lens zonules. This releases pigment into the aqueous which can then clog the trabecular meshwork. There is usually a vertical streak of pigment on the corneal endothelium called a Krukenberg spindle. The IOP can be a lot more labile than usual with IOP elevation even with exercise. 50% of those with pigment dispersion will get glaucoma.

### Rubeotic glaucoma

Retinal ischaemia from, for example, severe diabetic disease or a retinal vein occlusion results in the release of vasoproliferative substances such as vascular endothelial growth factor (VEGF). This can result in neo-vascularisation of the iris and these new vessels can cause scarring in the angle, which leads to a complex type of secondary angle closure glaucoma. Treatment involves reducing the release of VEGF by lasering the ischaemic retina and then treating the elevated IOP. Also, injecting anti VEGF medication such as Bevacizumab (Avastin) might help. Drops are frequently inadequate and surgery is often needed. If the eye is already blind then it may be reasonable to accept the high IOP and use topical atropine and steroids just to keep the eye comfortable.

## 11.5 Acute Angle Closure Glaucoma

Acute rise of intraocular pressure (IOP) in predisposed eyes caused by occlusion of the drainage angle by the iris.

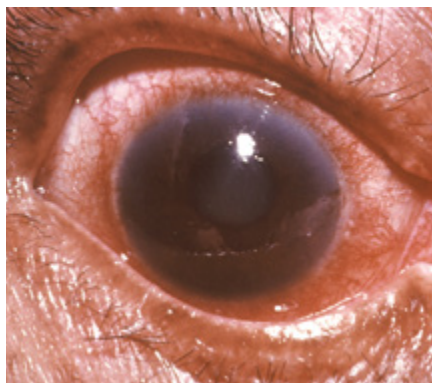
- **Aetiology:** predisposed eyes have a narrow angle with a crowded anterior segment. They usually are hyperopic (long-sighted) with a short axial length. The condition is more common with increasing age as the lens thickens and pushes the iris forward, narrowing the angle. The eye then reaches a critical state where there is a build up of aqueous behind the iris to push it further forward and occlude the angle, which results in a rapid rise in IOP.
- The rapid rise in IOP means there is little chance for the eye to compensate so the iris becomes ischaemic and the nerve can become severely damaged over a matter of hours.

### Symptoms

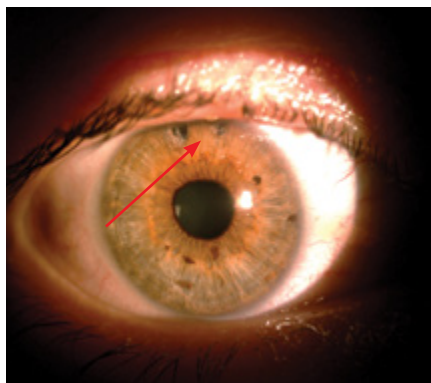
- Unilateral intense aching pain around the eye.
- Redness of the eye.
- Reduced vision in the affected eye.
- Nausea/vomiting.
- Headache.

### Signs

- Reduced vision.
- Inflamed eye with a hazy oedematous cornea.
- Mid-dilated poorly reactive pupil – this is pathognomonic sign.



Christmas tree cataract with colourful refractile opacities in the lens.



Laser iridotomy.

## Immediate Management

- The aim of immediate treatment is to lower the IOP sufficiently to reduce damage to the eye and to enable the cornea to clear. Once the cornea has cleared the patient can be treated with a YAG laser iridotomy. Treatment is with topical medications like Timolol and Brimonidine as well as oral acetazolamide (Diamox) and sometimes even intravenous Mannitol (an osmotic agent).
- Once the IOP has been lowered sufficiently, a laser iridotomy can be preformed.

## Long term management

- In most cases laser iridotomy is curative although occasionally the angle has suffered a degree of damage that requires ongoing glaucoma drops or even surgery.
- Ongoing review by an ophthalmologist is usually required.
- *Cataract Surgery* is sometimes required to help open and deepen the drainage angle.
- **Prophylactic iridotomies:** if a patient is found to have narrow angles, even if they have no history of problems, prophylactic laser iridotomies may be warranted to reduce the risk of an attack of angle closure glaucoma. These patients are often detected and referred by an optometrist following a routine eye exam.

## Referral guidelines

- Acute glaucoma is an emergency and should be referred immediately.
- Subacute angle closure, which can be a precursor to Acute Angle Closure Glaucoma (AACG), may cause recurrent episodes of aching pain, as well as blur and haloes around lights. These patients should be referred for assessment of their angles and consideration of prophylactic iridotomies.

## Causing angle closure with pharmacological pupil dilation

This is rare and only occurs in those with pre-existing narrow angles, so it is likely that closure might have occurred at some point anyway. The key thing is to recognise the problem and refer the patient immediately.

## Glaucoma warnings with systemic medications

Some medications, such as tricyclic antidepressants, carry warnings about them being used in people with glaucoma. This is usually because the medications have a potential anticholinergic effect, and could cause pupillary dilation and precipitate angle closure. This is highly unlikely and could occur only in someone with pre-existing very narrow angles and no laser iridotomies. There is no risk in primary open angle glaucoma (POAG). If in doubt the ophthalmologist will be able to tell whether it's a concern or not.

## 11.6 Glaucoma surgery

### Laser procedures for glaucoma

#### YAG Peripheral Iridotomy (YAG PI)

A YAG laser is used to create an opening in the peripheral iris to either prevent or treat closed angle glaucoma.

#### Laser Trabeculoplasty (Selective Laser Trabeculoplasty (SLT) )

This is a benign procedure in which 60 laser spots of 50 microns each are placed around 180 degrees of the trabecular meshwork. This improves aqueous drainage in about 70% of people and if the effect wears off over time then it can be repeated. It is not usually an adequate treatment on its own but can be useful in supplementing eye drops.

#### Laser Iridoplasty

This is occasionally used for those with narrow anterior chamber angles who have had insufficient opening of the angle with an iridotomy. A series of laser applications are made to the iris periphery to contract the iris and pull it away from the angle.

#### Surgery to improve aqueous drainage

Paediatric glaucoma operations for congenital glaucoma

#### Goniotomy

A fine needle or goniotomy knife is introduced into the anterior chamber and used to create a 120 degree incision around the trabecular meshwork. This improves aqueous drainage out of the eye and lowers the IOP. It has a success rate of 80–90%.

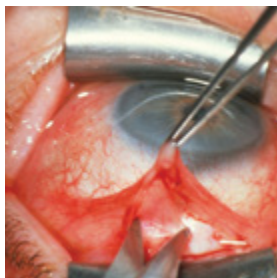
#### Trabeculotomy

If the cornea is too cloudy to allow a view for goniotomy then an external approach can be made. A partial thickness scleral flap is made and Schlemm's Canal identified within the sclera. A curved blade is passed along Schlemm's Canal for 120 degrees on either side of the flap and then rotated into the anterior chamber. This improves egress of aqueous from the anterior chamber and lowers the IOP.

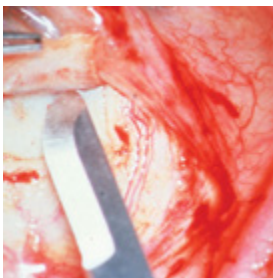
#### Adult glaucoma operations

##### Lens surgery

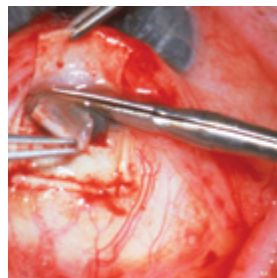
Cataract extraction and even removal of a clear lens is used at times to try to control pressure and works particularly well for those with very narrow angles and with high presenting pressures. If another glaucoma procedure is contemplated and some cataract is present then it is often advisable to remove



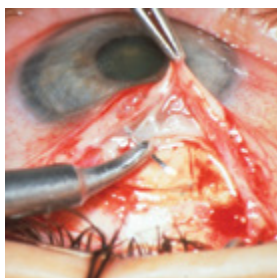Creating opening in conjunctiva superiorly.



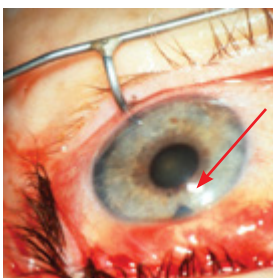
Creating a partial thickness scleral flap.



Removing a block of sclera under the flap into the anterior chamber.



Suturing the flap.

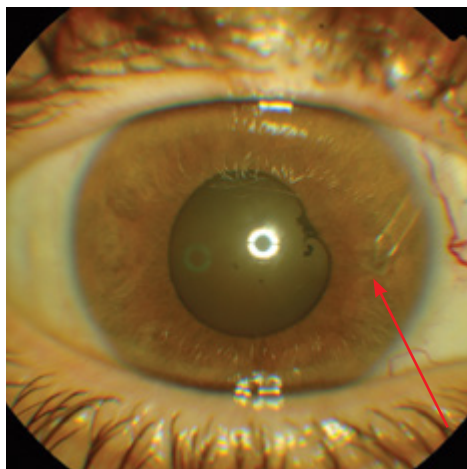


Surgery completed with bleb formed.

the cataract first and assess the IOP response before proceeding to a definitive glaucoma operation.

### Trabeculectomy

This is the most powerful glaucoma surgery available. An opening is made through the conjunctiva to expose bare sclera. A partial thickness scleral flap is fashioned and then a block of tissue in the base of the flap is excised to create a pathway into the anterior chamber. A section of iris is removed (peripheral iridectomy) and then the flap is sutured down and the conjunctiva repaired to make it watertight. Aqueous perfuses through and around the edge of the flap and collects under the conjunctiva to form a blister called a bleb. From here the aqueous drains through the conjunctiva into the tear film or



Drainage tube of a Molteno implant within the anterior chamber for treatment of glaucoma.

into the local blood vessels. This surgery has an 80–90 % success rate, but can be compromised by excessive scarring of the scleral flap or conjunctiva post-operatively. To help prevent this it is common to apply an anti-metabolite agent, Mitomycin-C, to the sclera at the time of surgery. Frequent post-operative visits are required over the first couple of months and the effect of the surgery can be titrated by removing releasable sutures in the scleral flap or by cutting sutures with a laser.

### **Glaucoma Drainage Devices (Aqueous Tube Shunts)**

- These are small plastic tubes that are placed into the eye, usually in front of the iris, to drain aqueous to a reservoir plate. The tube is protected by donor sclera which appears as a small white rectangle area adjacent to the limbus.
- The most common tube of type in New Zealand is a Molteno Tube (invented by Professor Antony Molteno in Dunedin). Some patients may have a Baerveldt Tube.
- Usually used for secondary complex forms of glaucoma including neovascular glaucoma.

### **Microinvasive Glaucoma Surgery (MIGS)**

- MIGS usually refers to devices/procedures that cause a modest reduction in IOP, such as trabecular bypass stents (e.g. iStent, Hydrus) and trabecular bypass surgery (e.g. Kahook Dual Blade)
- Microinvasive bleb-forming surgery (MIBS) is a subcategory that leads to much more IOP reduction by using the same IOP reducing pathway as trabeculectomy (subconjunctival). Devices include Preserflo and Xen.
- Micropulse laser also falls into the MIGS category and is a newer, gentler external laser procedure with evidence for significant IOP lowering. It is applied in a similar fashion to cyclodiode laser.

### **Operations to reduce aqueous production**

Cyclophotocoagulation/Cyclodiode laser – this traditional external laser works by ablating ciliary processes, which produce aqueous humour. A probe is placed on the sclera 1.5 mm posterior to the limbus, overlying the ciliary body where aqueous is produced. The diode laser energy is focused 0.9 mm beyond the tip of the probe so it is directed through the sclera and on to the ciliary tissue. A series of applications are made over 180–360 degrees



## 12 *Uveitis*

## 12.1 Acute Anterior Uveitis

Inflammation of iris and ciliary body. Anterior uveitis is the most common type of uveitis seen in Auckland, and almost half the cases are associated with HLA B27-antigen.

Prognosis is better than with other types of uveitis.

### Symptoms

- Pain (eye ache).
- Photophobia.
- Reduction in visual acuity.

### Signs

- Red eye, with redness particularly concentrated around the limbus (edge of cornea).
- Clear cornea.
- Pupil misshapen with posterior synechiae, poorly reactive to light.

### Slit lamp signs

- Red eye.
- Corneal keratic precipitates (deposits of inflammatory cells on endothelium).
- Anterior chamber cells and flare.
- Hypopyon if severe ("pool" of inflammatory cells settled at the bottom of the anterior chamber).
- Fibrin if severe (webs and fibres of inflammatory material in the anterior chamber).

### Immediate management

- Treatment is with intensive topical Pred Forte drops, slowly tapered over several weeks.
- Cycloplegic drops (usually cyclopentolate) and Maxidex ointment at night.

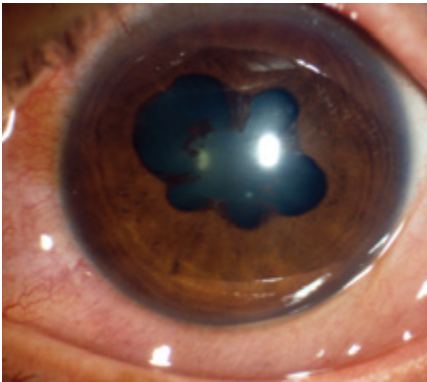### Long-term management

- Recurrent episodes common in either eye.
- Treatment between episodes is almost never required.
- Systemic investigations should be considered to look for underlying cause. HLA B27-antigen most common association in New Zealand.

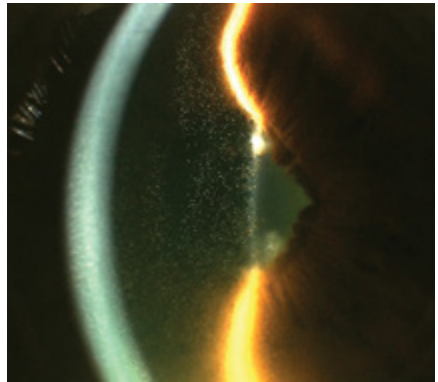


## Referral guidelines

- Any case of suspected anterior uveitis should be referred within 24 hours.
- More urgent if vision poor or hypopyon present.



Inflammation of the iris makes it 'sticky', causing adhesions between the iris and the lens – posterior synechiae.



Dust-like specks in the beam of light are inflammatory cells in the anterior chamber.

## 12.2 Chronic Anterior Uveitis

Chronic anterior uveitis is inflammation of iris and ciliary body that has persisted for more than 3 months.

It has an increased risk of complications, such as cataract and glaucoma. It can be associated with systemic disease including juvenile idiopathic arthritis, sarcoidosis and tuberculosis.

### Symptoms

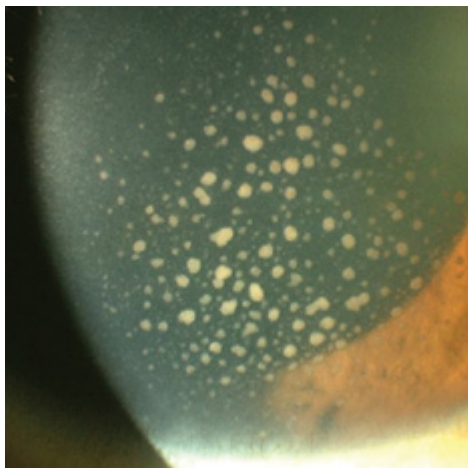
- Often more insidious and less severe than acute anterior uveitis.
- Redness.
- Blur.
- Photophobia.

### Signs

- Redness may be present.
- Posterior synechiae (adhesions between the iris, usually the pupil margin, and the lens).
- Cataract if chronic inflammation is present.

### Slit lamp signs

- Redness.
- Keratic precipitates (deposits of inflammatory cells on cornea).
- Anterior chamber cells and flare.
- Posterior synechiae.
- Hypopyon and fibrin are generally NOT a feature (unlike acute anterior uveitis ([See 12.1 Acute Anterior Uveitis on page 133](#))).
- Cataract, glaucoma, and band keratopathy can all develop with chronic uveitis.



Clumps of inflammatory cells on the posterior surface of the cornea are called keratic precipitates.

### Immediate management

- Systemic work up to look for underlying problems, e.g. sarcoid, JIA.
- Topical Pred Forte drops, tapered to minimum level required to control inflammation and maintain at this level.

### Long-term management

- Topical Pred Forte at minimum dose to control disease.
- In children, NSAIDS or methotrexate is often required .

### Referral guidelines

Refer within 1 week if suspected chronic anterior uveitis (within 24 hours if significant discomfort or decrease in vision)

## 12.3 Intermediate Uveitis

Inflammation of the uveal tract, predominantly around the pars plana (area between ciliary body and peripheral retina), resulting in vitritis.

Most cases are idiopathic, but some are associated with systemic disease including multiple sclerosis, sarcoidosis, tuberculosis, syphilis and psoriasis.

### Symptoms

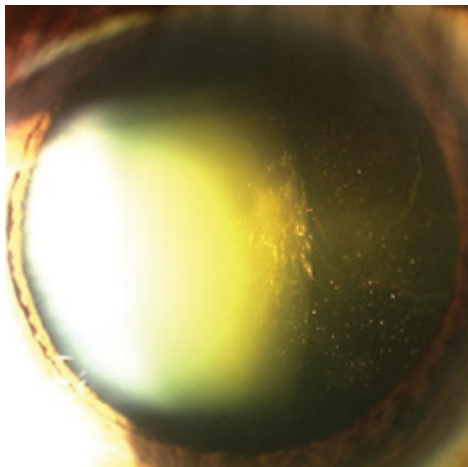
- Floaters.
- Blurred vision.
- Photophobia may be present.

### Signs

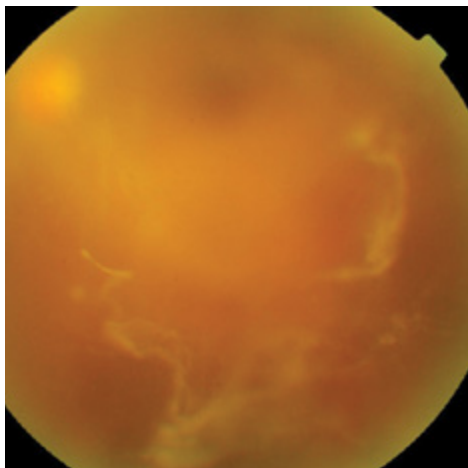
- +/- redness.
- +/- posterior synechiae.
- +/- cataract.
- Red reflex often impaired.

### Slit lamp signs

- Anterior chamber cells (usually mild).
- Vitreous cells and haze, snowball opacities may be present in inferior vitreous.
- Cystoid macular oedema a common complication (central swelling of macula causing reduced vision).
- Other complications may be present, e.g. cataract, glaucoma.



Vitreous cells can be seen by focusing the light beam behind the lens using high magnification.



Cells and fibrin within the vitreous make it opaque and obscure the view of the retina in vitritis.

### Immediate management

- Not all cases need treatment.
- Treatment indicated if vision-threatening problems such as cystoid macular oedema present, or if disabling symptoms.
- If treatment is indicated, the main options are periocular Triamcinolone injections, or oral steroids.

### Long-term management

- Many patients have a chronic course. Some will require disease-modifying immunosuppressant medications, if the course is severe and not controlled on low doses of oral steroid or periocular steroid injections.
- Investigations to exclude sarcoid, TB, syphilis.

### Referral guidelines

Sudden floaters or pain need prompt referral (within 24 hours). Insidious onset of gradual floaters should be reviewed within 4 weeks.

## 12.4 Infectious Uveitis – Fungal

Uncommon intraocular infections, mainly seen in patients who are debilitated and have had chronic catheters or intravenous lines, or in intravenous drug users.

### Symptoms

- Usually a subacute onset of increasing floaters and blur.
- Pain and redness may occur but are less prominent than in bacterial endophthalmitis.

### Signs

- External eye may be quiet or red.
- Posterior synechiae may develop, causing a misshapen pupil.
- Red reflex may be impaired if there is significant vitritis.

### Slit lamp signs

- Redness.
- Anterior chamber cells.
- Vitritis – large clumps of cells often develop in inferior vitreous, known as “snowballs”.

### Immediate management

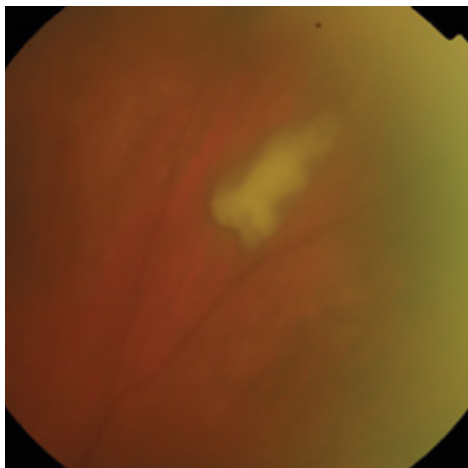
- Vitreous tap and injection of antifungal medication.
- Systemic antifungal agents.
- Look for source of infection.

### Long-term management

- Close monitoring until infection has resolved. Vitrectomy may be required to clear vitreous debris.

### Referral guidelines

Patients with increasing floaters and blur, especially in context of intravenous drug use or recent hospital admission.



‘Snowball’ opacities in the vitreous consist of active fungal elements.

## 12.5 Viral Uveitis

Viral uveitis can be caused by herpes simplex viruses 1 and 2, varicella zoster, and less commonly by cytomegalovirus. Most common presentation is with an anterior uveitis, but rarely a severe form of posterior uveitis can develop known as acute retinal necrosis (ARN).

### Symptoms

#### Herpes simplex

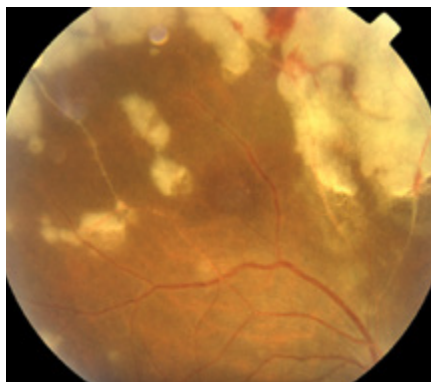
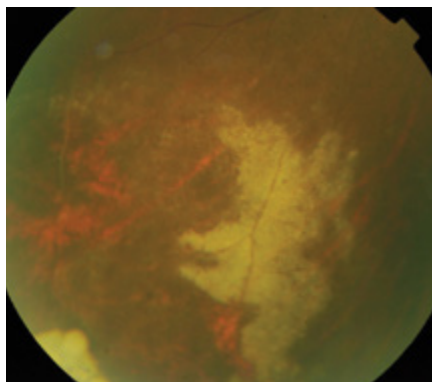
- Redness.
- Eye pain and blur, usually unilateral.
- May be a previous history of dendritic corneal ulcers ([See 8.2 Herpes Simplex Keratitis on page 67](#)). Often recurrent.

#### Herpes zoster

- Pain and rash in distribution of trigeminal nerve, unilateral.
- Eye redness, pain and blur.
- Floaters are not a feature, unless complications such as ARN have developed.

#### Acute retinal necrosis

- Pain, blur, floaters. Unilateral initially, can later become bilateral. There may be a preceding history of herpes zoster infection (any dermatome in body) within prior 6 weeks. Can develop in any age, more common if immunosuppressed.



Large areas of active CMV retinitis.

## Signs

### **Herpes simplex and herpes zoster anterior uveitis** (See [8.2 Herpes Simplex Keratitis](#) on page 67):

- Redness.
- Corneal oedema may be present overlying centrally, causing corneal haze.
- Corneal stromal scarring may be present if previous episodes have occurred.
- May have reduced corneal sensation (check with cotton tip or corner of tissue paper – compare to other eye).
- Sectoral iris atrophy (may be evident when checking red reflex, one area of iris will transilluminate as thinner).

### **Acute retinal necrosis:**

- Redness.
- +/- distorted pupil from posterior synechiae, +/- relative afferent papillary defect.
- Poor red reflex if vitritis present.
- Through a dilated pupil, creamy multifocal necrotising lesions in the peripheral retina may be seen.

## Slit lamp signs

### **Herpes simplex and herpes zoster anterior uveitis: (also see 4-2 and 4-3)**

- Redness.
- Cornea: keratic precipitates, and often corneal oedema overlying the keratic precipitates, causing corneal haze.
- Corneal stromal scarring may be present if previous episodes have occurred.
- Sectoral iris atrophy – more common with herpes zoster.
- May have raised intraocular pressure.

### **Acute retinal necrosis:**

- Anterior chamber cells.
- Corneal keratic precipitates.
- Vitritis.
- Elevated intraocular pressure.
- Creamy multifocal necrotising lesions in the peripheral retina.
- Retinal vasculitis, predominantly affecting arteries.
- Retinal tears or detachments can develop.
- Can be unilateral or bilateral. Bilateral disease will develop in 30% if systemic Acyclovir is not given.



## Immediate management

### Herpetic anterior uveitis:

- Topical Pred Forte steroid drops – usually only required qid to 6 times per day.
- Topical Acyclovir ointment 5 times per day in cases of HSV (not required for HZO).

### Acute retinal necrosis:

- Admit patient, diagnostic anterior chamber tap. Intravenous Acyclovir for 1–2 weeks (or oral Valganciclovir).

## Long-term management

### Herpetic anterior uveitis:

- Uveitis secondary to varicella zoster typically has a chronic course, and requires a very slow steroid taper over months. Glaucoma and cataract are common.
- Uveitis secondary to herpes simplex is more episodic, with complete remission between episodes and most patients come off treatment between attacks.

### Acute retinal necrosis:

- The initial intensive inpatient treatment is followed by systemic acyclovir for at least 6 weeks and longer if immunocompromised. Visual prognosis is generally poor, with median final visual acuity 6/60.

## Referral guidelines

- Urgent referral of herpes zoster patients should be made if patient is immunocompromised, if complaint of visual loss or if new onset of floaters.
- Suspected or recurrent HSV cases should be referred within 24 hours.

## 12.6 Endogenous Endophthalmitis

Rare form of endophthalmitis that results in seeding of infection from another source in the body. Sources include endocarditis, liver abscesses, infected lines or catheters. It results in a very serious ocular infection that can be blinding.

### Symptoms

Acute onset of redness, pain, photophobia and decreased vision.

### Signs

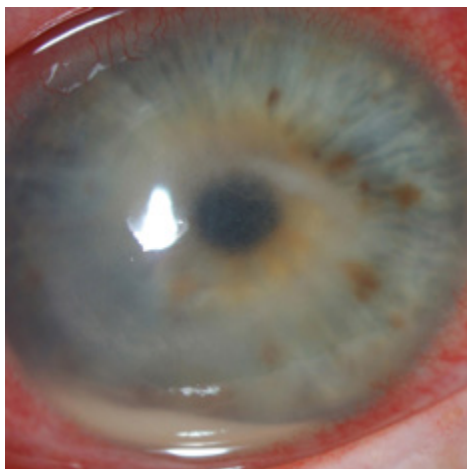
- Redness.
- Hypopyon common (collection of inflammatory cells in the bottom of the anterior chamber).
- Cornea may be hazy.
- Poor red reflex.

### Slit lamp signs

- Redness.
- Hypopyon and fibrin (webs and fibres of inflammatory material in the anterior chamber).
- Posterior synechiae (adhesions between the iris, usually pupil margin, and the lens).
- Vitritis (inflammatory cells in the vitreous).
- Choroidal abscess may be visible in fundus, or view may be obscured through inflammation.

### Immediate management

- If diagnosis is suspected, an urgent vitreous tap and injection of antibiotics and antifungals should be performed (unless source already known and cultured elsewhere). Intravenous antimicrobials required.
- Investigations to identify source of infection should be performed, including blood cultures, chest X-ray, urine cultures.



Inflamed, painful eye with hypopyon in endogenous endophthalmitis.

### Long-term management

- Continue antimicrobial therapy until infection is controlled. Vitrectomy is useful in some patients.
- Visual prognosis is guarded.

### Referral guidelines

Urgent referral of any patient who is constitutionally unwell who has acute or subacute eye pain, photophobia and decrease in vision, especially if hypopyon present.

## 12.7 Toxoplasma Chorioretinitis

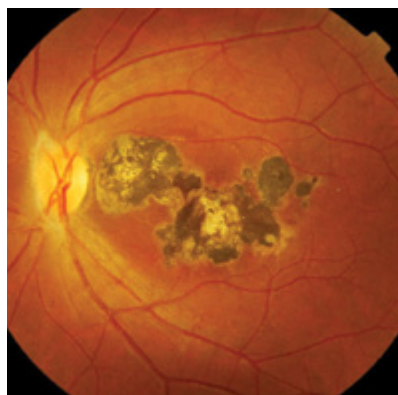
Toxoplasmosis is the most common cause of posterior uveitis worldwide. Infection is either congenital by transplacental route or acquired early in life.

### Symptoms

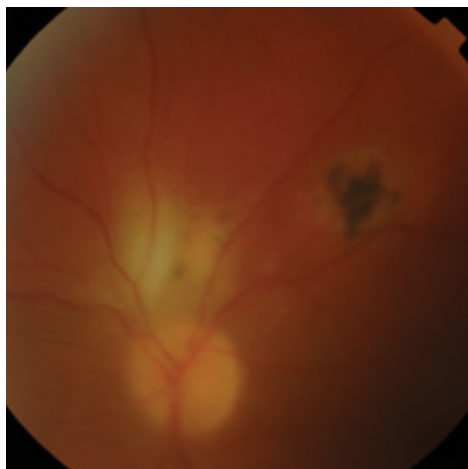
- Unilateral flares (unless severely immunocompromised).
- Floaters.
- Blurring of vision.
- Redness and pain associated with anterior uveitis.

### Signs

- Redness.
- Reduced visual acuity.
- Red reflex may be impaired through vitritis (inflammatory cells in the vitreous).
- Unifocal area of chorioretinitis.



Pigmented toxoplasma scars at the macula.



Creamy area of retinitis adjacent to the disc in active toxoplasma infection. The pigmented area is a scar from a previous episode of activity.

### Slit lamp signs

- Redness.
- Corneal keratic precipitates (collections of inflammatory cells on the endothelium). May be fine (non-granulomatous) or large (granulomatous).
- Intraocular pressure may be elevated.
- Vitritis.
- Creamy white focal area of chorioretinitis, often occurring adjacent to an old pigmented scar.
- Surrounding vasculitis may be present.
- May have optic nerve swelling.

### Immediate management

- Start oral antibiotics, e.g. Clindamycin or Cotrimoxazole.
- After 24–48 hours, oral steroids are added.
- Topical steroid to control anterior uveitis.

### Long-term management

- 6-week treatment course of combined antibiotic/ steroid usually required. Recurrences can occur throughout life.

### Referral guidelines

- Refer within 24 hours, especially if known history of toxoplasmosis.

## 12.8 Retinal Vaculitis

Inflammation of retinal veins or arteries. It may present as an isolated ocular disease, or in association with other systemic problems, such as Behcet's disease, sarcoidosis and tuberculosis.

### Symptoms

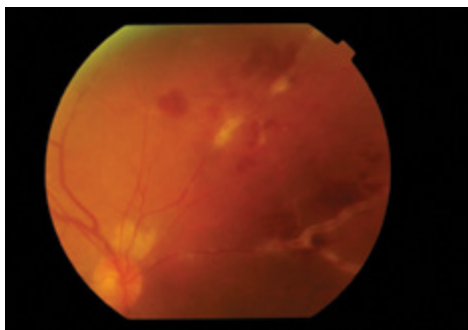
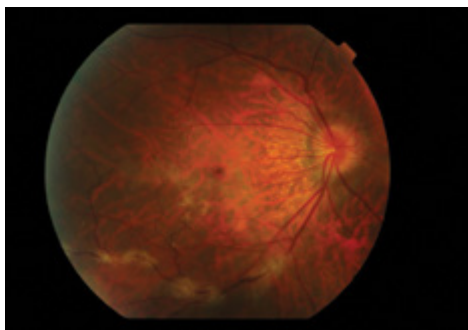
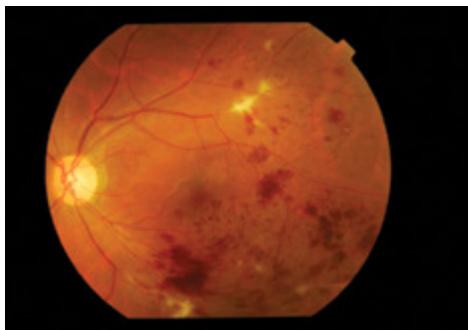
- Blur.
- Floaters.
- May have pain, photophobia and redness if some concurrent anterior uveitis present.

### Signs

- May or may not have redness. Distorted pupil may be present from posterior synechiae (adhesions between iris and lens). Impaired red reflex if significant vitritis present.
- Through a dilated pupil, vascular sheathing (whitening around vessel) and retinal haemorrhages may be seen.

### Slit lamp signs

- Variable redness.
- May have anterior chamber (AC) cells. Varies from quiet AC, to hypopyon (pool of inflammatory cells in the bottom of the anterior chamber).
- Possible vitritis (inflammatory cells in the vitreous).
- Vasculitis and sheathing of retinal arteries and/or veins.
- Vascular occlusions can occur if vasculitis is severe.
- Neovascularisation of optic nerve or retina may develop in severe cases.



White areas of inflammation along the vessels in vasculitis with associated retinal haemorrhages where the vessel has been occluded or has leaked.

### Immediate management

- Full systemic work-up to look for associated disease including: Behcet's, TB, syphilis, SLE, sarcoidosis.
- If there is vision-threatening vasculitis, aggressive treatment is required to prevent permanent visual loss. If infective aetiology is excluded, high dose steroid therapy should be initiated.

### Long-term management

- For immune-mediated cases, slow tapering of steroids while monitoring for rebound.
- Disease modifying agents are required in severe cases.

### Referral guidelines

- Refer within 24 hours, more urgent if known Behcet's disease or marked decrease in vision.

## 12.9 Sarcoidosis

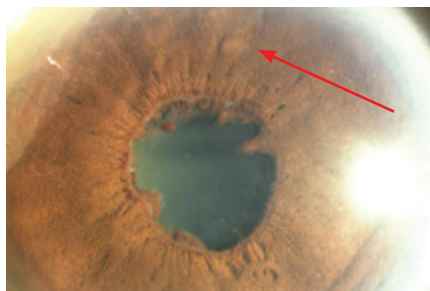Ocular sarcoidosis usually occurs in association with systemic sarcoidosis. It can cause anterior uveitis, intermediate, posterior or panuveitis.

Retinal vasculitis and optic neuritis can complicate disease. Disease course is often chronic, although a relapsing-remitting course can develop.

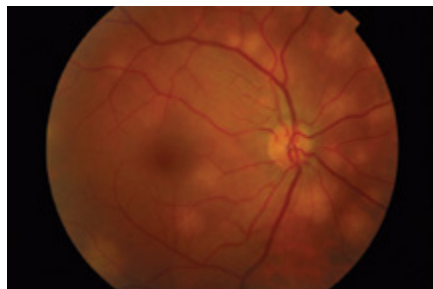
- Sarcoidosis can also cause conjunctival granulomas and infiltration of the lacrimal glands.
- Eye findings are thought to occur in 25% of patients with systemic sarcoidosis at some point in their disease.

### Symptoms

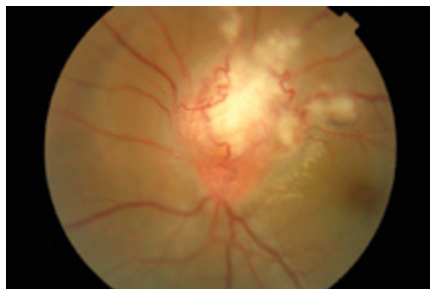
- Uveitis is usually bilateral.
- Anterior uveitis is the most common manifestation, and can present acutely, or with chronic disease (often is more gradual onset of redness, pain, photophobia and blur).
- Floaters (if intermediate or posterior uveitis is present).
- Blur – can be sudden and severe if optic nerve involvement occurs.



Iris nodules and posterior synechiae in sarcoidosis.



Pale areas under the retina are granuloma of the choroid in sarcoidosis.



Granuloma of the optic nerve in sarcoidosis.



## Signs

- Redness.
- Distorted pupil if posterior synechiae (iris adhesions to the lens) are present.
- Reduced red reflex if vitritis or cataract is present.
- Pupil abnormalities if optic neuritis is present (relative afferent papillary defect).

## Slit lamp signs

- Corneal keratic precipitates – often large and “mutton-fat”/granulomatous.
- Anterior chamber cells and flare.
- Posterior synechiae.
- Cataract in chronic disease.
- Vitritis and larger “snowball” opacities in inferior vitreous.
- Multifocal small choroidal lesions.
- Retinal vasculitis with sheathing around retinal veins.
- Optic nerve swelling or pallor.
- Cystoid macular oedema (central swelling of the retina).

## Immediate management

- Initial management is with steroids. Anterior uveitis usually responds well to topical steroids, started intensively and slowly reduced.
- Symptomatic vitritis, mild posterior uveitis or cystoid macular oedema can be treated with periocular steroid injections or with oral steroids.
- Moderate to severe uveitis, retinal vasculitis or optic neuritis require systemic steroids.

## Long-term management

- Chronic ocular sarcoidosis may require other systemic immunosuppression such as Cyclosporine or Methotrexate, in addition to steroids, if risk of visual loss or steroid-induced side effects is high.
- Relapsing-remitting disease course may only require episodic therapy.
- Many patients show complete remission of their disease within several years.

## Referral guidelines

- Any patient with known sarcoidosis and visual blur, pain or floaters should be referred for evaluation. Sudden changes in vision require more urgent assessment .

## 12.10 Behcet's Disease

Uveitis is the initial manifestation of Behcet's disease in 30% of patients. Ocular disease is common, with recurrent and explosive disease, and interval periods of quiescence. It can lead to severe visual loss.

### Symptoms

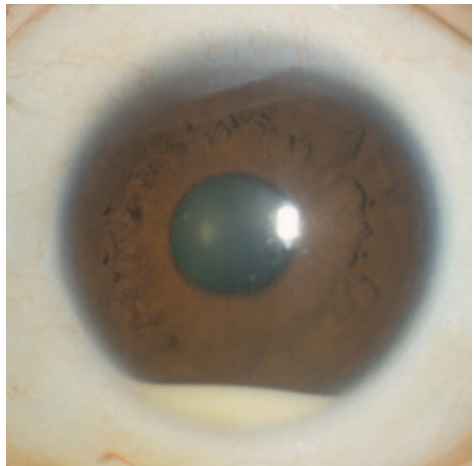
- Sudden onset of symptoms is common.
- Symptoms are variable, but typically blur and floaters.
- Pain and redness may not be present, even if significant anterior chamber reaction is present.
- Other systemic features: recurrent aphthous mouth ulcers, genital ulcers, erythema nodosum or other suggestive skin lesions.

### Signs

- Redness may be absent.
- Hypopyon (pus level in anterior chamber): this is shifting, and will slide with changes in head position.
- Poor red reflex if significant vitritis is present.

### Slit lamp signs

- Corneal keratic precipitates (small and fine, non-granulomatous).
- Anterior chamber cells: may be severe, even hypopyon uveitis.
- Vitritis.
- Retinal vasculitis (often occlusive).
- Retinal infiltrates.
- Optic nerve swelling.



Hypopyon in Behcet's disease. It tends to be more mobile than hypopyon in other conditions.

### Immediate management

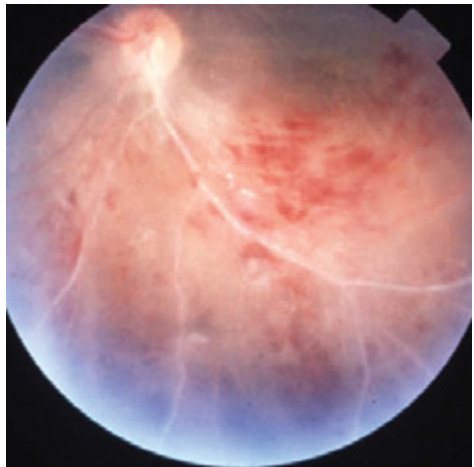- Intensive systemic therapy is required to prevent visual loss during flares.
- Systemic steroids started initially, but almost all patients will require other immunosuppressive agents.

### Long-term management

- Long-term immunosuppression is usually required, in consultation with a rheumatologist or immunologist.

### Referral guidelines

- Any patient with known Behcet's disease and new onset of visual symptoms must be referred promptly.
- Any hypopyon uveitis or patient presenting with rapid onset of floaters and blur must be seen urgently.



Vitritis and vasculitis in Behcet's disease.

## 12.11 White Dot Syndromes

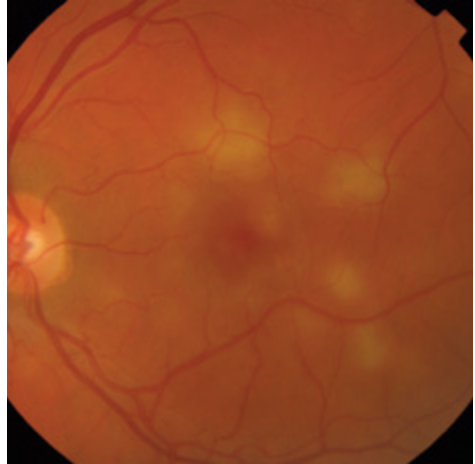
A rare, diverse group of poorly understood inflammatory choroidopathies, including punctuate inner choroidopathy (PIC), acute multifocal placoid pigment epitheliopathy (AMPPE), serpiginous choroidopathy, and multiple evanescent white dot syndrome (MEWDS).

Clinical features vary, however all have a predisposition for affecting young patients, with a female predisposition. Aetiology is obscure, but viral prodrome is noted in some patients and there is an increased association with other systemic autoimmune problems. AMPPE also has a rare association with cerebral vasculitis.

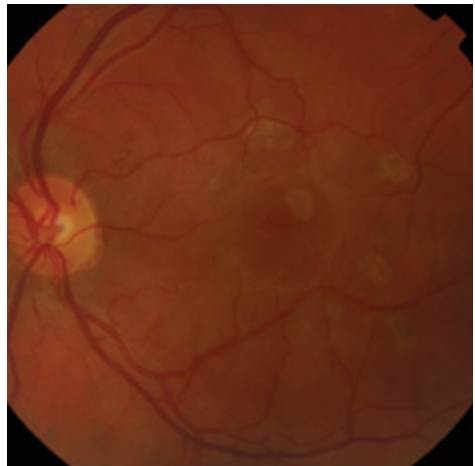
Most white dot syndromes have good prognosis, unless complications such as choroidal neo-vascular membrane develops. Serpiginous choroidopathy does have more variable prognosis, and is often relentlessly progressive and poorly responsive to immunosuppression.

### Symptoms

- Usually bilateral, rapid onset of visual blur.
- Pain and redness are not usually features.
- Distortion (straight lines appearing wavy) may be present.
- Occasionally systemic features, such as headache.



Multiple areas of pallor around the macula in active Acute Multifocal Placoid Pigment Epitheliopathy (AMPPE).



Pigmented and pale retinal changes in resolved AMPPE.

## Signs

- Reduced vision.
- White eye.
- Normal red reflex.
- May be no obvious signs of inflammation without slit lamp examination.

## Slit lamp signs

- Usually quiet anterior chamber and vitreous, or only minimal activity.
- White/pale spots in fundus in both eyes, usually a predilection for posterior pole.
- Occasionally subretinal haemorrhage if choroidal neo-vascularisation has developed.

## Immediate management

Refer for assessment: treatment with systemic immunosuppression is not always needed, as some types of WDS have a good natural history (an exception is serpiginous choroidopathy).

## Long-term management

Certain types of WDS have short-lived duration and do not require long-term management. Many patients will require ongoing self-monitoring with an Amsler grid to check for onset of distortion, as choroidal neo-vascularisation can be a late complication.

## Referral guidelines

Any patient with sudden onset of blurred vision or distortion.

## 12.12 Masquerade Syndromes

Conditions that mimic uveitis, particularly haematological malignancies, such as intraocular lymphoma

### Symptoms

- Most patients are elderly and present with gradual onset of increasing floaters and blur. Pain and redness are infrequent, and if present tend to be mild.
- There may be a history of confusion, unsteadiness or other neurological symptoms to suggest cerebral lymphoma.

### Signs

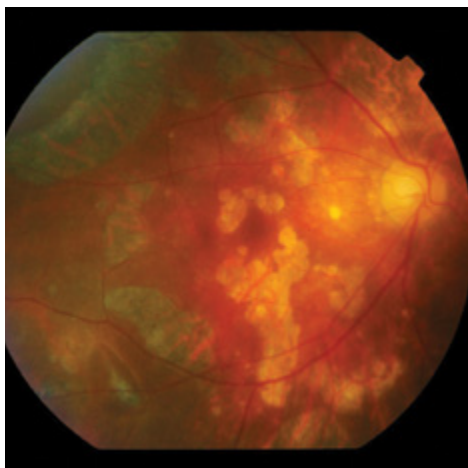
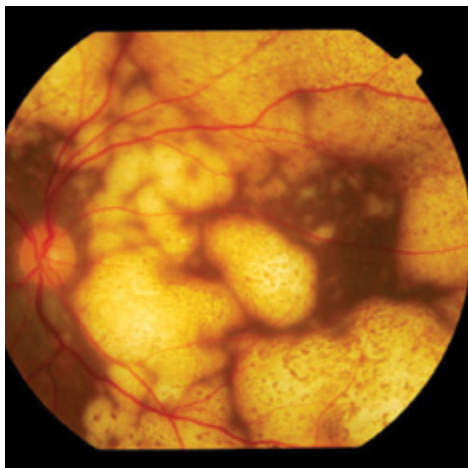
- Often the external eye is white. Occasionally a “pseudo-hypopyon” of malignant cells will form, but the eye will be otherwise quiet and non-inflamed.
- Red reflex may be impaired.

### Slit lamp signs

- Anterior segment reaction can vary from quiet to hypopyon, but usually other signs of inflammation such as redness are absent.
- Vitritis is the most consistent feature, present in >90%.
- Subretinal infiltrates or masses can occur.

### Immediate management

- The main challenge is confirming the diagnosis. Vitreous biopsy is required, and sometimes needs to be repeated to clinch diagnosis.
- MRI brain and lumbar puncture are also required for staging.



Subretinal infiltrate seen in masquerade syndrome.

### Long-term management

- Managed with the oncologists. The usual regimen is intravenous or intrathecal Methotrexate. Intravitreal Methotrexate can be considered for isolated ocular lymphoma.

### Referral guidelines

Increasing floaters and blur. Any uveitis diagnosed for the first time in a patient aged over 60 years that does not have another clear cause.

## 12.13 Vogt Koyanagi Harada Disease

An autoimmune disorder thought to be caused by development of antibodies targeted against melanocytes, predominantly occurring in Asians and “pigmented” races. The ocular manifestations are bilateral granulomatous panuveitis.

Skin, auditory and central nervous system manifestations can also occur.

### Symptoms

- Blur: relatively sudden onset, can be severe.
- Eye pain/ache.
- Photophobia.
- Headache and neck stiffness.
- Tinnitus and reduced hearing.

### Signs

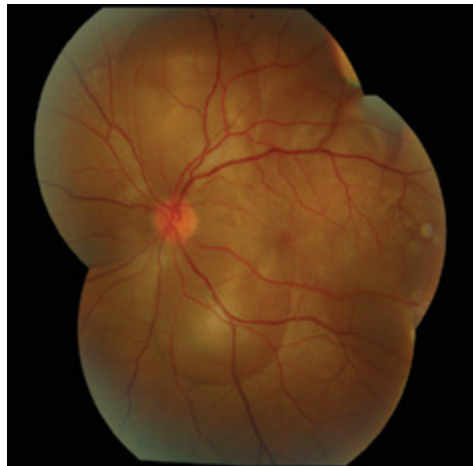
- Redness.
- Decreased visual acuity.
- Distorted pupil from posterior synechiae.
- Reduced red reflex if significant vitritis.
- Late systemic signs: vitiligo, poliosis and alopecia may develop (more common in undertreated disease).

### Slit lamp signs

- Redness.
- Cornea: keratic precipitates (usually large/“mutton fat”).
- Posterior synechiae.
- Vitritis.
- Dilated exam: multifocal exudative retinal detachments.

### Immediate management

- Exclusion of other conditions that can mimic VKH, e.g. tuberculosis, syphilis.
- Admission for intravenous methylprednisolone, or start high



Multiple areas of serous retinal detachment with subretinal fluid in VKH.



dose oral prednisone. Prognosis is more favourable if treatment is initiated within 2 weeks of onset of symptoms.

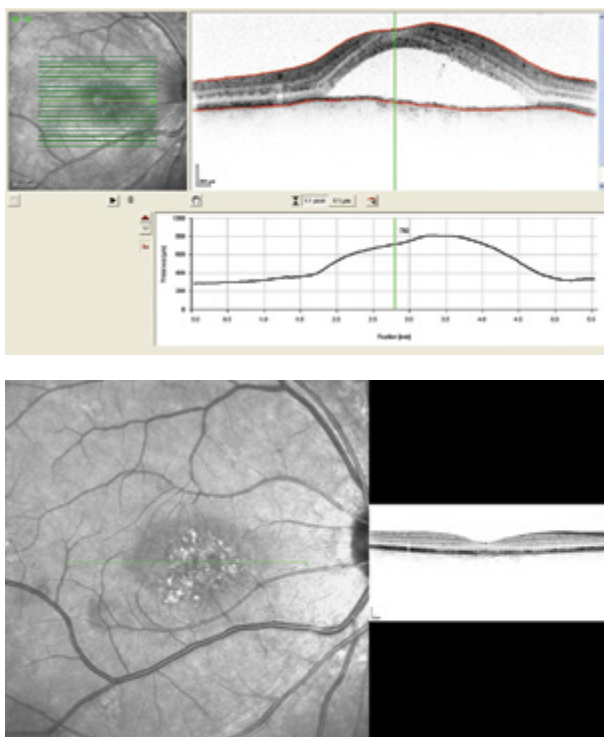
- Topical Pred Forte and cycloplegics to treat anterior segment inflammation.

### Long-term management

- Minimum of 6 months of systemic immunosuppression is required, and many patients require longer treatment. Some patients will require a second immunosuppressant (e.g. azathioprine or cyclosporine A).
- Chronic disease course with recurrent anterior uveitis and vitritis will develop in same patients

### Referral guidelines

Any patient with sudden reduced vision, eye pain, floaters, or visual changes in context of new onset headache.



OCT demonstrating subretinal fluid in Vogt-Koyanagi-Harada (VKH) disease with the second scan showing resolution after treatment.

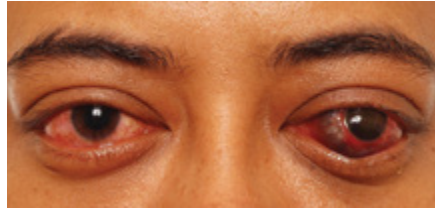## 12.14 Sympathetic Ophthalmia

An autoimmune form of uveitis developing after penetrating trauma to one eye. The immune system becomes exposed to uveal antigens usually sequestered in the eye, and mounts an immune response that attacks both eyes.

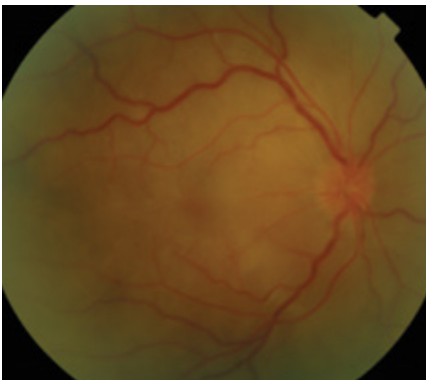
The non-traumatized eye is referred to as the “sympathising” eye. It can develop up to 20 years after penetrating trauma, but is most common within the first two years.

The most common cause of sympathetic ophthalmia traditionally has been accidental trauma, but with better management of ocular trauma the incidence is decreasing. It can also develop following iatrogenic trauma, particularly with repeated retinal surgical procedures.

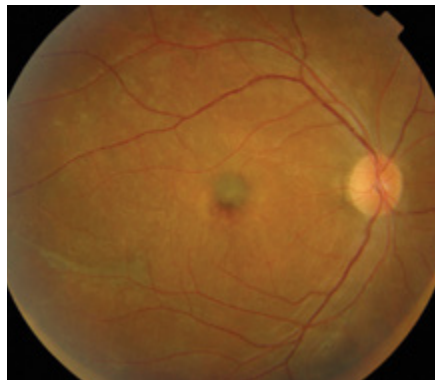Prognosis remains variable, with half of patients having permanent visual impairment despite systemic immunosuppression.



Bilateral inflamed eyes with original injury to left eye (inciting eye)..



Areas of pallor with choroiditis and subretinal fluid in sympathetic ophthalmia.



Improved after systemic steroid or immune modulation.

## Symptoms

- Redness.
- Blur.
- Aching pain.
- Photophobia.
- Floaters.
- History of previous penetrating trauma, including vitreoretinal surgery.

## Signs

- Bilateral involvement (or fellow eye enucleated or blind).
- Redness.
- Reduced visual acuity.
- Irregular pupil (posterior synechiae).
- Impaired red reflex.

## Slit lamp signs

- Redness.
- **Cornea:** keratic precipitates (typically large/granulomatous).
- Anterior chamber cells and flare.
- Posterior synechiae.
- Vitritis.
- **Fundus (dilated examination):** multifocal choroiditis, multifocal serous retinal detachments.

## Immediate management

- **Systemic steroids:** high dose oral, or intravenous methylprednisolone.

## Long-term management

Most require second-line agents, as course is typically chronic with high potential for complications including glaucoma, cataract, and chorioretinal scar.

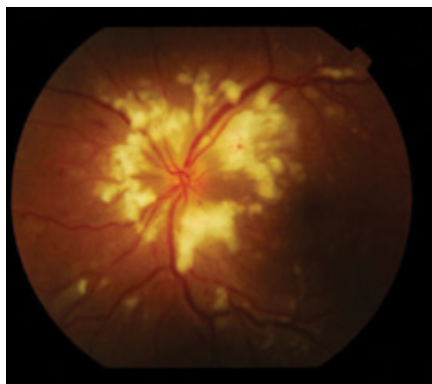
## Referral guidelines

Any patient with history of penetrating eye trauma or vitreoretinal surgery, who presents with bilateral redness, eye pain or blur should be evaluated for sympathetic ophthalmia.

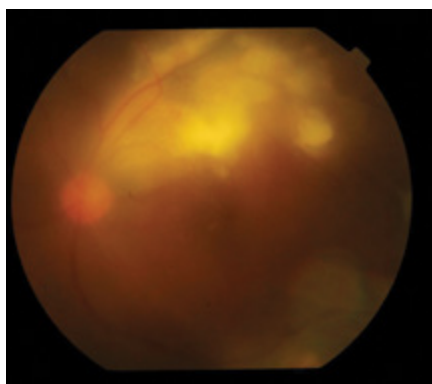
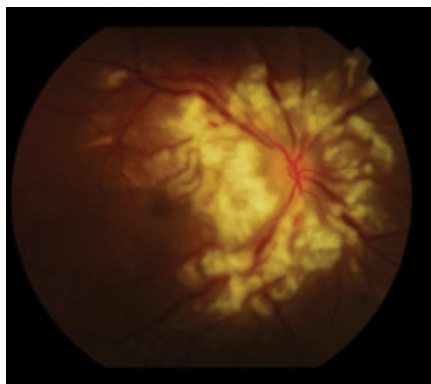
## 12.15 Uveitis in an Immunocompromised Patient

Uveitis occurring in patients with immunocompromise from any cause, including HIV/AIDs, can provide a diagnostic dilemma.

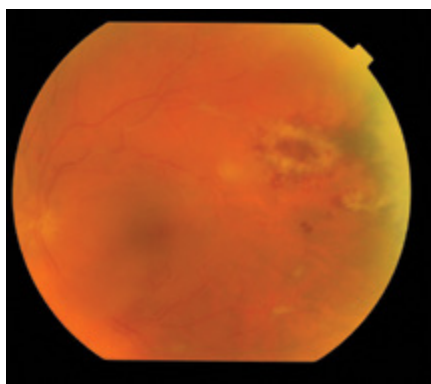
Symptoms and signs are not always typical as the patient cannot mount the usual immune response. There is also an increased risk of serious sight-threatening infections, in particular cytomegalovirus, and of “masquerade” syndromes such as lymphoma.



Pale patches of chorioretinitis in *Mycobacterium avium* in a patient with HIV.



luffy white patches on the retina represent areas of cryptococcal infection.



## Symptoms

- Symptoms depend on the degree of immune-compromise. In a profoundly immune suppressed individual, the first sign may be irreversible visual loss from retinitis. In less compromised patients the presentation will be more typical, with pain and floaters.
- Mild redness, photophobia, or discomfort and floaters may be present.

## Signs

- Possible redness.
- Possible misshapen pupil from posterior synechiae.
- Red reflex may be impaired.

## Slit lamp signs

- Anterior chamber cells (may be mild).
- Vitritis (may be mild).
- Retinitis is a common feature of infectious uveitis, and usually appears as creamy white lesions, often with haemorrhagic areas or vasculitis uni- or multifocal.

## Immediate management

- Initial management is geared towards pinpointing the precise aetiology. This may involve biopsy from either anterior chamber fluid, or a vitreous biopsy.
- Infectious uveitis requires specific antiviral or antimicrobial therapy and careful monitoring.

## Long-term management

Dependent on underlying aetiology, and also on the degree and duration of immune compromise. If immune reconstitution is not possible, some patients will require indefinite treatment.

## Referral guidelines

Refer any immunocompromised patient with suspected uveitis, or subacute blurring of vision, for prompt assessment.



## 13 *Retina*

## 13.1 Posterior Vitreous Detachment (PVD)

A physiological age-related phenomenon where the vitreous gel in the eye undergoes collapse. In New Zealand this occurs in about 40% of individuals by the age of 60 years. The incidence is greater following intraocular surgery such as [Cataract Surgery](#) and in patients who are myopic (short-sighted).

The risk for patients with a symptomatic PVD is the development of a retinal tear, a precursor for a retinal detachment. The risk of developing a retinal tear in a patient with a symptomatic PVD is 15%.

The precipitating events are poorly understood but involve a collapse of the vitreous gel, which culminates in a separation of the vitreous from the retina. As the gel separates, liquid vitreous replaces the deficit so no structural abnormality occurs to the eye. In some eyes the vitreous has an abnormal adhesion to the retina and the PVD will result in a retinal break and increase the risk of a retinal detachment.

### Symptoms

- New onset of flashes and floaters. The risk of a retinal tear is greater if the patient visualises >10 floaters.

### Signs

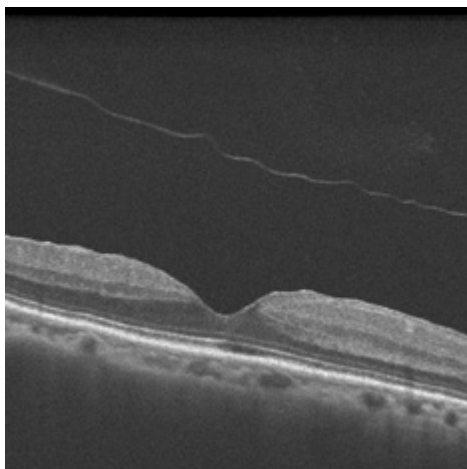
- None – slit lamp required.

### Slit lamp signs

- A third of patients have a Weiss ring in the vitreous cavity (ring shaped floater in front of the optic disc), which is pathognomonic of a PVD.
- Blood or pigment in the vitreous cavity.
- Sometimes optic nerve head haemorrhage.

### Immediate management

- Ideally all symptomatic patients should be seen within 48 hours.
- Patient requires a dilated retinal examination to exclude a retinal break and/or retinal detachment.



OCT demonstrating separation of the vitreous from the retina in a posterior vitreous detachment. The line above the retina is the posterior face of the vitreous.

### **Long-term management**

Usually none apart from education. 95% retinal tears occur at the time of the PVD and patient need not be reviewed unless vision worsens or symptoms persist.

### **Referral guidelines**

Ideally all newly symptomatic patients should be seen within 48 hours.



## 13.2 Retinal Breaks

Also known as retinal tears or holes. A retinal break typically develops because of abnormal traction on the retina that occurs during or following a posterior vitreous detachment (PVD).

The discovery of a retinal break requires an assessment to determine the likelihood of progression to a retinal detachment. When indicated most retinal breaks are secured with laser photocoagulation, the method of delivery being determined by position and size of the break, and clarity of the ocular media.

### Symptoms

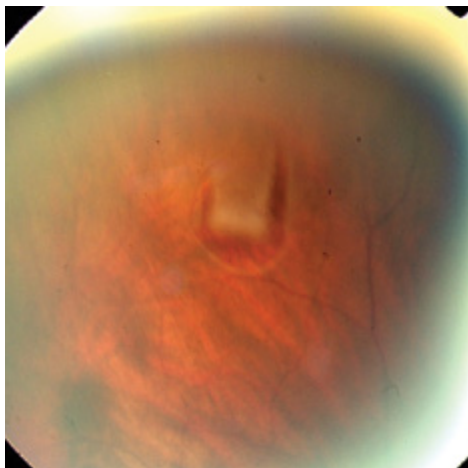
It is not usually possible from history alone to discriminate between a posterior vitreous detachment and a retinal break or even an early retinal detachment. All three pathologies can present with flashes and floaters. However patients reporting dot-like floaters numbering more than 10 are more likely to have a retinal tear.

### Signs

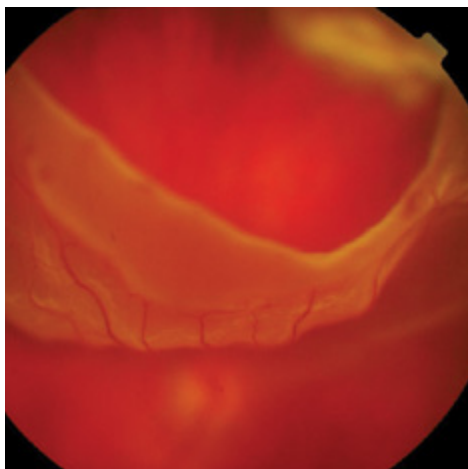
- None – slit lamp required

### Slit lamp signs

- Signs of a posterior vitreous detachment.
- Sometimes pigment or blood in the vitreous cavity.
- Retinal break or tear.



Horse-shoe-shaped retinal tear.



Giant retinal tear.

### **Immediate management**

The ophthalmologist would usually treat the retinal break with either laser or cryotherapy to seal the break.

### **Long-term management**

Once the lesion is successfully treated the patient can be discharged from routine surveillance with instructions to report any similar problem in the future.

### **Referral guidelines**

Urgent referral to a retinal specialist if patient has sudden onset of flashes or floaters in the vision.

## 13.3 Rhegmatogenous Retinal Detachment

The generic term “retinal detachment” refers to a separation of the retina from the retinal pigment epithelium. Rhegmatogenous retinal detachment (RRD) is when that separation occurs as a consequence of a retinal break, usually with the configuration of a tear.

In the Auckland region RRDs occur at the rate of 11 per 100,000 per year. The risk is greater in individuals who are myopic or who have had [Cataract Surgery](#). There is a slight gender difference with men being more at risk in their late 60s, while for women the incidence is higher earlier in that decade.

### Symptoms

- Most patients presenting with RRD report a combination of symptoms including flashes and floaters, loss of vision and/or a shadow in the vision.

### Signs

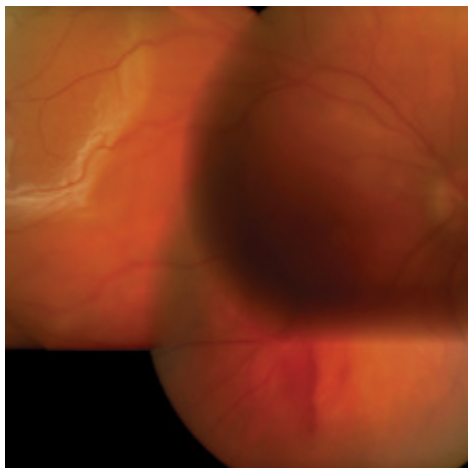
- Reduced vision if the macula is involved. A peripheral field defect is usually apparent with confrontational field testing.
- May have abnormal red reflex.

### Slit lamp signs

- Red blood cells and pigment may be seen in the vitreous. The detachment can be seen with a fundal lens.

### Immediate management

The treatment is always surgical and there are a number of recognised options for repairing retinal detachments, including intraocular gas injections, scleral buckling and vitrectomy. The approach depends on a number of factors including number of retinal breaks, the extent of detachment and the presence of co-morbidities. Surgical success depends on ensuring the retinal break(s) are permanently closed by either cryotherapy or laser retinopexy.



Peripheral rhegmatogenous retinal detachment with retinal break.

### Long-term management

In New Zealand the risk of a RRD developing in the fellow eye approximates 10% and so education is important part of patient management.

### Referral guidelines

The best results occur when surgery is performed before the macula is detached and hence urgent referral is warranted if there is a clinical suspicion of a retinal detachment or retinal break.

## 13.4 Other Types of Retinal Detachment

The two other types of retinal detachment are traction retinal detachment and serous retinal detachment.

In traction retinal detachment the retina is pulled off the wall of the eye by scar tissue. This is most common in advanced diabetic retinopathy, in which proliferating new vessels at the posterior pole can contract causing loss of central vision. Other important causes include retinopathy of prematurity (ROP), trauma, and proliferative vitreoretinopathy (PVR) after retinal detachment repair.

Serous retinal detachment is caused by fluid developing under the retina rather than entering through a break. There are dozens of possible causes of serous detachment but the most important are inflammatory (including infection), and neoplastic. Central Serous Retinopathy is a localised form of serous detachment.

### Symptoms

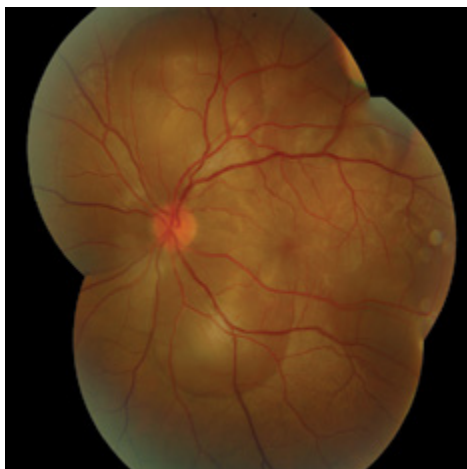- Loss of vision, floaters, flashing lights.

### Slit lamp signs

- Traction retinal detachment is usually localised and concave in appearance. It is typically in the posterior pole in diabetics, temporally in ROP, inferiorly in PVR and at the site of injury in trauma. In the absence of a secondary retinal break the detachment usually progresses slowly.
- Serous detachment can be small and localised with a convex shape, or the retina can be entirely detached. The hallmark of larger serous detachments is that the subretinal fluid shifts with postural change to the dependent part of the eye. There may be associated signs such as a subretinal mass, inflammation of the retinal vasculature, retinal exudates or optic nerve abnormalities.

### Immediate management

If there is vision loss, the patient should be referred urgently. Patients with less severe symptoms should also be referred promptly.



Pale areas indicate multiple areas of serous retinal detachment.

### Long-term management

Traction retinal detachment usually requires surgery. This is more urgent when the central vision is involved, or when there is a retinal break in addition to the traction. Serous retinal detachment requires diagnosis of the underlying condition followed by appropriate management.

### Referral guidelines

Surgery will be required for traction retinal detachment, and prompt specialist referral is indicated. Serous retinal detachment is often managed medically, but specialist care is also required.

## 13.5 Epiretinal Membranes (ERM)

Epiretinal membranes are a common finding occurring in about 4% of adults over the age of 40.

### Symptoms

- Many patients are asymptomatic.
- Those that are symptomatic typically report distortion and/or blurred central vision.

### Slit lamp signs

An epiretinal membrane looks like a piece of cellophane has been applied to the surface of the retina. In some progressive cases the retina becomes wrinkled if the membrane contracts.

### Immediate management

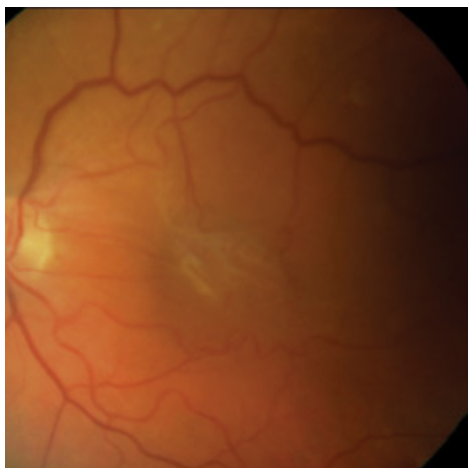
Observation with photography and retinal scan (optical coherence tomography – OCT) as a baseline recording.

### Long-term management

Observation unless central vision is threatened or compromised in which case vitreo-retinal surgery is indicated. The standard approach is small gauge vitrectomy, usually performed as day case surgery under local anaesthesia. Following removal of the vitreous the ERM is typically stained with a dye and then removed from the surface of the retina. The vision typically improves within six weeks of surgery, paralleling the reduction in distortion of the retina.

### Referral guidelines

- Non-urgent referral to a vitreo-retinal surgeon.



Epiretinal membrane causing retinal distortion.

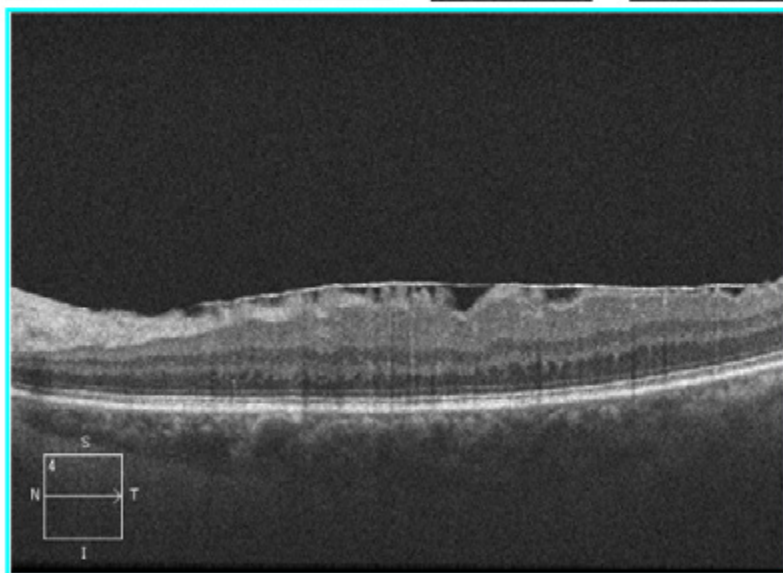
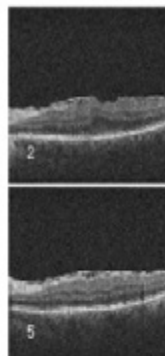
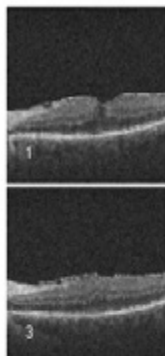
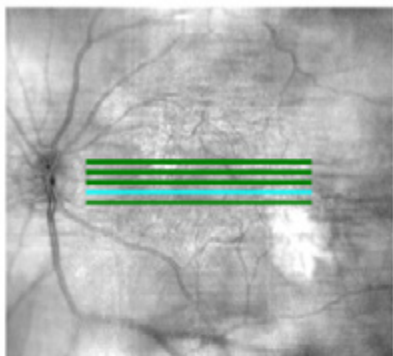
# High Definition Images: HD 5 Line Raster

OD ☐ OS ☒

Scan Angle: 0°

Spacing: 0.25 mm

Length: 6 mm



Comments

Doctor's Signature

SW Ver. 5.1.1.6  
Copyright 2010  
Carl Zeiss Meditec, Inc.  
All Rights Reserved  
Page 1 of 1

OCT of Epiretinal Membrane. Note the irregular contour of the surface of the retina with bright white line of membrane causing the distortion.



## 13.6 Macular Hole

A full-thickness defect in the retina at the central macular – fovea – causing central visual loss.

In fact the circular deficit does not represent loss of retinal tissue but more of a vertical separation through the central retina. As such closure of this defect can restore central vision.

### Symptoms

- Central loss of vision in one eye.
- Distortion of central vision in one eye.

### Signs

- Reduced vision in one eye.

### Slit lamp signs

- Normal ocular exam except for central hole in retina.
- The presence of the macular hole is best confirmed by Ocular Coherence Tomography (OCT), which gives cross sectional pictures of the central retina.

### Immediate management

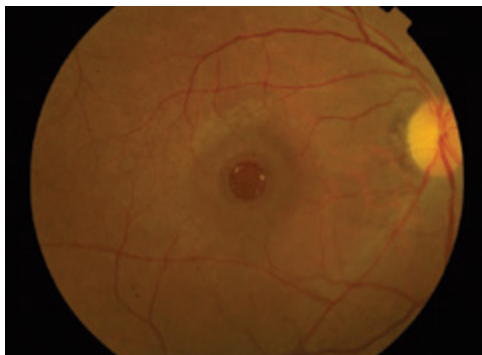
The management is surgical and involves vitrectomy surgery with membrane peel and gas tamponade. Post operatively the patient is usually asked to posture face down for a period of time to improve the chance of surgical success.

### Long-term management

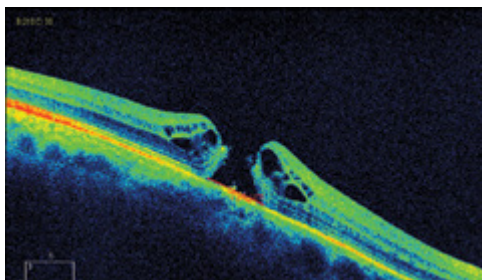
Once the hole is successfully closed (surgery has about 90% success rate for closure) the patient can be discharged from ophthalmic care. Surgery frequently induces a cataract that may need to be addressed within a year of two of the macular hole repair.

### Referral Guidelines

Early referral (non-urgent) is best as prognosis is dependant on the duration of the defect.



Large macular hole.



OCT with macular hole and surrounding cuff of intraretinal fluid (dark spaces within the coloured retina).

## 13.7 Retinoschisis

This is a splitting of the layers of the retina that can arise as the result of a rare X-linked inherited disorder typically involving the macula.

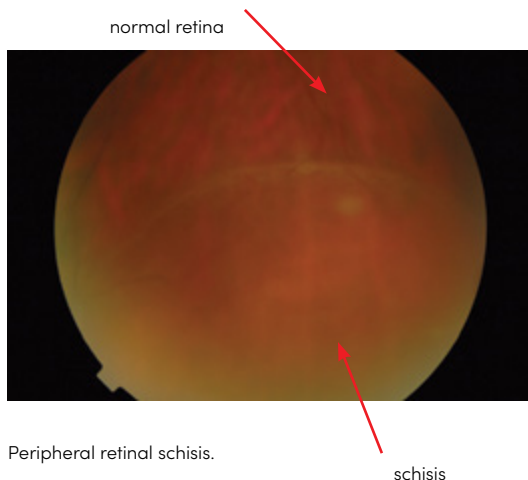
Alternatively retinoschisis may present as part of a syndrome associated with hypermetropia. Typically this form is benign and is usually limited to the peripheral retina.

### Symptoms

Mostly asymptomatic, with a minority of patients aware of a peripheral field defect.

### Signs

Reduced vision is common in patients with X-linked retinoschisis and at the macula a cartwheel-like appearance may be seen. Peripheral retinoschisis may mimic a retinal detachment with a bullous like appearance to the retina.



### Slit lamp signs

A lens is required to see the changes in the retina.

### Immediate management

Depends on the ease of differentiating between retinal detachment and retinoschisis. If in doubt patient should have urgent referral.

### Long-term management

Observation and education to the patient about symptoms of progression and retinal detachment.

All patients need to be aware of the low risk of developing a retinal detachment and or extension of the defect to involve the macula.

### Referral guidelines

Non-urgent referral to a retinal specialist.

## 13.8 Surgical Techniques

### Retinopexy

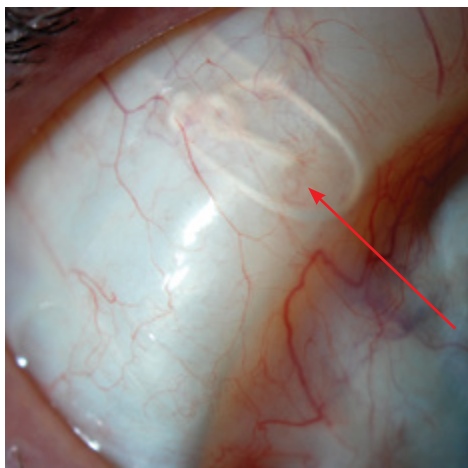Retinopexy refers to the surgical technique of sealing retinal breaks by either laser or cryotherapy. Both treatment options cause a chorio-retinal adhesion by inducing an inflammatory reaction to the area treated.

### Laser photocoagulation

Laser photocoagulation can be delivered by either a slit lamp approach or via the indirect ophthalmoscope. Both delivery systems are useful under certain scenarios and the choice depends on position of the retinal break, size and clarity of the ocular media as well as personal preference of the surgeon. Cryotherapy is useful in the operating theatre as the patient often requires local anaesthetic for this form of retinopexy.

### Scleral buckling

Scleral buckling is a method of reattaching the retina, sometimes called conventional treatment. The goal of retinal reattachment surgery is to facilitate the subretinal fluid to be absorption, create a chorio-retinal adhesion and ensure there is no residual traction on the retinal break. The placement of a scleral buckle usually ensures the traction is relieved and providing the other two conditions are met the retina will be successfully reattached. The technique of scleral buckling involves correct placement of the buckle, which may be a sponge like material or a solid silicone element. This buckle is sutured to the sclera underneath the conjunctiva and serves to “indent” the sclera, thus pressing it towards the retina. There are many different sizes and shapes of buckles reflecting the different pathologies encountered. Scleral buckling is less popular in New Zealand now than 20 years ago, reflecting a worldwide trend to perform less invasive surgery and arguably vitrectomy has a more pre-eminent role in retinal surgery.



Suture and scleral buckle.

## 13.9 Vitrectomy

This surgical procedure removes the vitreous for therapeutic or diagnostic purposes. The latter may also be termed a vitreous biopsy.

Therapeutic vitrectomy may be indicated for a wide range of posterior segment pathologies including retinal detachment, macular hole, epiretinal membrane as well as vitreous opacities, such as blood and debris. Most anterior segment indications for vitrectomy are related to complications of [Cataract Surgery](#).

### Anaesthesia

Most vitrectomies are performed as day case procedures with regional anaesthesia. If the vitrectomy is combined with other procedures such as corneal graft or scleral buckling the patient might need a general anaesthetic.

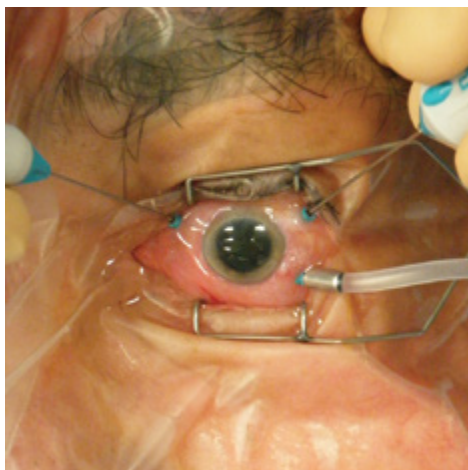### Surgery

Three incisions are made through the sclera behind the iris and lens and anterior to the retina. One port – the infusion line – allows solution to replace fluid removed from the eye and maintains the intraocular pressure. One port is used to introduce a light pipe to enable visualisation and the third port is for instrumentation such as the vitrector.

The incisions may range in size from 20 gauge (0.9 mm) to 25 gauge (0.49 mm). The small incisions are often self-sealing.

Post-operatively the patient may have oil or gas in their eye and be asked to posture. The oil or gas is a tamponade to the retina and holds it in place as required. By moving the head the gas or oil floats to the upper most level and the site of the tamponade can be varied.

The eye is usually inflamed for a week or two post-operatively and requires antibiotic drops and anti-inflammatory drops like a topical steroid for up to 4 weeks.

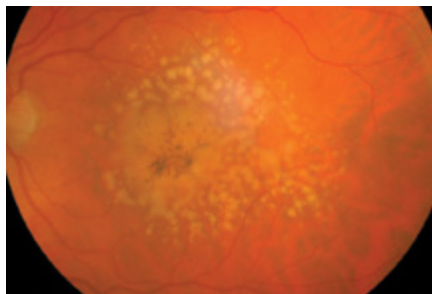


Three-port pars plana vitrectomy with an infusion line inferiorly and two instruments – usually a light pipe and a vitrector in the superior ports. The wounds pass 3.5–4mm behind the cornea.

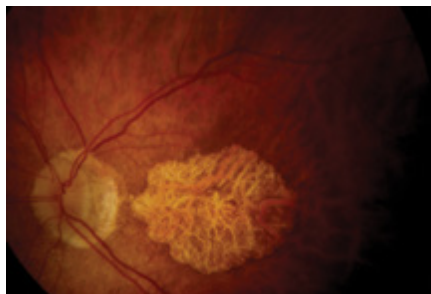
## 13.10 Age-Related Macular Degeneration (AMD)

This is the leading cause of irreversible severe visual loss in the Western world in people over 60 years. The prevalence increases with age. The two main types are:

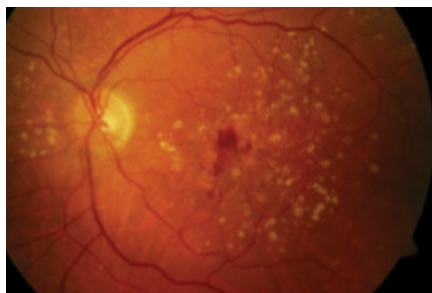
- Dry or atrophic (non-exudative) AMD – a slowly progressive disease which accounts for 90% of cases.
- Wet or exudative AMD – a more aggressive condition with detachment of the retinal pigment epithelium (RPE) and choroidal neo-vascularisation (CNV), which untreated leads to a scar over the macula area.



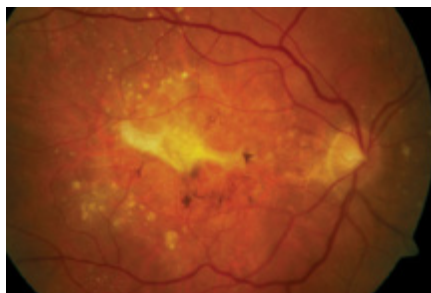
Drusen and pigment change in dry age-related macular degeneration.



Central geographic atrophy in dry AMD.



Central haemorrhage and drusen in active wet AMD, indicating untreated choroidal neovascular membrane.



Central fibrotic scar as well as pigment change and drusen in end-stage wet age-related macular degeneration.

## Symptoms

### Atrophic AMD.

- Gradual loss of central vision.
- Amsler grid changes, may be asymptomatic.

### Exudative AMD.

- Distortion of straight lines or edges.
- Rapid onset of visual loss.
- Central or paracentral scotoma.

## Signs

- Reduced vision.
- Otherwise need slit lamp.

## Slit lamp signs

- Atrophic AMD – macular drusen (pale/yellow spots in the macular area), pigment clumping, RPE atrophy leading to geographic atrophy (large pale areas).
- Exudative AMD – drusen accompanied by RPE detachment or CNV, subretinal haemorrhages (minimal or extensive), subretinal lipid exudates (yellowish deposits), subretinal fibrosis (disciform scar), retinal or vitreous haemorrhage.

## Immediate management

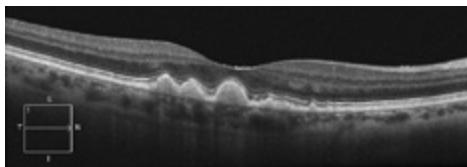
- Refer within 48 hours if exudative AMD suspected. Further investigation with fluorescein angiography (FFA) and OCT is required to plan treatment.
- Treatment for active, exudative AMD is with intravitreal anti-VEGF therapy – e.g. Avastin, Lucentis.
- Injections are given 4-weekly until vision and OCT appearance have stabilised.

## Long-term management

- Patients are monitored until stable.
- Patients should self-monitor regularly with an Amsler grid as reactivation of the CNV can occur.
- Those with high-risk drusen and/or active disease in the other eye can take vitamin/mineral supplements as recommended by contemporary randomised control studies. There is good evidence that blood pressure control and stopping smoking is important in mitigating disease progression. [Cataract Surgery](#) does not adversely influence the progression of the disease.

## Referral guidelines

- Refer within 48 hours if exudative AMD suspected.



OCT demonstrating subretinal drusen under the fovea in dry AMD.

## 13.11 Diabetic Retinopathy

Diabetic retinopathy (DR) is a microangiopathy affecting the retinal arterioles, capillaries and venules. Larger vessels may also be involved. Retinopathy has features of microvascular occlusion and leakage.

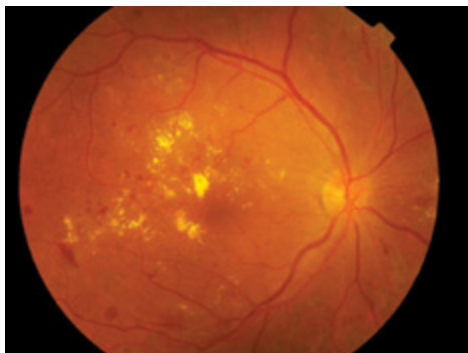
Risk factors for developing DR are duration of diabetes, poor metabolic control, uncontrolled hypertension and dyslipidaemia and other factors such as pregnancy, renal disease, obesity and smoking.

### Symptoms

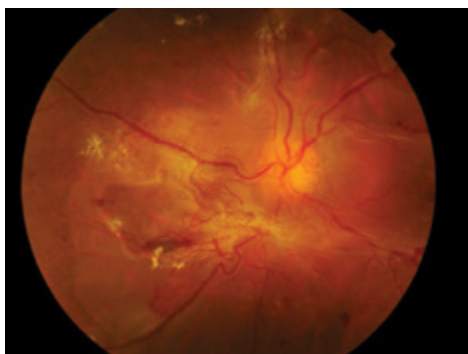
- Vision may be unaffected until sudden reduction due to vitreous haemorrhage or severe maculopathy. This highlights the importance of retinal screening.

### Signs

- Mild nonproliferative diabetic retinopathy (NPDR) – dot and blot haemorrhages, microaneurysms (tiny red dots) and hard exudates (yellowish deposits).
- Moderate NPDR – same as mild NPDR plus cotton-wool spots (fluffy white lesions), venous beading and loops and some capillary closure.
- Severe NPDR – same as moderate NPDR plus four quadrants of intraretinal haemorrhages, or two quadrants of venous beading, or one quadrant of intraretinal microvascular abnormalities (IRMA).
- Proliferative diabetic retinopathy (PDR) – findings above plus neovascularisation on the optic disc (NVD), neovascularisation elsewhere (NVE), or neovascularisation of the iris (NVI). Complications such as



Exudate and haemorrhages in diabetic maculopathy.



Proliferative diabetic retinopathy with haemorrhage, tractional detachment, exudate and fibrosis.

vitreous haemorrhage, fibrovascular tissue formation and traction retinal detachment may occur.

- Maculopathy can be present at any stage of retinopathy. It can be exudative, ischaemic or a combination.

### **Immediate management**

- Refer within 1 week if maculopathy or neovascularisation is present.
- Laser treatment may be required for maculopathy or peripherally for neovascularisation.
- Intravitreal anti-VEGF agents may be needed for central oedema and for NVI.

### **Long-term management**

- Ensure all diabetics are screened regularly for retinopathy.
- Patients should optimise glycaemic control, blood pressure and hyperlipidaemia.

### **Referral guidelines**

- Refer within 1 week if maculopathy or neo-vascularisation is present.



## 13.12 Retinal Artery Occlusion

This is a blockage in either the central retinal artery or a branch artery causing widespread retinal ischaemia and loss of vision. Caused by emboli (especially carotid or cardiac), thrombosis, giant cell arteritis, collagen-vascular disease and hypercoagulation disorders.

### Symptoms

- Unilateral, painless, acute loss of vision (CF to PL) over a few seconds. Level of acuity is dependent on whether the macula is affected.
- May have a previous history of amaurosis fugax.
- Partial visual field loss if a branch artery is occluded.

### Signs

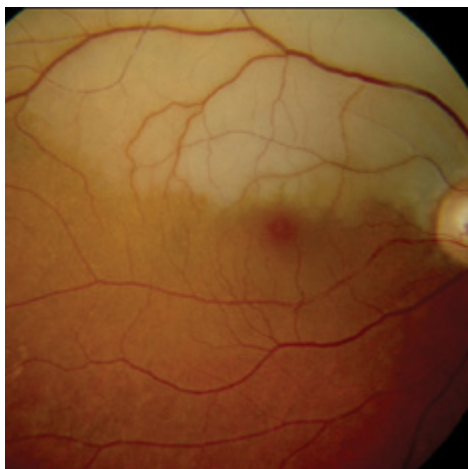
- Significantly reduced visual acuity.
- A small island of vision may remain if the cilioretinal artery serving the macula is still perfused.
- Relative afferent pupillary defect (RAPD).

### Slit lamp signs

- Superficial whitening of the retina due to intracellular oedema.
- “Cherry-red spot” in the centre of the macula.
- Narrowed retinal arterioles.
- Occasionally emboli are seen.

### Immediate management

- If presenting within 24 hours of the occlusion (i.e. sight loss) then refer to an ophthalmologist urgently.
- Treatment within the first 24 hours aims at dislodging the emboli by rapidly reducing



Pallor of the superior retina indicating a branch retinal artery occlusion.

the intraocular pressure either with ocular massage, medication or anterior chamber paracentesis.

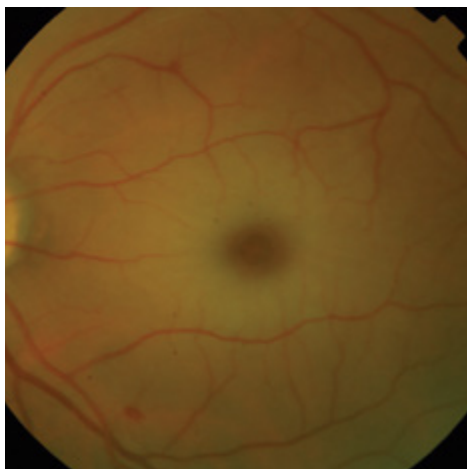
- Check ESR, CRP and platelets to rule out GCA if patient older than 50 years.
- Check atherosclerotic risk factors: BP, lipids.

### Long-term management

- Consider carotid doppler ultrasound and cardiac evaluation to look for source of emboli.
- An RAO is similar to a TIA or stroke and so patient may need to be referred to a TIA/stroke clinic or a physician for evaluation.
- The vision is unlikely to improve if it does not resolve within 24 hours.
- An ophthalmologist may arrange a fluorescein angiogram to confirm the diagnosis and will monitor for the next months to ensure rubeosis does not develop.

### Referral guidelines

Refer immediately if artery occlusion suspected.



Widespread pallor with central 'cherry-red' spot in a central retinal artery occlusion.

## 13.13 Branch Retinal Vein Occlusion (BRVO)

A branch vein is occluded by compression of the venous wall typically at an arterio-venous (AV) crossing and is thought to be related to an abnormality in the adjacent arterial wall. This may result from hypertension, arteriosclerosis or diabetes.

- Incidence increases with age (>50 years old)
- Main threats to vision are macular oedema and neo-vascularisation.

### Symptoms

- May be asymptomatic, particularly if not affecting the macula.
- Some have a relative visual field defect and others have blurred vision with distortion, or patches missing from their vision.

### Slit lamp signs

- Variably reduced visual acuity.
- Dilated and tortuous veins, superficial haemorrhages, retinal oedema and cotton-wool spots (fluffy white lesions) affecting the part of the retina drained by the obstructed vein.
- Hard exudates (yellowish deposits), vascular sheathing, collateral vessel formation.

### Immediate management

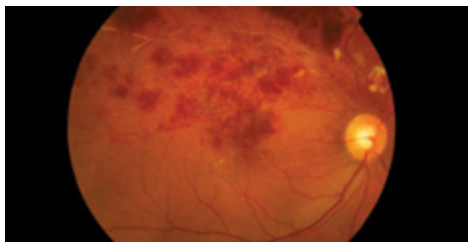
- Check blood pressure. Arrange fasting blood sugar and lipid profile, FBC and ESR.
- Refer for detailed ocular assessment. Fundus fluorescein angiography (FFA) may be useful to check for extent of ischaemia and to look for foveal involvement. Optical coherence tomography (OCT) is useful to screen for macular oedema.
- If vision is reduced due to macular oedema consider early treatment with the intravitreal anti-VEGF's. This may be combined with grid laser treatment.
- If neo-vascularisation is present sector pan-retinal photocoagulation (PRP) to the ischaemic area is performed.

### Long-term management

- Review every 1–2 months at first to monitor treatment or check for complications.

### Referral guidelines

- Refer within 48 hours if vision is reduced.



Sectorial blot and flame haemorrhages of a branch retinal vein occlusion.

## 13.14 Central Retinal Vein Occlusion (CRVO)

Often caused by atherosclerosis of the adjacent retinal artery which compresses the central retinal vein leading to occlusion. Risk factors include hypertension, glaucoma, optic disc drusen, hypercoagulable states, vasculitis, drugs like the oral contraceptive pill and diuretics, and with retrobulbar external compression.

Can be non-ischaemic (around 75%) or ischaemic which influences clinical features and prognosis.

### Symptoms

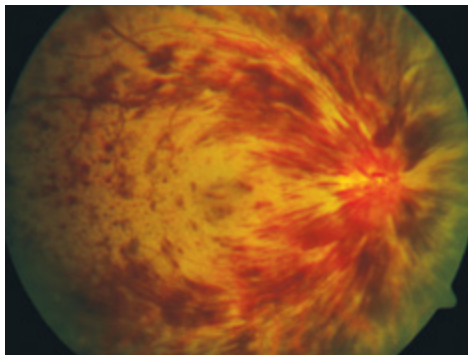
- Usually unilateral, sudden, painless loss of vision.

### Slit lamp signs

- **Non-ischaemic CRVO:** vision often better than 3/60, tortuosity and dilation of all retinal veins, mild to moderate intraretinal haemorrhages, few (if any) cotton-wool spots (fluffy white retinal lesions), mild to moderate optic disc swelling and macular oedema.
- **Ischaemic CRVO:** vision usually worse than 3/60, relative afferent pupillary defect (RAPD), extensive intraretinal haemorrhages, multiple cotton-wool spots, may have neo-vascularisation of the iris/optic nerve.
- Intraocular pressure may be elevated if related to glaucoma or as rubeotic glaucoma develops.

### Immediate management

- Urgent referral required for detailed ocular examination including gonioscopy.
- Blood pressure assessment.
- Blood tests – HbA1c and lipid profile, FBC, CRP. If patient <50 years consider thrombophilia screen.



Extensive blot and flame haemorrhages and swelling of the optic nerve in a central retinal vein occlusion.

### **The ophthalmologist will arrange:**

- Fluorescein angiography (FFA) helps to establish degree of ischaemia.
- Optical coherence tomography (OCT) to assess macular oedema.

### **Treatment:**

- Consider low-dose aspirin therapy.
- If macular oedema causing reduction in vision intravitreal anti-VEGF therapy (e.g. Avastin) is considered.
- If neo-vascularisation of the iris is present intravitreal anti-VEGF treatment is given and pan-retinal photocoagulation is performed.

### **Long-term management**

- Regular follow up is required particularly for the first 6 months so macular oedema and neo-vascularisation can be treated promptly.
- Monitoring for 2–3 years.

### **Referral guidelines**

- Urgent referral (under 48 hours) if vision is reduced.

## 13.15 Hypertensive Retinopathy

Systemic hypertension may cause retinal vascular damage, particularly retinal arteries and arterioles, causing progressive narrowing and atherosclerosis.

In sustained uncontrolled hypertension the blood-retinal barrier can be disrupted, resulting in increased vascular permeability. Hypertension is the most common underlying cause of retinal vein occlusions.

### Symptoms

- Usually asymptomatic.
- Severe cases may present with reduction in visual acuity.
- Malignant hypertension is a medical emergency, and these patients need to be referred to the emergency department for urgent blood pressure management.

### Signs

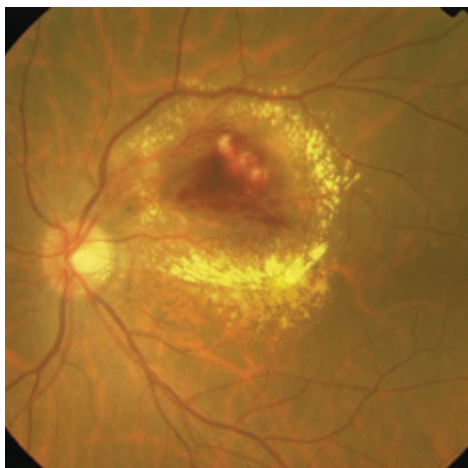
- Generalised or localised retinal arteriolar narrowing – mostly bilateral.

#### Chronic Hypertensive Retinopathy:

- Arterio-venous (AV) nicking.
- Copper or silver wiring of vessels.
- Cotton-wool spots.
- Flame-shaped haemorrhages.
- Central or branch occlusion of an artery or vein.
- Arterial macroaneurysms with or without associated haemorrhage.

#### Acute Hypertensive Retinopathy – associated with malignant hypertension

- Hard exudates often in a macular star.
- Retinal oedema.
- Disc swelling.
- Elschnig spots (clumps of pigment with surrounding red or yellow halo) indicate past episodes of acute hypertension.



A macroaneurysm with surrounding exudate.

### Immediate management

- Treatment is to control the blood pressure.
- No treatment needed for the eye in most cases unless neo-vascular complications arise.
- Urgency depends on the blood pressure reading and whether the patient is symptomatic.
- If diastolic pressure >110 mmHg with chest pain, headache or blurred vision refer immediately for treatment of malignant hypertension.

### Long-term management

- When the hypertension has been addressed arrange 2–3 monthly eye review until acute signs resolve. Eye signs resolve with treatment of hypertension unless a vascular occlusion has occurred.

### Referral guidelines

- Refer to a physician and request an ophthalmic assessment.
- If diastolic pressure >110 mmHg with chest pain, headache or blurred vision refer immediately.

## 13.16 Radiation Retinopathy

Radiation can cause a retinal microvasculopathy. It may develop following treatment of intraocular tumours with plaque therapy or following external beam radiation for orbital, sinus or nasopharyngeal malignancy.

The interval between radiotherapy and development of retinopathy is variable but mostly 6 months to 3 years.

### Symptoms

Decreased vision or distortion of vision.

### Slit lamp signs

#### Mild signs:

- Flame haemorrhages.
- Exudates.
- Telangiectasia.

#### Severe changes related to retinal ischaemia include:

- Arteriolar occlusion.
- Cotton-wool spots.
- Superficial and deep retinal haemorrhages.
- Optic nerve involvement.
- Proliferative retinopathy may develop in the long term.

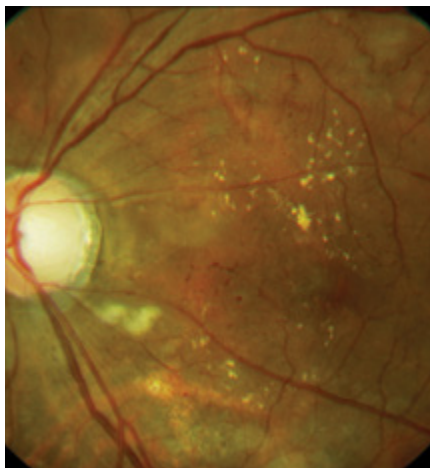
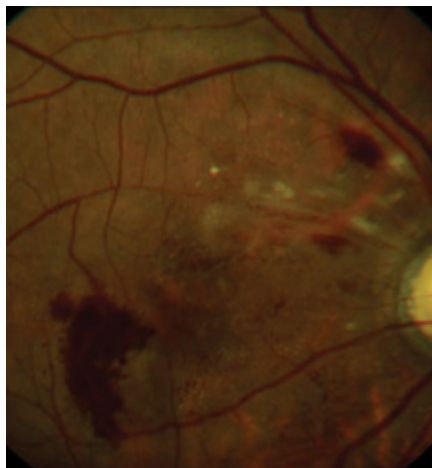
### Immediate management

- Referral to ophthalmology for confirmation of diagnosis with fluorescein angiography (FFA) and optical coherence tomography (OCT).
- Exclude other causes of vascular disease – measure blood pressure and blood sugar.

### Long-term management

- Possible temporary reduction in exudation with anti-VEGF therapy or intravitreal steroid
- Panretinal photocoagulation (PRP) may be required for proliferative retinopathy.
- Long-term follow-up required unless the eyes are stable following PRP.





Bilateral radiation retinopathy with cotton wool spots, exudate and haemorrhage.

### Referral guidelines

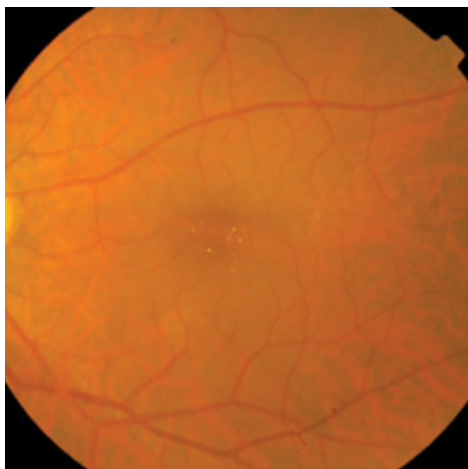
- Refer for further investigation if history is suggestive of radiation retinopathy.

## 13.17 Toxic Retinopathies

A variety of medications can cause toxicity to the retina, including anti-malarial drugs (Chloroquine and Hydroxychloroquine), phenothiazines (Thioridazine and Chlorpromazine), Quinine and some agents which cause a crystalline maculopathy – Tamoxifen, Canthaxanthin (an oral agent that enhances suntanning) and Methoxyflurane (an inhaled general anaesthetic agent).

### Symptoms

- Chloroquine/hydroxychloroquine – reduced vision, loss of visual field, decreased colour vision, reduced dark adaptation.
- Thioridazine – blurred vision, brownish vision, poor night vision, reduced visual field
- Chlorpromazine – blurred vision or asymptomatic, reduced visual field.
- Tamoxifen – reduction in vision though this is very rare.
- Quinine – visual loss.



Crystals deposited around the fovea in tamoxifen maculopathy.

## Signs

### Chloroquine/Hydroxychloroquine

- Bull's eye maculopathy (a ring of depigmentation surrounded by a ring of increased pigmentation).
- Loss of the foveal reflex.
- Paracentral scotoma.
- Abnormal electro-retinogram (ERG) and electro-oculargram (EOG).

### Thioridazine

- Pigment clumps between the posterior pole and the equator .
- Areas of depigmentation.
- Retinal oedema.
- Visual field abnormalities including constriction.
- Reduced or extinguished ERG.

### Chlorpromazine

- Peripheral deposits of clumps of pigment.
- Visual field constriction.
- ERG abnormalities.

### Tamoxifen

- Bilateral, multiple, superficial, yellow, crystalline, ring-like deposits at the macula.

### Canthaxanthin

- Tiny glistening yellow dots arranged symmetrically in a doughnut shape at the posterior pole of both eyes.

### Quinine

- An idiosyncratic response with fixed and dilated pupils and retinal oedema.

## Slit lamp signs

Some cases associated with vortex keratopathy but this is not an indication of toxicity.

## Immediate management

If toxicity is confirmed stop the treatment with appropriate medical supervision.

## Long-term management

Patients on long-term Chlorpromazine and Thioridazine should have 6-monthly follow-ups. Patients on Chloroquine should have an initial assessment at baseline and as they approach a total dose of 300g. Patients on Hydroxychloroquine should have a baseline assessment and further testing as they approach a total dose of 700g (usually about 5 years of treatment).

## Referral guidelines

Refer for ophthalmic assessment within 1 month if patient has visual symptoms.

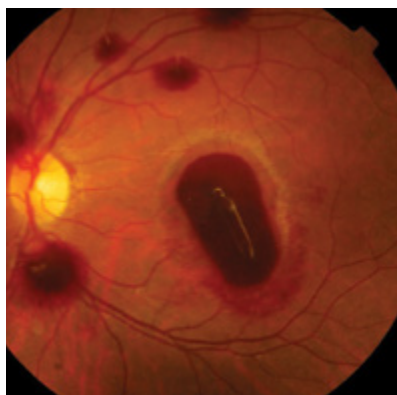
## 13.18 Haematological Disease and the Retina

The retina may be affected by a variety of haematological diseases, either due to vascular changes and ischaemia caused by the disease or by direct infiltration.

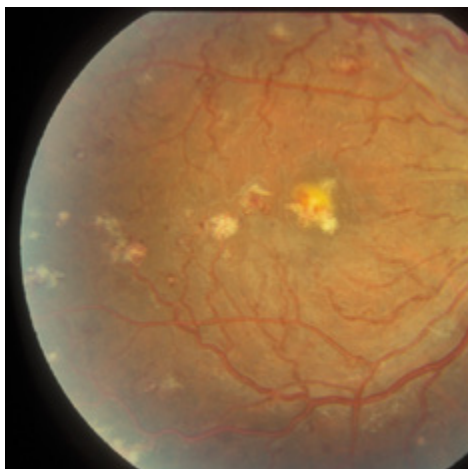
Diseases include anaemias, leukaemias and hyperviscosity states such as polycythaemia rubra vera, secondary polycythaemia, chronic leukaemias, Waldenstrom macroglobulinaemia and multiple myeloma.

### Symptoms

- Asymptomatic.
- Reduced vision if the macula or optic nerve are involved.



Multiple haemorrhages in acute leukaemia.



Creamy subretinal and intraretinal plaques in chronic myeloid leukaemia.

## Signs

### Anaemia

- Haemorrhages.
- Cotton-wool spots (areas of retinal ischaemia).
- Venous tortuosity.

### Leukaemia

- Haemorrhages.
- Cotton-wool spots.
- Venous tortuosity.
- Microaneurysms and neo-vascularisation.
- Pale areas of choroidal infiltration.
- Optic neuropathy and orbital involvement may also occur.

### Hyperviscosity states

- Venous dilatation, segmentation and tortuosity.
- Superficial and deep retinal haemorrhages.
- Cotton-wool spots.

## Immediate management

- Diagnosis and treatment of the underlying condition.
- Haematology referral.

## Long-term management

Eye signs will resolve as the disease enters remission.

## Referral guidelines

A person with a known haematological disease who develops visual symptoms should be referred within 2 weeks.

## 13.19 Cystoid Macular Oedema

This is the result of accumulation of fluid in the layers of the retina in the foveal region. Multiple cystoid spaces lead to increased retinal thickness.

Cystoid macular oedema (CMO) may occur following any type of ocular surgery. Incidence after *Cataract Surgery* increases with complications. It is also seen with diabetic retinopathy, vascular occlusion, uveitis, retinitis pigmentosa, and topical Prostaglandin inhibitors such as latanoprost.

### Symptoms

- Decreased vision.

### Slit lamp signs

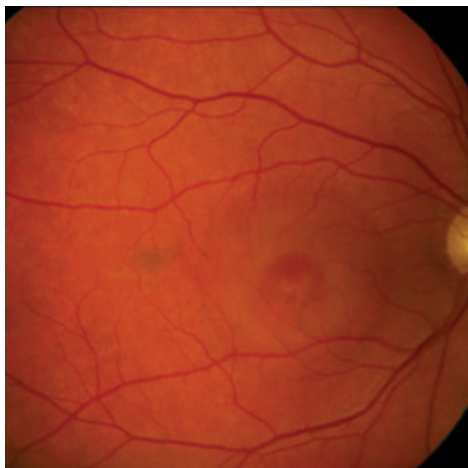
- Loss of the foveal depression, thickening of the retina and multiple cystoid spaces in the neurosensory retina

### Immediate management

- Confirm diagnosis with optical coherence tomography (OCT) and/or fundus fluorescein angiography (FFA).
- In post-surgical cases, treatment is with a topical non-steroidal anti-inflammatory and steroid eye drops 4 times a day. If there is no response after 6–8 weeks, periocular or intraocular steroid injection is considered.
- Stop drops if these are the cause of CMO developing.
- Diabetics may benefit from laser treatment or intravitreal anti-VEGF injections.

### Long-term management

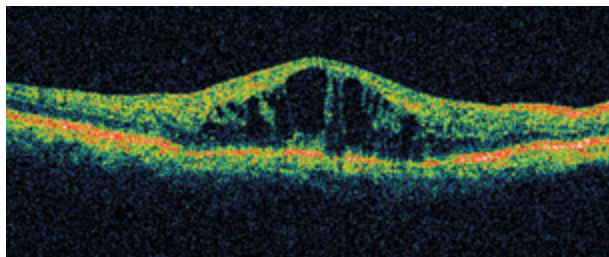
It is advisable to try and correct CMO within 4 months of onset as long-term presence of cystic change can lead to lamellar hole formation and irreversible damage to central vision. OCT is essential for monitoring response to treatment.



Loss of the normal foveal light reflex in cystoid macular oedema.

## Referral guidelines

Post-surgical CMO is not an emergency but other causes may require prompt action. Refer these within 2 weeks.



OCT of the foveal region with subretinal fluid and intraretinal cysts in CMO.

## 13.20 Central Serous Chorioretinopathy (CSR)

A localised serous detachment of the neurosensory retina in the macular area, which means a blister-like collection of fluid lies below the central retina, often under the fovea.

Idiopathic CSR usually occurs in males aged 25–50 years, often with a “type A” personality. It is typically a sporadic, self-limiting condition. It can be associated with exogenous steroid use (including nasal sprays and inhalers), and also with pregnancy. There is a 30–50% recurrence rate, becoming chronic in some cases.

### Symptoms

- Unilateral blurred or dim vision.
- Objects appear distorted or smaller.
- Colours may be washed out.
- Central blank spot.

### Signs

- Mild to moderate reduction in visual acuity.
- Distortion or a patch of blurring on Amsler grid.

### Slit lamp signs

- White eye.
- A localised elevation of the retina in the macular area.

### Immediate management

- Refer to ophthalmologist for confirmation of the diagnosis – usually with optical coherence tomography (OCT).
- 90% will resolve spontaneously within 12 weeks.

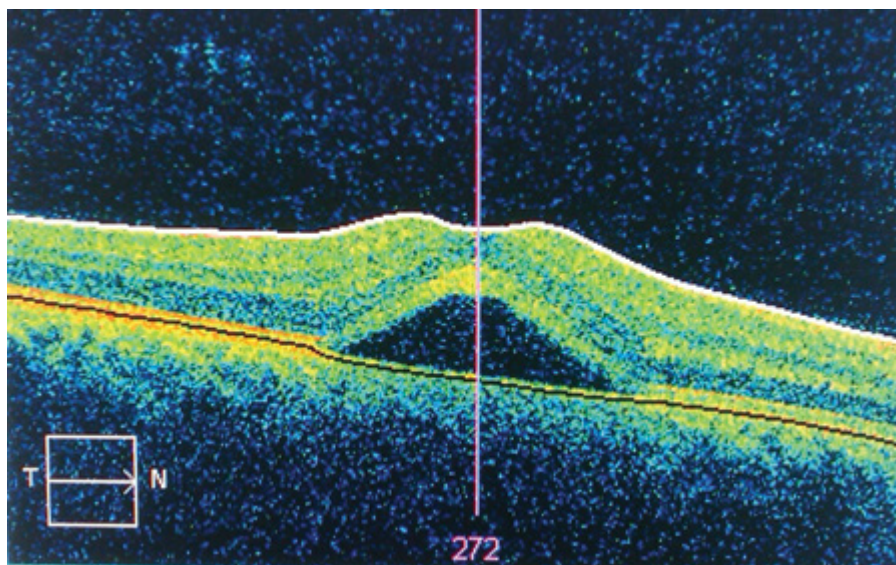
### Long-term management

- If CSR persists for longer than 3 months fundus fluorescein angiography (FFA) is required to assess suitability for treatment.
- Treatment with laser photocoagulation or reduced fluence photodynamic therapy (PDT) may be recommended.
- Vision may be permanently reduced especially in recurrent or chronic cases.
- Avoid exogenous steroids if these are responsible and try to reduce stress.

### Referral guidelines

- Refer within 1 week.





OCT showing sub retinal fluid in central serous chorioretinopathy (CSR)

## 13.21 Choroidal Folds

These are undulations or wrinkles in Bruch's membrane, RPE or the choroid.

### They can be caused by:

- External pressure such as in orbital disease, retrobulbar mass, thyroid ophthalmopathy or scleral buckling.
- Choroidal congestion such as with a choroidal tumour or in posterior scleritis.
- Low pressure within the globe.
- No apparent reason – idiopathic as seen in healthy hypermetropic patients.

### Symptoms

May be an asymptomatic finding or cause mild visual disturbance.

### Slit lamp signs

- IOP may be very low if folds are caused by hypotony.
- Retinal examination show lines or striae temporally in the posterior pole, most are parallel and horizontal but they can be vertical or oblique.

### Immediate management

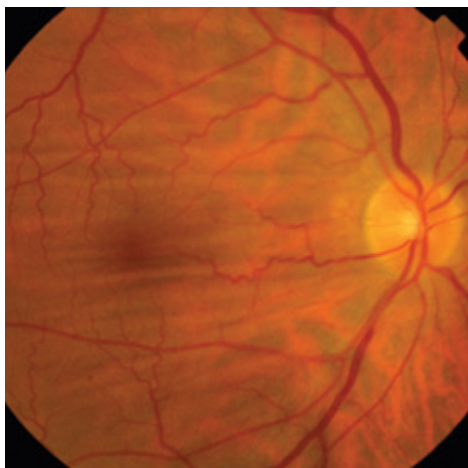
Referral required to exclude conditions requiring treatment. Choroidal folds can be confirmed with fundus fluorescein angiography (FFA). May need to arrange B-scan ultrasound to check for posterior scleritis and choroidal tumours, or CT scan or MRI for orbital disease.

### Long-term management

Folds will resolve if the cause is removed. If the cause is idiopathic or not treatable the folds will remain. There may be further permanent change in the RPE and sensory retina.

### Referral guidelines

- Refer within 2 weeks so further investigation can be arranged.



Corrugation of the retina indicating choroidal folds.

## 13.22 Degenerative Myopia

Progressive elongation of the globe leads to degenerative changes in the retina and choroid.

High level of myopia usually greater than minus-6 dioptries.

### Symptoms

- Decreased vision.
- Distortion.
- Reduction of visual field.

### Signs

Retinal examination can show patches of chorioretinal atrophy, a myopic crescent around the disc, tilted disc, macular pigmentary changes, lacquer cracks (yellow subretinal streaks), Forster-Fuchs' spot (a hyperpigmented spot at the macula), peripheral retinal thinning and lattice degeneration.

- There may be complications such as retinal detachment or choroidal neovascularisation.
- Visual field defects may be present.

### Immediate management

Fairly urgent referral required if the patient has noticed a reduction in vision, as the reason for reduced vision must be established. Choroidal neo-vascularisation may be treated with intravitreal anti-VEGF agents, retinal tears with retinal barrier laser treatment and retinal detachment with vitreoretinal surgery.

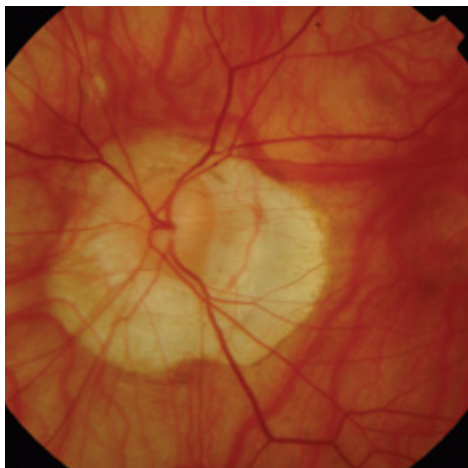
### Long-term management

- 6–12 monthly follow-up required to watch for complications.
- Wearing of polycarbonate safety glasses recommended for sport.

### Referral guidelines

Within 24 hours if retinal detachment suspected.

Within 48 hours for all other symptomatic patients.



Peripapillary atrophy and thinned pale retina in a highly myopic fundus

## 13.23 Retinal Dystrophies

Genetic eye disease is a leading cause of vision loss in children and adults but remains rare. There are hundreds of different types that can affect any part of the eye and can also affect other parts of the body for instance hearing loss in Usher syndrome. Some conditions can run in families but for many there is no family history. Vitally, across the world, extensive research is ongoing to find treatments for these disorders and an accurate diagnosis is the first step for future treatment trials.

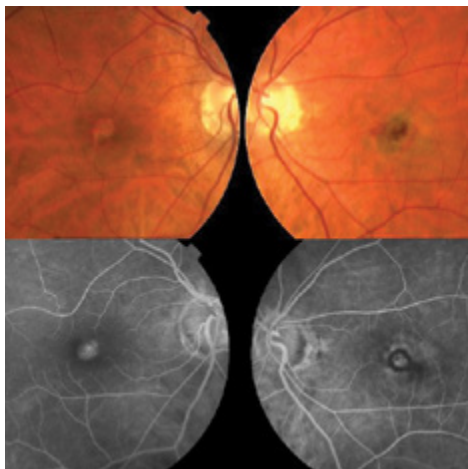
Retinal dystrophies include Leber congenital amaurosis, rod-cone dystrophy (retinitis pigmentosa), cone and cone-rod dystrophies, congenital stationary night blindness, achromatopsia, macular dystrophy and choroideraemia. Hereditary vitreoretinopathies include Stickler syndrome, familial exudative vitreoretinopathy and incontinentia pigmenti.

### Symptoms

- Leber congenital amaurosis presents in infancy with nystagmus and poor visual responses and patients may have light staring behaviour or photosensitivity, and an oculodigital reflex (eye poking behaviour).
- Rod-cone dystrophy can present at any age with nyctalopia then peripheral field loss with central vision disturbance later. Symptoms progress slowly.
- Cone-rod dystrophies present initially with reduced visual acuity and colour vision. The commonest form, Stargardt disease (from ABCA4 mutations) presents in childhood.
- Vitreoretinopathies may present with high myopia at a young age or even vision loss from detachment.

### Signs

- In rod-cone dystrophy early changes include subtle mid-peripheral retinal pigment epithelium (RPE) atrophy, with white dots at the level of the RPE and some cells in the anterior vitreous. Pigmentary changes develop later with classic 'bone spicule' change in the mid-peripheral retina, vessel attenuation and disc pallor. Patients develop cataract



Colour photos and fluorescein showing adult vitelliform dystrophy with bilateral yellowish lesion at the fovea with abnormal fluorescein uptake.

earlier than usual and may also have cystoid macular oedema as part of their condition (topical therapy may help).

- In cone-rod dystrophy, the changes start in the macula, with RPE and outer retinal atrophy and areas of increased autofluorescence.
- The commonest macular dystrophy, related to ABCA4 mutations, also known as Stargardt disease, presents with atrophic change and classically has pisciform flecks.
- Vitreoretinopathies may have abnormal vitreoretinal interface, telangiectasia, peripheral avascularity or exudate.

## Investigations

- Widefield fundus imaging and autofluorescence is a key imaging tool for identifying disease and monitoring for progression.
- OCT macula also typically finds thinning and loss of the ellipsoid zone in the outer macula which matches a ring of increased autofluorescence on the FAF.
- Genetic testing is routinely offered to more accurately understand the condition.

## Management

### Referral for specialist assessment has multiple benefits for patients:

- Prognosis
- Inheritance- this help families understand the risk for other family/future children
- Identify systemic associations
- Treatment- gene therapy for RPE65 related retinal dystrophy is now available worldwide and a large number of treatment trials are ongoing for many other genes. Without a genetic diagnosis, patients cannot receive gene specific treatment

### Supportive care includes:

- Visual aids such as magnifiers
- Home and work adaptations and mobility support
- NZ based organisations include:
- Blind Low Vision NZ <https://blindlowvision.org.nz>
- The Blind and Low Vision Education Network NZ (BLENNZ) <https://www.blennz.school.nz>
- Parent of Vision Impaired NZ <https://pvi.org.nz>
- Retina NZ Inc <https://retina.org.nz>

## 13.24 Retinitis Pigmentosa (RP)

A group of hereditary disorders involving progressive loss of photoreceptor and retinal pigment epithelium (RPE) function.

Typical RP is a diffuse, bilateral, symmetrical, retinal dystrophy with damage predominantly to rod function. Expression of the disease depends on the gene defect and mode of inheritance.

RP can occur as an isolated disorder or in association with certain systemic conditions.

### Symptoms

- Progressive difficulty with night vision and eventual night blindness and loss of peripheral vision. Poor central vision and colour vision occur relatively late in the disease.

### Signs

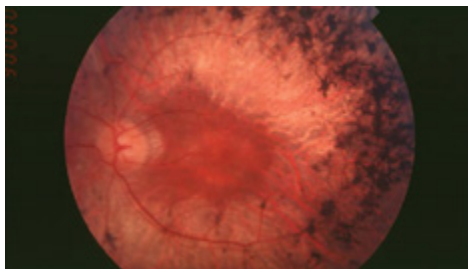
- The classic triad of 'bone spicule' clumps of pigmentation throughout the retinal periphery, arteriolar attenuation and late waxy optic disc pallor may be seen on retinal examination.
- Progressive field loss leads to a small central field.
- Myopia, posterior subcapsular cataract, cystoid macular oedema, raised intraocular pressure (IOP), vitreous changes, optic disc drusen and keratoconus are also associated with RP.
- The electroretinogram (ERG) is moderately to markedly reduced and the electro-oculargram (EOG) shows an absence of the light rise.

### Slit lamp signs

- The classic triad of 'bone spicule' clumps of pigmentation throughout the retinal periphery, arteriolar attenuation and late waxy optic disc pallor may be seen on retinal examination.

### Immediate management

- Refer for confirmation of the diagnosis and supplementary testing to establish the amount of vision loss. Try to establish the inheritance for diagnostic and counselling purposes.
- If neurological abnormalities such as ataxia, polyneuropathy or deafness are present arrange serum phytanic acid levels to



Typical pigment clumping in Retinitis Pigmentosa with 'bone spicule' pattern.

rule out Refsum disease. This can be treated with a low-phytanic acid, low-phytol diet.

- If RP is associated with fat intolerance check for hereditary abetalipoproteinaemia. Treatment is with replacement of fat soluble vitamins A, D, E and K with restriction of dietary fat.
- Pigmentary retinopathy is associated with chronic progressive external ophthalmoplegia in the Kearns-Sayre syndrome. Arrange cardiology referral as there is risk of death from complete heart block.

### Long-term management

- Treatment of inherited retinal dystrophy is going to be possible in the future, depending on the genetic mutation involved. Patient with mutations in the RPE65 gene can receive gene therapy and in the future, hopefully many more mutations can be treated.
- *Cataract Surgery* and treatment of cystoid macular oedema may improve central vision
- Refer for genetic counselling.
- In advanced cases, low-vision aids and vocational rehabilitation are essential.
- Retinal prostheses, which are implantable electronic devices designed to simulate sensation of vision in individuals with advanced disease, are also treatment options in patients with advanced vision loss.

### Referral guidelines

Referral to ophthalmology for confirmation of disease with visual field testing and electrodiagnostics within 4 weeks followed by referral to the genetics service.





## 14 *Orbit*



## 14.1 Orbital Cellulitis

As opposed to pre-septal cellulitis in which infection is limited to anterior structures, orbital cellulitis is a more severe and potentially sight-threatening disorder. Infection is usually from adjacent structures such as the lid, lacrimal system or sinuses, but rarely can be blood borne.

Infection within the orbit can impact on the extra-ocular muscles or in severe cases affect the optic nerve, reducing vision.

### Symptoms

- Orbital cellulitis is often painful and typically patients are aware of diplopia once the disease becomes retro-septal (spread into the orbit posterior to the orbital septum). Visual symptoms may occur from pressure on the globe or inflammation affecting the optic nerve.

### Signs

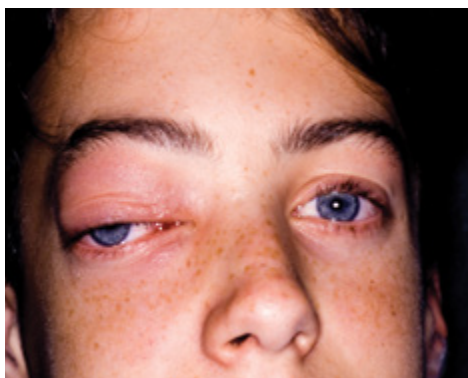- Redness and swelling of the lids.
- Varying degrees of ptosis and proptosis.
- Vision may be reduced if the infection is severe.
- Reduced eye movements confirm that the infection is within the orbit rather than limited to the preseptal region.

### Slit lamp signs

Very occasionally there will be anterior segment signs (such as a hypopyon) heralding the presence of an underlying intraocular infection and there will usually be chemosis and conjunctival injection with orbital infection. Using a 90 dioptre lens at the slit-lamp any optic nerve swelling can be assessed.

### Immediate management

As with any orbital condition, evidence of optic nerve dysfunction needs to be ruled out with urgency. CT scans are the preferred modality



Right orbital cellulitis with proptosis, and ptosis and swollen red upper lid.

to investigate orbital infection as they outline the bony walls and sinuses in detail. The presence of an abscess may need immediate drainage if there is optic neuropathy but otherwise it is mandatory to admit the patient for intravenous antibiotics and careful monitoring of progress.

### **Long-term management**

In general, patients will settle on appropriate systemic antibiotics and surgery if indicated. Underlying conditions, such as chronic sinusitis, need treating once the orbital infection has resolved.

### **Referral guidelines**

Patients with suspected orbital cellulitis should be referred urgently (within hours) for ophthalmic assessment. If the condition is confirmed, they are likely to need hospitalisation.

## 14.2 Orbital Inflammation

Orbital inflammatory disease can be broadly divided into thyroid (*See 14.5 Thyroid Eye Disease on page 214*) and non-thyroid related inflammation.

The latter group is sub-divided into regions of inflammation within the orbit and include dacryoadenitis (lacrimal gland), scleritis (*See 9.2 Anterior Scleritis on page 103*)(*See 9.3 Posterior Scleritis on page 105*), myositis (extra-ocular muscles), orbital apex (the Tolosa-Hunt Syndrome) and generalized orbital inflammation. The majority are idiopathic but some are related to systemic conditions such as Granulomatosis with polyangiitis, polyarteritis nodosa, sarcoidosis and TB.

### Symptoms

- Pain is generally a reliable sign of orbital inflammation
- Diplopia is common in all groups but particularly so with myositis.
- Optic nerve involvement within the orbit from orbital apex inflammation will produce loss of vision if left untreated. Other cranial nerve palsies may also be apparent.
- If the 3rd cranial nerve is affected patients may be aware of pupil changes and ptosis as well as diplopia.

### Signs

Along with most orbital conditions, the cardinal sign is proptosis. Reduced eye movements are commonly seen along with ptosis and pupil changes from 3rd nerve involvement. Optic neuropathy is recognised by reduced colour vision, an afferent pupillary defect and in some cases disc swelling. Swelling often continues forward into the lids which may become quite closed in significant inflammation.

### Slit lamp signs

- The optic disc is most easily examined using a magnifying lens with the slit-lamp.
- Occasionally orbital inflammation will be seen in conjunction with ocular surface inflammation (such as ulcerative keratitis in Granulomatosis with polyangiitis), or there may be co-existent retinal pathology as in sarcoidosis.

### Immediate management

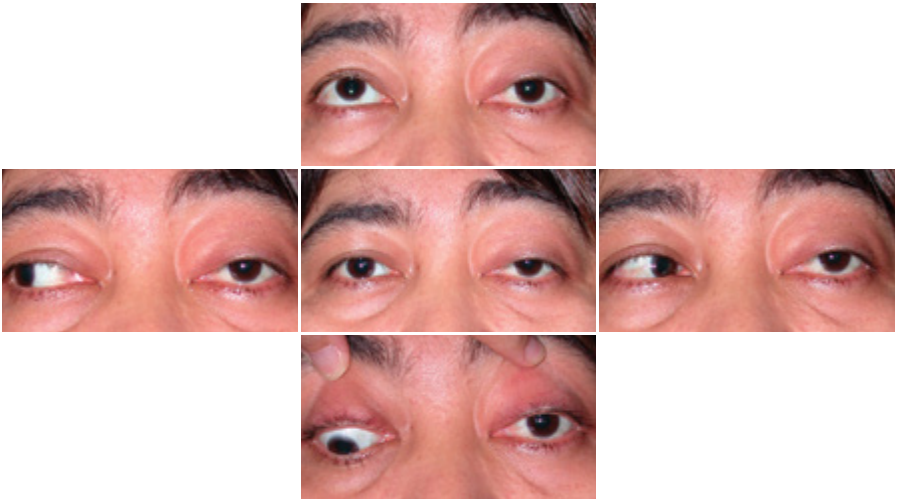CT or MRI scans should localise the disease process and help differentiate the condition from others, such as orbital cellulitis. With signs of optic nerve compromise or severe inflammation the patient should be treated with systemic immunosuppression.

## Long-term management

In most patients inflammation will settle reasonably quickly on appropriate medication. In some, radiotherapy is an option but all patients should have work-up for an underlying systemic condition.

## Referral guidelines

Urgent referral (same day) is indicated in patients with signs of optic nerve compromise or if there is severe pain. Otherwise patients are seen on a timely basis related to the severity of their symptoms.



Restriction of left eye movement caused by orbital myositis.

## 14.3 Orbital Cystic Lesions

While there are a variety of cystic lesions found in the orbit, by far the most common are dermoid cysts. These cysts have a bi-modal age of presentation usually occurring in either the first or fourth decades.

They are generally found anteriorly in the lateral brow region associated with the frontozygomatic suture but can be situated medially or occasionally deeply within the orbit, related usually with the sphenoid bone.

### Symptoms

- In children, parents generally notice a smooth rounded swelling, which slowly enlarges, laterally or, less commonly, medially in the upper lid in the first couple of years of life. The medial lesions need to be differentiated from meningo-encephalocoeles.
- In adults the cyst presents as a slowly enlarging painless lesion although with deep orbital dermoids there may also be proptosis.

### Signs

- Other than the swelling, signs may include inflammation if the cyst leaks and ptosis with large lesions. Palpation of the cyst may indicate whether it is freely mobile, attached to the underlying bone or actually passing through bone and into the orbit, adjacent sinus or brain.

### Slit lamp signs

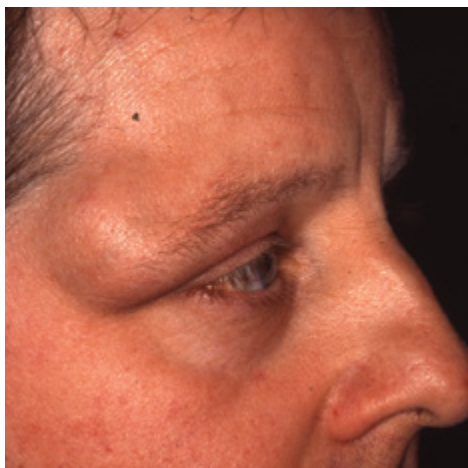- There are no specific slit-lamp signs of cystic lesions although a deep orbital dermoid cyst may compress the optic nerve and cause nerve swelling or pallor.

### Immediate management

The only lesions requiring relatively acute treatment are the rare cysts causing visual symptoms or those which have leaked.

### Long-term management

In general, dermoid cysts are best removed before they leak and in children this is unusual to occur before the age of two years.



Swelling lateral to brow typical of a dermoid cyst.

If there is any possibility that the cyst extends widely or through bone then a CT scan should be arranged prior to surgical removal. In these cases the tract through the bone also needs removal to prevent chronic inflammation from retained cyst wall tissue.

### **Referral guidelines**

Any lesion resembling a dermoid cyst should be referred for non-urgent assessment and discussion of the appropriate timing of surgical intervention.

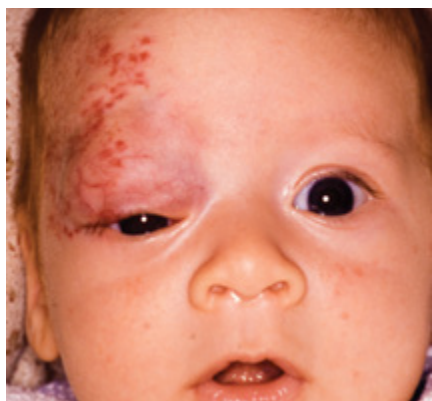## 14.4 Orbital Vascular Lesions

Capillary haemangioma (strawberry naevus) is the most common vascular lesion of childhood whereas in adults the most common orbital vascular lesion is a cavernous haemangioma.

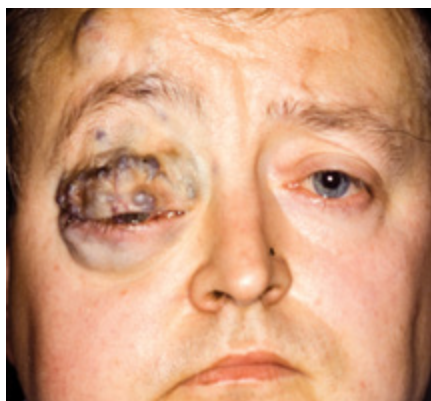There are also congenital vascular anomalies such as lymphangiomas and varices found in the orbit.

### Signs

- Capillary haemangiomas generally grow to a maximum size at 9 months of age, and then regress with most lesions having resolved by the age of 7 years. Typical skin changes seen with capillary haemangiomas are generally present with eyelid lesions but may be absent with deeper orbital lesions. The masses are often amblyogenic on account of their causing secondary ptosis or astigmatism.
- Lymphangiomas intermittently swell and can cause marked proptosis and or optic nerve compression. Episodes of swelling may be associated with upper respiratory tract infections.
- With cavernous haemangiomas there is usually gradual proptosis and optic nerve compromise if the lesion is situated in the orbital apex or becomes very large.
- Capillary haemangiomas often have a strawberry mark on the overlying skin. Typical 'chocolate cysts' may be seen within the conjunctiva representing cystic spaces containing altered blood. Cavernous haemangiomas generally just cause progressive proptosis but are increasingly an incidental finding on neuroimaging for other conditions. Other vascular anomalies may produce pulsatile proptosis or become apparent during a valsalva manoeuvre.



Capillary haemangioma.



Right orbital vascular anomaly.

## Slit lamp signs

Dark 'chocolate' cysts in the conjunctiva can be seen on slit-lamp examination in patients with lymphangiomas. In high flow vascular lesions, globe pulsations may be apparent.

## Immediate management

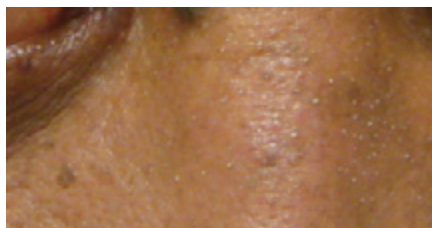Urgent treatment may be indicated with lesions which cause significant orbital haemorrhage or those associated with optic nerve compromise. This involves removal of blood and decompression of orbital structures.

## Long-term management

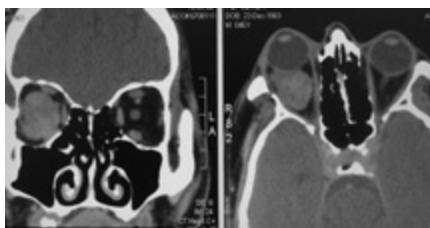
Each of the different vascular lesions has typical features on orbital imaging and this is very useful diagnostically particularly with venous anomalies and cavernous haemangiomas. Vascular lesions are often merely observed with intervention required when significant signs or symptoms arise. If cavernous haemangiomas need removal, this is often achieved via a lateral orbitotomy approach. Capillary haemangiomas are treated if the lesions are cosmetically unacceptable or visually threatening. The mainstay management is systemic Propranolol administered under observation by paediatricians, which results in resolution of lesions in the vast majority of cases. Occasionally excision of the residual lesion may be required.

## Referral guidelines

All patients with vascular anomalies or tumours of the eyelids or orbit need assessment by an ophthalmologist and urgent treatment if there is risk of visual loss. In children with a risk of amblyopia, early treatment is likely to produce a better long-term visual outcome.



Axial proptosis from a cavernous haemangioma..



CT of right cavernous haemangioma.



## 14.5 Thyroid Eye Disease

Thyroid related eye disease is a condition characterised by an acute inflammatory phase then followed by a more chronic fibrotic phase.

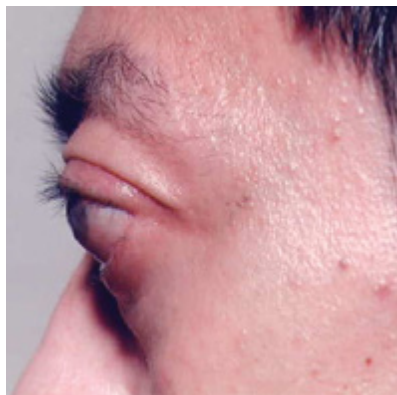Initially there is an immune related outpouring of water and glycosaminoglycans, typically causing expansion of the orbital fat and extra-ocular muscles. The disease process generally runs for about 2 years and is most commonly associated with hyperthyroidism (Graves Disease) and occasionally hypothyroidism, although 10% of patients are found to be euthyroid.

### Symptoms

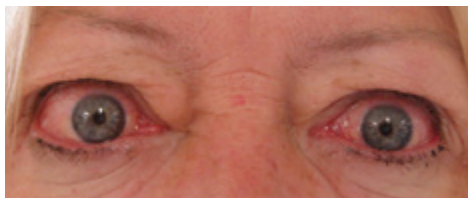- In the inflammatory phase patients suffer from conjunctival injection, tearing and a hot or burning sensation often related to corneal exposure. Patients may complain of eyelid swelling, a pressure feeling from increased orbital volume and visual deterioration. There may be diplopia and in severe cases of orbitopathy with compressive optic neuropathy, visual loss may occur.

### Signs

The hallmark of the condition is eyelid retraction, and increase in orbital volume causing proptosis (synonymous with exophthalmos in this condition). The conjunctiva is typically swollen in the acute phase. Diplopia from recti muscle involvement is common and typically there is restriction in upgaze and abduction from superior and medial recti swelling. Compressive optic neuropathy would be suspected in the presence of an afferent pupillary defect and/or reduced colour vision.



Lateral view of an eye with proptosis.



Prominent staring eyes with increased scleral show in thyroid eye disease.

## Slit lamp signs

- Inflammation is recognised by dilated conjunctival and episcleral blood vessels particularly over the insertions of the recti muscles, about 5–8mm from the limbus. Chemosis and swelling of the caruncle are signs of active inflammation. With acute optic nerve compression, the optic disc may be normal or swollen in appearance.

## Immediate management

- Sight-threatening complications such as optic nerve compression or corneal decompensation (from marked proptosis) should be managed immediately. The latter is very rare but optic neuropathy is less rare and this condition may require high dose systemic steroids, radiotherapy, orbital decompression or a combination of treatments.
- Some patients with diplopia will get temporary relief from the addition of prisms to their spectacles while awaiting the condition to settle and many will ultimately benefit from corrective strabismus surgery.

## Long-term management

- Longer term treatment is based around two factors. Firstly, if active inflammation can be reduced by steroids, other immunosuppressive agents, and/or low dose radiotherapy, then the chronic fibrotic phase of the disease may ultimately produce less morbidity. In patients where the inflammation is only mild, ocular lubricants are the mainstay of treatment. The disease symptoms and outcome are markedly worse in smokers and every effort should be made to stop patients smoking if they have the condition.
- In the chronic phase, treatment is geared towards returning the patient to a more normal situation with respect to both function and cosmesis. This may be achieved by strabismus and eyelid surgery and in patients with severe or asymmetrical proptosis, orbital decompression is indicated.

## Referral guidelines

Patients with signs of visual loss (colour vision testing is a sensitive test for this) or severe sight-threatening proptosis should be referred immediately or assessment. Otherwise, the urgency of referral depends on the degree of inflammatory symptoms, problems from diplopia or the cosmetic concerns of the patient.

## 14.6 Orbital Tumours

Orbital tumours are rare, occurring with an incidence of 1 case per 250,000 of the population per annum.

As the orbit is a contained space open anteriorly, most tumours cause a mass effect with the eye being pushed forward (proptosed) away from the lesion. Occasionally enophthalmos can occur with cicatricial lesions such as scirrhous breast secondaries or aggressive destructive lesions.

Tumours can affect any of the structures within the orbit such as the lacrimal gland, extra-ocular muscles, bony walls, optic nerve, peripheral nerves and blood vessels. The pathology ranges from the benign to highly malignant lesions.

### Symptoms

- Most patients notice their eye becoming displaced forwards and there may be diplopia (double vision) from mass effect or extra-ocular muscle involvement as well as visual symptoms related to reduction in vision.
- Visual symptoms can relate to direct pressure on the globe or optic nerve compression.

### Signs

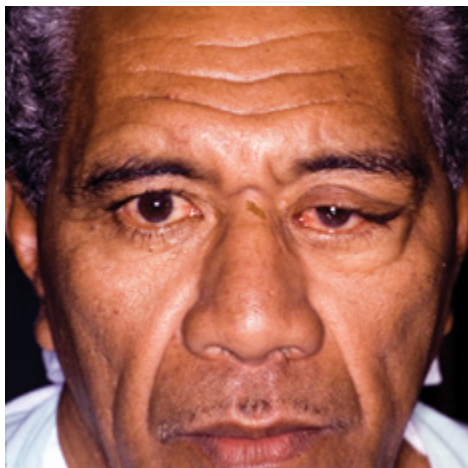
- Proptosis is a common sign of orbital tumours as is reduced eye movements. An afferent pupillary defect and reduced colour vision are signs of optic nerve compromise, often from compression. Patients should be checked for pre-auricular and cervical lymphadenopathy, as well as alteration in sensation in V1 or V2 nerve distributions.

### Slit lamp signs

- Optic nerve swelling or pallor is best assessed at the slit lamp and any mass effect in the orbit may give rise to choroidal folds seen in the posterior pole of the fundus.

### Immediate management

With orbital tumours the urgency of treatment relates to the presence or likely occurrence of optic nerve dysfunction and the possibility of a malignant lesion. Patients will require CT or MRI scanning or a combination of the two. In the majority of malignant lesions, an early biopsy is indicated.



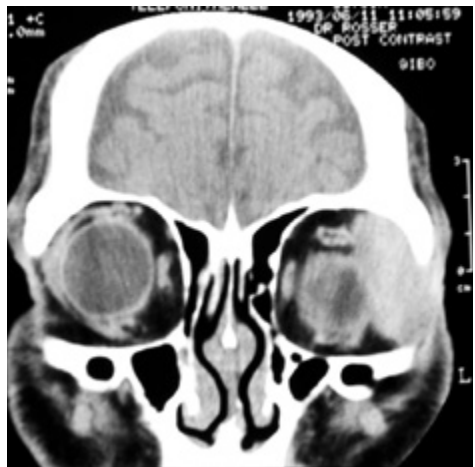Left lacrimal gland tumour with the classic 'S-shaped lid deformity'.

## Long-term management

Some masses are better left alone although the majority will require removal via an orbitotomy or at least a biopsy to verify the nature of the condition. Depending on the pathology, further surgery (such as exenteration), or treatment with other modalities including radiotherapy or chemotherapy may be indicated.

## Referral guidelines

All patients with suspected orbital tumours should be referred for assessment within a week of presentation but sooner if there is suspected optic nerve compromise or there is suspicion of an aggressive neoplastic disease.



CT of a left lacrimal gland tumour.



## 15 *Uvea*

## 15.1 Iris Melanomas

They are the rarest form (3–13%) of intraocular melanoma and are often first noticed as a change in a pre-existing naevus. They are usually larger than an iris naevus ( $> 3\text{ mm}$  base,  $> 1\text{ mm}$  thick) and can either be focal or diffuse, pigmented (melanotic) or not (amelanotic).

Focal iris melanomas are more common in the inferior iris of light-skinned people.

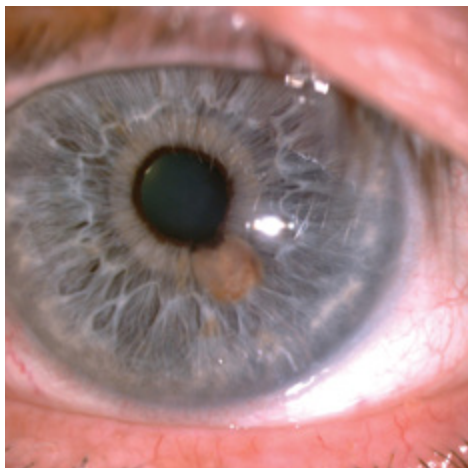
Diffuse melanomas cause progressive darkening of a wide area of the iris (heterochromia), loss of iris crypts, and are more likely to lead to glaucoma.

### Symptoms

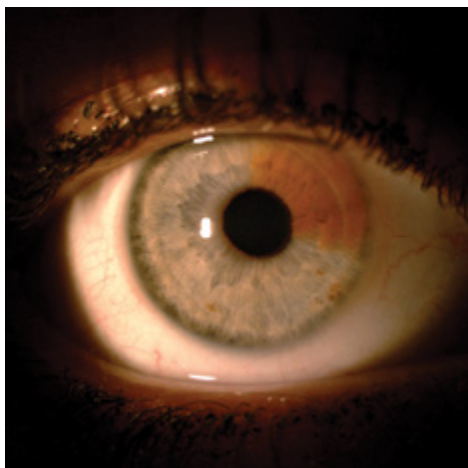- Iris melanomas are usually asymptomatic. Occasionally there is pain due to secondary glaucoma.

### Signs

- The most important sign is a distinct change in iris pigmentation, either focal or diffuse. This may be noticed by the patient or by family or friends, or it may be picked up at a routine eye examination. Iris naevi often become apparent as they darken at puberty or young adulthood.



Iris melanoma. Note the distortion of the pupil margin near the tumour.



Iris naevus.

### Slit lamp signs

- Size > 3 mm, thickness > 1 mm.
- Prominent blood vessels in the mass.
- Pulling on pupil margin (ectropion uveae).
- Focal cataract.
- Seeding of pigmented cells into the anterior chamber (a/c), or hyphaema (bleeding into a/c).
- Transillumination indicates an iris cyst.

### Immediate management

- Thorough documentation of the lesion: photography, gonioscopy, high-frequency ultrasound, intraocular pressure and indented examination to check the fundus and ciliary body.
- Differentiation from a benign nevus is often difficult so documented growth is most important.
- Differentiation from alternative diagnoses should be made if possible, including: iris naevus or cyst, inflammatory mass (sarcoid or TB), haemosiderosis, and metastasis from other cancers.

### Long-term management

Repeat visits at 3- to 12-month intervals depending on the degree of clinical suspicion. Surgical removal of a smaller lesion may be indicated if there is growth or other change. Larger tumours can be treated with plaque radiation. Enucleation may be required if the melanoma is very large, or if there is secondary glaucoma.

### Referral guidelines

A history of pigment change, or any of the slit lamp signs above warrant specialist referral for documentation and monitoring.



## 15.2 Other Iris Lesions

A number of conditions may present as a visible change in the appearance of the iris. The specific appearance, associated ocular pathology, and management are discussed below for each type of lesion.

### Iris hypoplasia

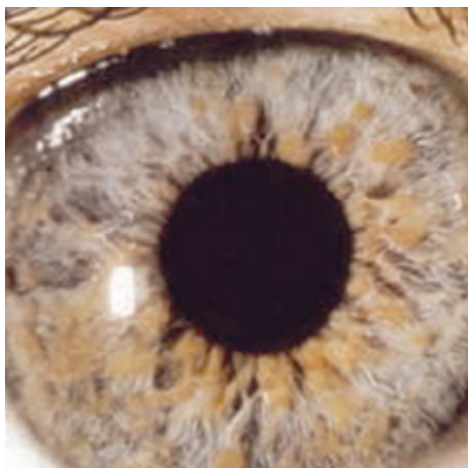Iris hypoplasia is part of the inherited ocular syndrome of aniridia, which is due to a PAX6 gene mutation and may also include nystagmus, optic nerve and retinal hypoplasia, limbal stem cell deficiency and cataract. It is generally bilateral and the iris may be partly deficient or totally absent so that the equator of the lens is visible as well as the zonules and the ciliary body. Treatment may include cataract extraction with insertion of artificial iris.

### Juvenile xanthogranuloma

Juvenile xanthogranuloma is a rare, benign histiocytic lesion, occurring in children 2 years or younger. Most commonly it produces yellow or red-brown papular lesions of the skin, but involvement of iris, ciliary body, orbit or eyelids may occur. In the iris this results in usually unilateral, fleshy appearing lesions with prominent surface vessels. It may be a cause of unilateral glaucoma, iris heterochromia or episodic blurred vision and pain from multiple spontaneous hemorrhages into the a/c (spontaneous hyphaema).

### Lisch nodules: neurofibromatosis-1

- Lisch nodules usually arise in the first decade in almost all patients with neurofibromatosis-1 but no patients with neurofibromatosis-2.
- They appear as smooth, small, multiple, usually bilateral, elevated yellow to brown nodules on the surface of the iris.
- They are benign hamartomas, histologically identical to iris naevi.
- No treatment is required.



Lisch nodules on the surface of the iris.



## Iris haemangioma

- These very rare iris tumours may occur in children or adults.
- They appear as red, purple or brown lesions of the iris or pupil margin and may be confused with other iris lesions such as naevus, melanoma, xanthogranuloma, inflammatory granuloma. They may also be associated with vascular tumours of the fundus and with other vascular malformations, e.g. brain, kidney, skin.
- They may result in spontaneous hyphaema or elevated intraocular pressure.

## Primary iris cyst

- A primary cyst of the iris stroma is an uncommon lesion found in children, most commonly in the first year of life.
- It appears as a cystic lesion on the surface of the iris of variable size in an eye with no history of prior surgery or penetrating ocular trauma. It may be asymptomatic or may cause reduced vision, photophobia, inflammation or secondary glaucoma.
- Management is generally observation unless it is causing secondary damage in which case surgical excision may be attempted. Histologically it is a non-keratinised squamous epithelial-lined structure arising within the iris stroma.

## Secondary iris cyst

- As a result of trauma or surgery, epithelial cells from the ocular surface may become implanted in the anterior chamber and develop into cystic structures of the iris or anterior chamber angle. They may be complicated by secondary glaucoma, visual disturbance, and pressure damage to adjacent structures.
- Treatment is difficult with most treatment options being complicated by scarring, inflammation and recurrence of the cyst.

## Irido Corneal Endothelial Syndrome

- A rare unilateral anterior segment condition in which the endothelial cell layer is abnormal and behaves more like an epithelial layer, spreading over the angle and over the surface of the iris.
- The surface of the iris may develop the appearance of multiple small iris naevi. Other features include progressive iris atrophy and polycoria, glaucoma secondary to anterior chamber angle, and corneal oedema secondary to endothelial dysfunction.
- Treatment for the complications includes glaucoma surgery and corneal transplantation.

## 15.3 Choroidal Naevus

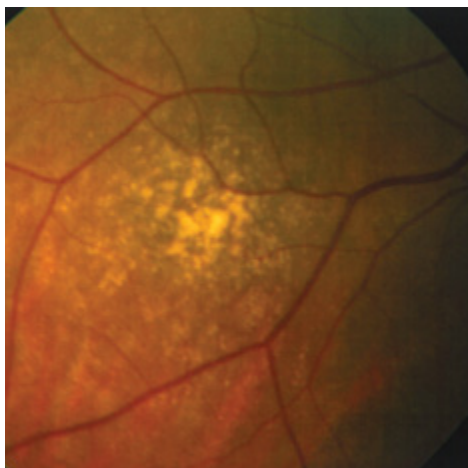
Choroidal naevi are common melanocytic lesions with a reported frequency of around 7%. The importance of documenting the presence of naevi relates to the life time risk of malignant transformation (approximately 1%) and that the apparent naevus may in fact be a malignant melanoma of the choroid.

### Symptoms

- Most choroidal naevi are asymptomatic.
- Symptoms of flashes or decreased vision are an indicator that the lesion may be malignant.

### Signs

- On fundal examination the lesions appear grey to brown, typically flat and < 5 mm in diameter. Drusen may be present in the lesion. A more peripheral position – further than 3 mm or 2 disc diameters (DD) from the optic disc – indicates a lower risk of malignancy. A depigmented halo around a naevus is rare but also reassuring.



Choroidal naevus with drusen.

The ophthalmoscopic and ultrasound features that are associated with an increased risk of developing into a melanoma are:

#### Lower risk

- No symptoms (good vision, no flashes)
- No overlying orange pigment
- Size < 5.0 mm (~3½ DD)
- Drusen present
- Pale amelanotic halo around naevus
- No subretinal fluid
- Thickness < 2 mm on ultrasound
- High reflectivity on ultrasound

#### Higher risk

- Symptoms (decreased vision or flashes)
- < 3 mm (2 DD) to optic disc
- Orange pigment present
- Size > 5.0 mm (~3½ DD)
- No Drusen
- No halo (but 95% of naevi lack halo)
- Subretinal fluid
- Thickness > 2 mm on ultrasound
- Ultrasound hollowness (low echo)

#### Immediate management

Observation and documentation. If the lesion is suspicious then ophthalmic review is warranted. Three or more of the high risk factors indicate a significant chance of developing into a melanoma.

#### Long-term management

- 1–2 yearly review.

#### Referral guidelines

- If the lesion is suspicious then review is warranted.

## 15.4 Choroid Melanoma

Choroidal melanomas can be pigmented (melanotic) or non-pigmented (amelanotic). They are more common in light-skinned people and are the most common form of ocular tumour. The incidence in New Zealand is approximately 25 cases per year.

### Symptoms

- Choroidal melanomas are often asymptomatic. When present, symptoms include visual field defects, reduced vision, light flashes, floaters, and pain.

### Signs

Usually no external signs but rarely feeder vessels are visible externally on the sclera. On fundal examination melanomas are usually an even grey but can be variable or lacking pigment. Smaller lesions must be distinguished from naevi ([See 16.3 Giant Cell Arteritis on page 236](#)).

#### Features of choroidal melanoma include:

- Documented growth – particularly if rapid.
- “Collar stud” growth with a focal mushroom-shaped extension through the choroid.
- Thickness > 3 mm on ultrasound.
- Large base > 5 mm (~3½ DD).
- Significant subretinal fluid or detachment.
- Subretinal or vitreous haemorrhage.
- Overlying orange pigment (lipofuscin).

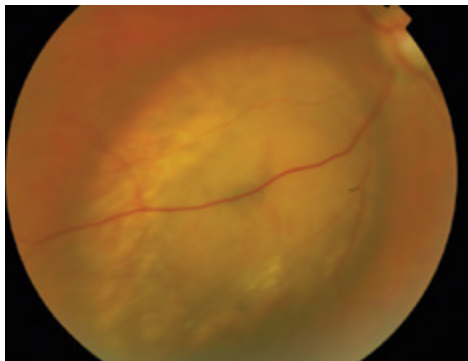
Rarely a diffuse choroidal melanoma shows no focal changes.

### Slit lamp signs

- Rarely feeder vessels or mass to pupil.

### Immediate management

Initial work up includes careful clinical examination, ultrasound, and fluorescein angiography. Ultrasound shows even, medium-low reflectivity and excavation



Large choroidal melanoma.

of the choroid. In doubtful cases fine needle aspiration may be necessary. If malignant melanoma is suspected a thorough systemic workup for metastases is indicated.

### **Long-term management**

Once diagnosed treatment is tailored to the size and position of the lesion. Plaque radiation or external beam radiation is the usual treatment. Very large lesions, lesions adjacent to the optic nerve, or patient preference may require enucleation (removal of the eye). Very small lesions can occasionally be photocoagulated. Prognosis is better than for comparably sized skin melanomas, and is related to tumour size, degree of anterior position, extrascleral extension, and cell type.

### **Referral guidelines**

All large pigmented fundal lesions, or smaller lesions with elevation or any other suspicious signs, should be referred for evaluation and diagnostic testing.

## 15.5 Capillary Haemangioma of the Retina (*von Hippel-Lindau Disease*)

Capillary haemangioma of the retina is a vascular tumour consisting of large, tortuous capillaries.

The lesions have high blood flow and are often multiple and bilateral. Early tumours can become apparent in childhood and gradually enlarge and proliferate throughout life. More than one lesion is highly likely to indicate von Hippel-Lindau disease, with multiple systemic associations including CNS haemangiomas, and kidney tumours.

### Symptoms

- The lesions are initially asymptomatic, and may be picked up on examination of members of families with known genetic risk. Later lesions can cause distortion, and loss of vision due to exudation, retinal detachment, vitreous haemorrhage, or macular pucker.

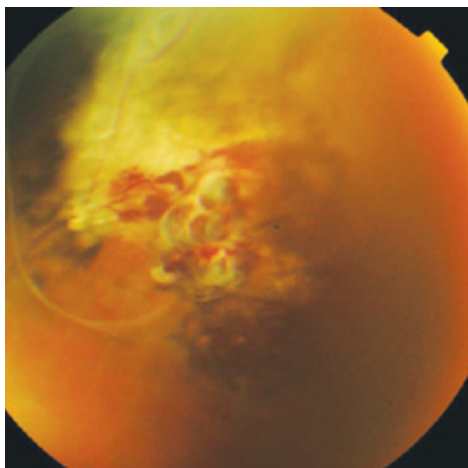
### Signs

- On funduscopy, the lesions appear as red-orange intraretinal masses with dilated feeder vessels. With enlargement other features become more prominent, including exudation, retinal detachment, haemorrhage, and fibrous proliferation and distortion. Lesions are sometimes adjacent to the optic disc, in which case no feeder vessels are visible.

### Immediate management

Smaller lesions are relatively easy to treat and rapidly become more difficult with enlargement, so immediate treatment is indicated. Juxtapapillary lesions (next to the optic disc) are more difficult to treat and may be observed initially. A careful search for other early lesions in the same and other eye should also be undertaken. For early lesions laser treatment and cryotherapy are usually sufficient. In advanced cases surgery, direct cautery, retinal detachment repair,

A retinal cavernous haemangioma.



A retinal cavernous haemangioma.

and peeling of epiretinal membranes may be attempted, with limited prognosis for good vision.

### **Long-term management**

Retinal haemangiomas are often the first sign of von Hippel-Lindau disease. Referral for a thorough systemic work up, genetic studies, and examination of other family members if previously undiagnosed are mandatory. Repeated fundal examinations and treatment of new haemangiomas as they arise can maintain good vision.

### **Referral guidelines**

Any fundal lesion with feeder vessels, or any patient with known family history of von Hippel-Lindau disease, should be referred for specialist follow-up.

## 15.6 Retinal Pigment Epithelium Tumours

The most common retinal pigment epithelium tumour is congenital hypertrophy of the retinal pigment epithelium or CHRPE. More rarely RPE hyperplasia may occur after trauma or inflammation.

### Symptoms

- There are no symptoms related to CHRPE. There may be a history of trauma or inflammation associated with RPE hyperplasia.

### Signs

These lesions are usually found on routine fundal examination.

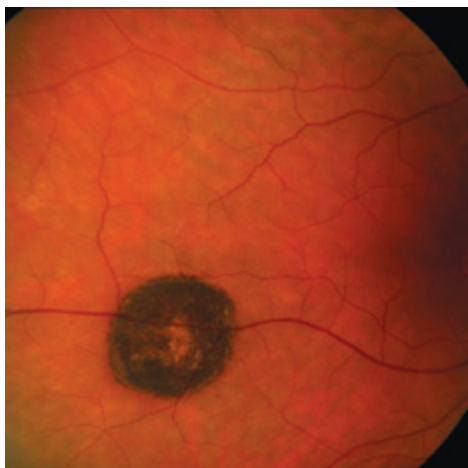
- CHRPE are flat and jet black early in life. Their borders are usually very well defined and may be scalloped. There is sometimes a depigmented halo at the margin of the lesion. Later in life characteristic pale lacunae develop within the lesion and may expand so that the CHRPE is ultimately fully depigmented apart from a sharp, dark margin.
- A lesion similar to CHRPE involves multiple small pigmented lesions, “bear tracks”, which may be very numerous. They have been associated with Gardner’s Syndrome (familial adenomatous polyposis) and an increased risk of bowel cancer.
- Retinal pigment epithelium hyperplasia usually develops in response to chronic traction on the RPE. It is less well defined than CHRPE and may lead to involvement and distortion of the overlying retina. It can usually be differentiated on the basis of associated findings and history.

### Long-term management

- Usually none.

### Referral guidelines

If there is a clinical suspicion of ocular malignant melanoma the patient should be referred for specialist opinion and further tests which may include ultrasound and fluorescein angiogram. If there are multiple lesions – “bear track” pattern – initial referral to an ophthalmologist may be followed by genetic testing and a gastroenterology opinion if indicated.



Typical CHRPE.



## 15.7 Primary Intraocular Lymphoma

Intraocular lymphoma may be primary, arising in the retina or vitreous, or less commonly secondary due to metastatic spread of systemic lymphoma.

Primary intraocular lymphoma is a subset of primary central nervous system lymphoma (PCNSL) and intracranial disease develops in over two-thirds of patients who initially have isolated ocular disease.

### Symptoms

- Floaters and blur.
- Neurological symptoms, e.g. behaviour changes, focal weakness, cerebellar signs.

### Signs

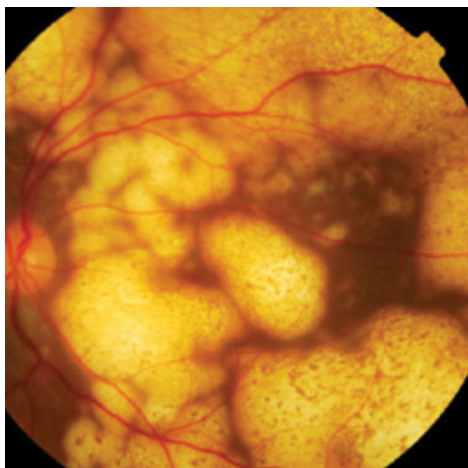
- Reduced visual acuity (unilateral or bilateral).
- White eye.

### Slit lamp signs

- Minimal or no anterior segment involvement.
- Large vitreous clumps or sheets of cells.
- Creamy-yellow subretinal infiltrates.
- Retinal vasculitis.

### Immediate management

- Any patient with suspected intraocular lymphoma requires diagnostic vitreous biopsy. Repeat biopsies may be required as the laboratory confirmation is difficult.
- Patients also require MRI, lumbar puncture and oncology review.



Multiple white retinal lesions in lymphoma.

### Long-term management

- Optimal management of PCNSL is not known as prognosis remains poor, with median survival between 12 and 18 months.
- Treatment options for isolated ocular lymphoma include systemic chemotherapy (e.g. Methotrexate), intraocular Methotrexate injections and local radiotherapy. Management is in conjunction with an oncologist.

### Referral guidelines

- All patients with known primary CNS lymphoma should receive a baseline eye check, repeated if any new visual symptoms.
- Any patient with history of increasing floaters and blur should be referred within 1 week.



## 16 *Neuro*

## 16.1 Optic Neuritis

Optic neuritis (also known as retrobulbar optic neuritis) is an acute inflammatory condition of the optic nerve resulting in rapid monocular vision loss.

It occurs in young patients 15–45 years and is more frequently seen in females (75%). The cause is usually idiopathic but may also be the initial presenting sign of multiple sclerosis (MS).

### Symptoms

- Loss of vision (over a few days).
- Peri-ocular pain especially with eye movement.
- Loss of colour perception and red desaturation.
- Loss of visual field

### Signs

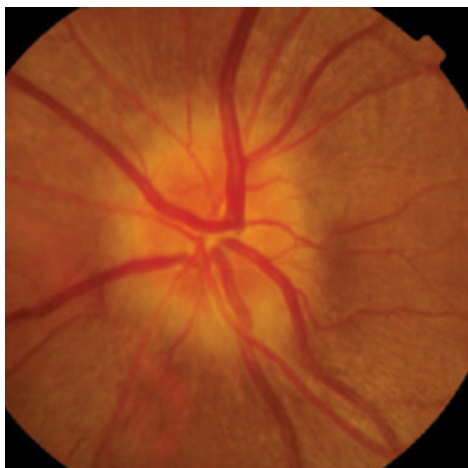
- Decreased visual acuity, not improving with pinhole (vision ranging from 6/6 to no perception of light).
- Relative afferent pupillary defect (RAPD).
- Reduced colour vision (on testing with Ishihara plates), or reduced ability to see red.
- Visual field loss (often central, but can be any pattern of unilateral retinal nerve fibre loss).
- 20% may have optic disc swelling.

### Slit lamp signs

- There may be no slit lamp or fundal signs.

### Immediate management

- If visual acuity (VA)  $<6/12$  recommended treatment as per Optic Neuritis Treatment Trial (ONTT) is intravenous methylprednisolone (1g/day x 3), followed by oral prednisone 1mg/kg for 11 days.
- Semi-urgent MRI scan is recommended to confirm evidence of



Swollen optic nerve in optic neuritis.

optic nerve involvement and other white matter lesions described as demyelinating plaques.

- Additional blood tests for NMO spectrum antibodies eg. Anti-MOG

### Long-term management

- Most patients regain vision over one month, but often report persisting reduction in the quality of vision.
- There is an associated risk of developing demyelinating disease (most commonly multiple sclerosis), especially if other neurologic symptoms and signs are present.
- Different treatments specific for NMO spectrum disease.

### Referral guidelines

- Urgent referral to ophthalmology for initial treatment.
- Long-term follow-up with ophthalmology and neurology.

## 16.2 Anterior Ischaemic Optic Neuropathy

This presents as a sudden loss of vision affecting one eye, most commonly in middle-aged patients, often with a history of hypertension.

It is also referred to as Non-arteritic anterior ischemic optic neuropathy (NAAION). It is thought to be caused by small vessel disease of the anterior optic nerve.

### Symptoms

- Painless loss of vision initially affecting just part of the visual field and often noted on awakening.
- Progressive vision loss over days.

### Signs

- Decreased visual acuity not improving with pin-hole.
- A relative afferent pupillary defect (RAPD).
- Loss of visual field often in an altitudinal pattern (horizontal midline).
- Optic disc oedema which may be sectorial.
- The optic disc in the fellow eye often will be small and crowded.

### Slit lamp signs

- Disc appearance as above.

### Immediate management

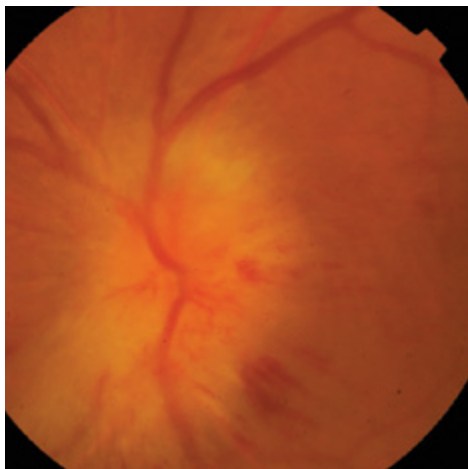- Giant cell arteritis needs to be ruled out clinically (*See 16.3 Giant Cell Arteritis on page 236*) and with urgent blood tests (FBC, ESR, CRP).
- There is no proven therapy available for NAION.

### Long-term management

- Low dose Aspirin is thought to be protective against involvement of the fellow eye?

### Referral guidelines

- Semi-urgent referral to ophthalmology.



Swollen nerve with flame haemorrhage.

## 16.3 Giant Cell Arteritis

Giant cell arteritis (GCA), also known as temporal arteritis is an inflammatory disease of medium sized arteries most commonly in the head and neck though may occur throughout the body.

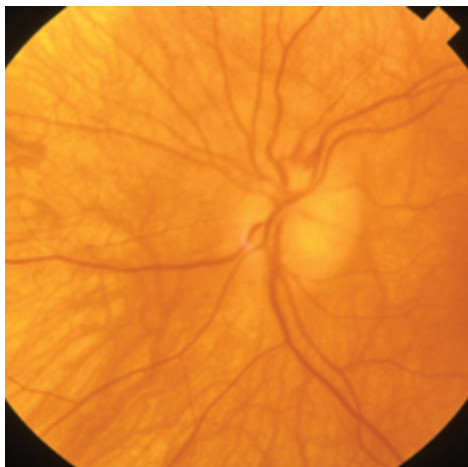
This is a vision-threatening condition due to ischaemic optic neuropathy, also known as arteritic anterior ischemic optic neuropathy (AAION). It can result in permanent loss of vision, mainly affecting elderly patients, and is rarely seen in patients less than 60 years of age.

It often presents asymmetrically and prompt recognition of the disease and aggressive treatment with steroids is required to potentially save vision in the fellow eye.

- Differential diagnosis:
- Non arteritic ischaemic optic neuropathy (*See 12.2 Chronic Anterior Uveitis on page 135*).
- Central retinal artery occlusion (*See 10.3 Intraocular Lenses (IOLs) on page 113*).
- Carotid occlusive disease with ocular ischaemia.

### Symptoms

- Headache/temporal pain or tenderness/pain with hair-brushing.
- Fleeting loss of vision (amaurosis fugax).
- Jaw claudication (pain on chewing).
- Intermittent diplopia.
- Generally feeling unwell, fever, malaise and poor appetite.
- History of polymyalgia rheumatica.



Anterior ischaemic optic neuropathy with sectorial swelling and pallor of the optic nerve head.

## Signs

- Reduced visual acuity not improving with pinhole.
- Relative afferent pupillary defect (RAPD).
- May have restricted ocular motility.
- Usually normal anterior segment.
- Swelling of the optic disc with pallor and haemorrhages.
- Can have central artery occlusion (10%).

## Slit lamp signs

- Disc appearance as above.
- Potential to have ocular ischaemia signs with anterior chamber inflammation (flare and cells – see 8-1–8-15).

## Immediate management

- Request urgent blood test – FBC, ESR, CRP.
- If diagnosis of GCA is highly suspected based on clinical and systems assessment, administer high dose oral steroids immediately (don't wait on blood test results).
- Inpatient management: intravenous Methylprednisolone 1000mg/day.
- Temporal artery biopsy to confirm diagnosis.

## Long-term management

- Oral prednisone after three days of intravenous methylprednisolone.
- Taper dose of oral prednisone according to ESR/CRP results. Up to 12 months of therapy required.
- Management of steroid-induced side effects especially osteoporosis.

## Referral guidelines

- Immediately refer to ophthalmology.



## 16.4 Papilloedema

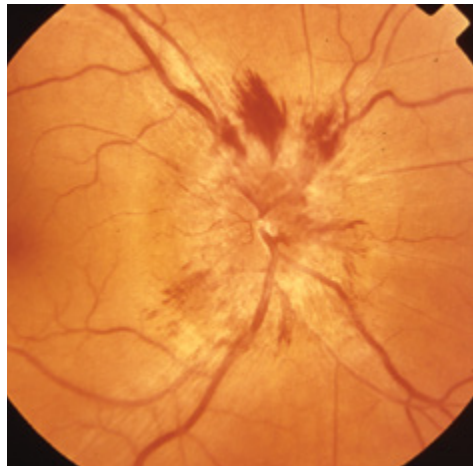
Papilloedema refers to swelling of the optic disc from increased intracranial pressure (ICP). It must be differentiated from optic disc swelling due to other causes, termed “optic disc oedema”.

Bilateral papilloedema can be due to reasons, such as brain tumor, CNS inflammation, or idiopathic intracranial hypertension (IIH – see 12-5).

- Other causes of optic disc oedema:
- Unilateral
- Optic neuritis (pain on eye movement)
- Neuroretinitis (exudates form macular star, cat scratch)
- Ischaemic optic neuropathy (arteritic or non arteritic)
- Central retinal vein occlusion (CRVO)
- Hypertensive disc oedema
- Bilateral
- Inflammatory/infectious lesion (such as sarcoidosis, toxoplasmosis, VKH, other uveitis)
- Diabetic papillopathy
- Drug induced (minocycline)
- Infiltrative optic neuropathy and tumors (lymphoma, leukemia)
- Compressive optic neuropathy (optic nerve sheath meningioma)
- Thyroid ophthalmopathy

### Symptoms

- Headache
- Nausea and vomiting if sudden increase in ICP
- Transient visual obscurations where vision is lost for fleeting periods of time (only seconds)



Swollen optic nerve head with flame haemorrhages in papilloedema.

## Signs

- Visual acuity usually preserved
- A relative afferent pupillary defect (RAPD) may be present
- Enlargement of the physiologic blindspot

## Slit lamp signs

- Blurred margins of the optic disc often with haemorrhages and elevation and loss of spontaneous venous pulsations.

## Immediate management

- Refer to neurology for urgent neuro-imaging: MRI/MRA/CT with contrast.

## Long-term management

- Underlying cause treated by appropriate specialist (neurologist/ophthalmologist).

## Referral guidelines

- Urgent referral to ophthalmology/neurosurgery/neurology, based on underlying pathology.

## 16.5 Idiopathic Intra-Cranial Hypertension (IIH)

Also called benign intra-cranial hypertension (BIH), and pseudotumour cerebri (PTC). This is an idiopathic condition characterised by optic disc swelling, and has a potential for peripheral visual field loss, associated with headache, usually in obese young women.

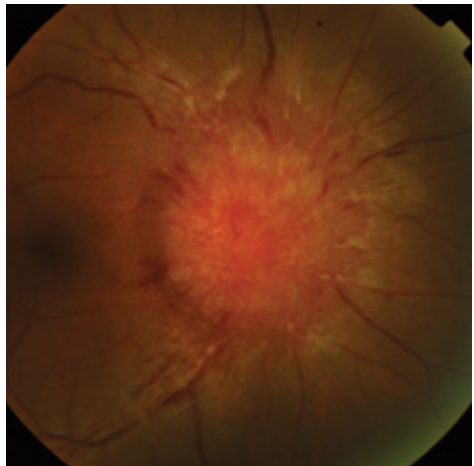
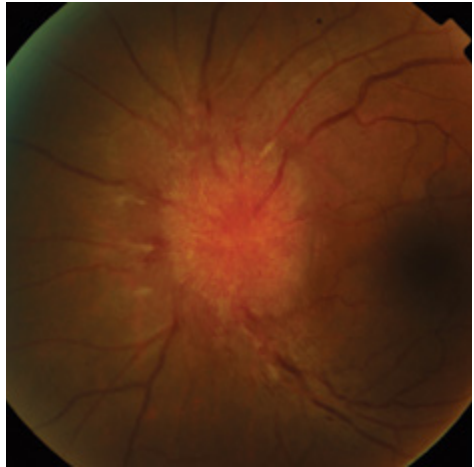
It is thought to be due to elevated cerebro-spinal fluid (CSF) pressure and abnormalities of CSF production/absorption.

### Symptoms

- Headaches.
- Peripheral vision loss.
- Diplopia (often sixth nerve, but also third and fourth cranial nerve palsies).
- Tinnitus (whooshing noise heard).
- Transient visual obscurations (fleeting loss of vision with postural change).

### Signs

- Relative afferent pupillary defect.
- Reduced visual acuity.
- Reduced colour vision (Ishihara pseudo-isochromatic plates).
- Loss of peripheral vision (formal automated visual field testing shows retinal nerve fibre bundle defects).



Bilateral swollen optic discs as seen in Idiopathic Intracranial Hypertension (IIH).

### Slit lamp signs

- Optic discs swelling affecting both eyes (may be asymmetric).

### Immediate management

- Appropriate neuro-imaging: MRI scan with venography (MRV), to exclude cerebral venous sinus thrombosis or CT / CT venography.
- Lumbar puncture to confirm elevated CSF opening pressure. (after normal imagine only!)
- CSF should be entirely normal.
- Treatment with oral acetazolamide (Diamox), up to 500mg qid.
- Weight loss should be actively encouraged and is often curative.

### Long-term management

- Progressive vision loss may require optic nerve sheath decompression.
- Progressive headaches may require lumbar-peritoneal/ventriculo-peritoneal shunting.
- Exclude possible underlying causes (hypervitaminosis A, idiosyncratic drug reactions, e.g. minocycline).
- Long-term management requires ongoing formal visual field assessment with ophthalmologist.

### Referral guidelines

- Acute referral to ophthalmology or CT / CT venography or neurology.

## 16.6 Chiasmal Lesions/Syndromes

The hallmark of these conditions is bi-temporal visual field loss, due to the neuro-anatomy of the chiasm and surrounding structures. Ganglion cell fibres from the nasal retina of each eye decussate (cross) in the centre of the chiasm, before passing into the optic tract posteriorly.

A compressive lesion impacts on the chiasm causing a typical bi-temporal visual field pattern affecting the superior field initially and then spreading inferiorly. The most common lesions to impact the chiasm are pituitary tumours with suprasellar extension. Other causes include sellar meningioma, craniopharygioma, aneurysm, trauma, and inflammatory/infectious conditions.

### Symptoms

- Some patients may note loss of peripheral vision (tunnel vision), and report difficulties with judging proximity (knocking into objects and driving issues).
- Loss of colour perception.
- Diplopia.
- Headaches.
- Symptoms due to underlying pituitary dysfunction.
- A sudden symptoms if pituitary apoplexy – urgent referral to neurology.

### Signs

#### Signs of optic nerve dysfunction:

- decreased visual acuity.
- relative afferent pupillary defect (RAPD).
- decreased colour vision/red desaturation.
- visual field loss – confrontation visual field testing with a red target is the most sensitive test.
- Anterior chiasmal lesions result in a junctional scotoma (loss of central visual field on the affected side and peripheral loss on the unaffected side) with ipsilateral nerve dysfunction asymmetry.
- Signs of specific pituitary dysfunction (acromegaly, prolactinoma).

### Slit lamp signs

- Optic nerve swelling or optic nerve pallor – may be sectoral.

## Immediate management

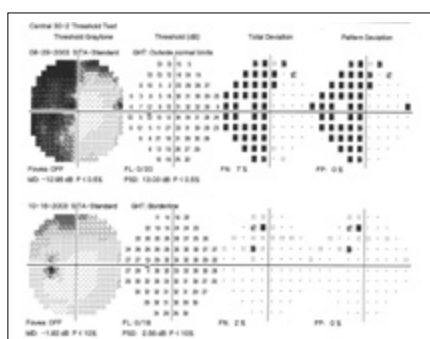
- Confirmation of visual field defect with automated visual field testing (perimetry).
- Neuro-imaging – the best option is MRI, brain and orbits with contrast.
- Referral for endocrinological work-up. Some hormone secreting tumours respond to medical therapy, e.g. bromocriptine for prolactinoma.
- Referral to neuro-surgery for removal of pituitary tumour if required (e.g. resection via trans-sphenoidal approach via the nose).

## Long-term management

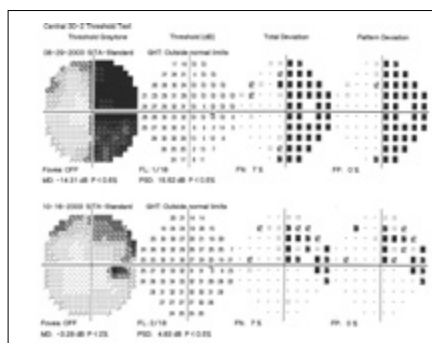
- Follow up visual field testing on a regular basis, along with repeat imaging to exclude recurrence.
- May require radiotherapy.

## Referral guidelines

- Initial referral to ophthalmology for formal visual field testing.



Left



Right

The uppermost visual fields show bi-temporal hemianopia with temporal loss of visual field of both right and left eye. The lower visual fields show resolution after treatment of the chiasmal lesion, 8 weeks following pituitary resection.

## 16.7 Retrochiasmal Lesions

Retrochiasmal lesions involve the visual pathway posterior to the chiasm, resulting in homonymous patterns of visual field loss affecting both eyes.

There may be associated neurologic deficits such as hemi-field neglect as seen with parietal lesions. The most common cause of a retrochiasmal lesion is a CVA often in association with hypertension, but may also occur with intracranial tumours.

### Symptoms

- Patients may complain of non-specific blurred vision, bumping into objects, and missing parts of their vision.
- Some patients may be asymptomatic.

### Signs

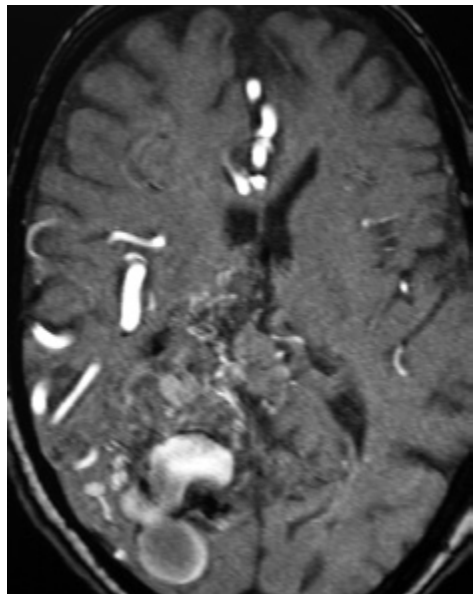- Visual acuity usually not affected, but often patients will have difficulty with reading.
- Visual field loss with confrontation testing using a red target.
- Associated neurologic deficits such as hemi-field neglect (inability to pay attention or to notice stimuli) on the same side as the visual field defect.

### Immediate management

- Confirmation of visual field defect with automated visual field testing (perimetry) using Humphrey or Medmont visual field machine.
- Neuro-imaging – best option is MRI with contrast, after discussion with a neuro-radiologist.
- Referral if indicated (based on MRI results) to neurology or neurosurgery.

### Long-term management

- Follow-up visual field testing as requested. Expect some



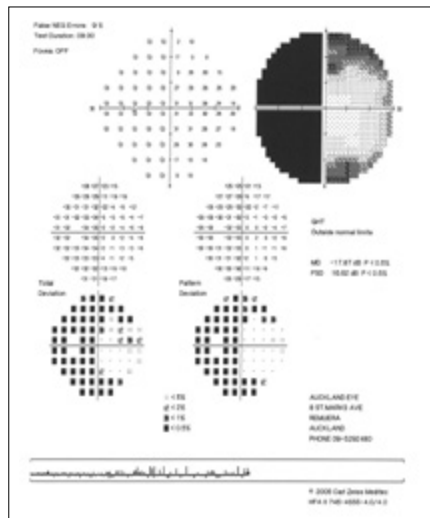
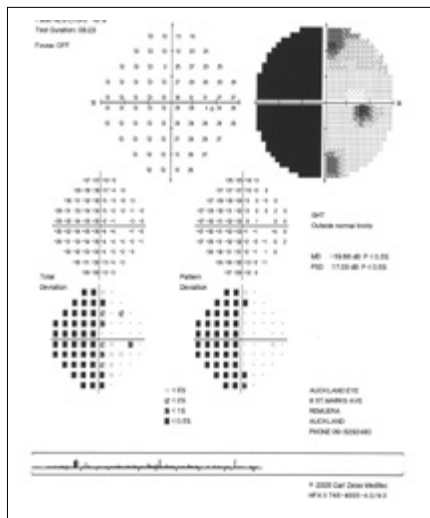
Retrochiasmal lesion that would typically give rise to homonymous hemianopia.

improvement after resolution of the acute cerebral oedema (that may initially surround the cerebral lesion).

- Additional testing of simultaneous, binocular visual field (Esterman Protocol), to help assess the fitness to drive.

## Referral guidelines

- Semi-urgent initial referral to ophthalmology for formal visual field testing.



Left-sided homonymous hemianopia.



## 16.8 Migraine

A migraine is characterised by throbbing head pain, accompanied by nausea, vomiting and photophobia. Blurred vision can precede the onset of headache symptoms by up to 60 minutes as an aura.

Commonly, patients describe the visual disturbance as flashing, zig-zagging, expanding lights that may be accompanied by expanding visual field defects. Patients often retreat to lie down in a darkened room, and symptoms usually abate over several hours. There may be familial tendency, and there may be certain triggers or precipitating factors.

### Symptoms

- As above with visual disturbance, nausea, vomiting and headache.
- A migraine should involve both sides. An exclusively unilateral migraine suggests other pathology and is an indication for imaging.
- Acephalic migraine (migrainous visual disturbance without headache) often occurs in older patients who have often experienced classic migraines when younger.

### Signs

- Often no signs except in complicated migraine (e.g. cerebral – neurological deficit; ophthalmoplegic – ipsilateral paresis of extra-ocular muscles; retinal – monocular vision loss of sudden onset).

### Immediate management

- Analgesia/NSAID and/or anti-emetics in response to patients' requirements. Some medications are given at the time of onset to reduce time course of migrainous attack.

### Long-term management

- Avoidance of precipitating factors – foods/medications/alcohol/stress/bright lights.
- Prophylactic medications if severe/frequent migraine attacks.

### Referral guidelines

- Routine referral to ophthalmology to exclude eye pathology.
- Routine referral to neurology clinic.
- Migraine should be a diagnosis of exclusion.



Visual disturbance typical of migraine.

## 16.9 Supranuclear Paresis (*Palsy*)

Supranuclear palsy is the result of brain lesions involving the motor control centres for eye movements, compared with isolated cranial nerve paresis, i.e. third, fourth, sixth.

Supranuclear palsy usually presents with sudden onset diplopia and gaze palsy (inability of the two eyes to look in the same direction at the same time) and associated neurologic signs, such as ataxia and somnolence. Vertical diplopia is usually due to thalamic lesions whereas horizontal diplopia is usually related to mid-brain/pontine lesions.

The most common aetiology would be CVA. Other causes include demyelination (MS) with a clinical presentation of inter-nuclear ophthalmoplegia (INO). Rarely the cause can be intracranial tumours, such as a pinealoma causing Parinaud's Syndrome.

### Symptoms

- Sudden onset diplopia – vertical or horizontal and occasionally nystagmus that may become progressive with time.
- Ataxia and somnolence.

### Signs

- Vertical or horizontal strabismus.
- Loss of vestibular-ocular reflex.

### Immediate management

Arrange neuro-imaging (MRI scan).

### Long-term management

Treatment of underlying cause and also tests to exclude diagnosis of chronic progressive external ophthalmoplegia (CPEO), a mitochondrial myopathy that typically manifests in young adult years. Ptosis is usually the presenting feature with an associated compensatory head posture to maximise the area of binocular single vision. Other diseases like Graves' disease, myasthenia gravis and glioma that may cause an external ophthalmoplegia must also be ruled out.

### Referral guidelines

- Immediate referral to neurology/ophthalmology.

## 16.10 Third Nerve Palsy

The third cranial nerve (CNIII) controls all the extraocular muscles except the superior oblique (cranial nerve IV) and the lateral rectus (cranial nerve VI). Additionally it supplies the levator palpebrae superioris and carries the efferent pupillary fibres.

Damage to the third nerve may occur anywhere along its pathway, but the most important clinical scenario is a compressive lesion due to a posterior communicating artery aneurysm, which presents with a complete third nerve lesion – ptosis + dilated pupil + eye pointing down and out. **THIS IS A MEDICAL EMERGENCY AND REQUIRES IMMEDIATE TRANSFER TO HOSPITAL.** This condition carries significant risk of morbidity/mortality from subarachnoid haemorrhage. It is sometimes referred to as a “surgical cranial nerve III lesion”, as opposed to a “medical cranial nerve III lesion”, in which the pupillary fibers are spared due to microvascular infarction of the motor portion of the cranial nerve III seen in patients with diabetes and hypertension.

### Symptoms

- Headache is often present.
- Sudden onset vertical and horizontal diplopia.
- Loss of vision from the ptosis.

### Signs

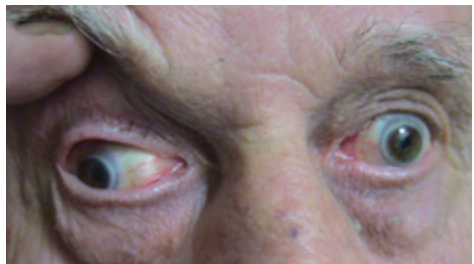- Ptosis.
- Limitation of eye movements with retention of lateral rectus and superior oblique function resulting in the classic “down and out” misalignment, which is only evident when the eyelid is manually elevated.
- Dilated pupil due to interruption of the efferent pathway.
- Partial signs may be observed during the evolution of the lesion.

### Slit lamp signs

A dilated pupil that fails to respond to light.

### Immediate management

- Pupil involved CNIII palsy requires immediate transfer to hospital



Right third nerve palsy with ptosis, and a “down and out” eye.

for urgent neuro-imaging to determine underlying pathology in particular to confirm/exclude an aneurysm.

- Pupil sparing CNIII palsy requires review at 1 week to determine that there has been no evolution to a pupil involving CNIII.

## Long-term management

### Ocular:

- Management of diplopia with prisms or occlusion.
- If deviation persists and cosmetically unacceptable and/or symptomatic can have strabismus surgery.

### Systemic:

- Treatment of underlying vascular conditions.

## Referral guidelines

Immediate referral of sudden onset strabismus and/or diplopia, especially for patient with pupil involved third nerve palsy (CNIII).

## 16.11 Fourth Nerve Palsy

This is the most common cause of vertical strabismus. The most common aetiology is congenital, or decompensation of a congenital fourth nerve palsy, with longstanding nature elicited from history, examining old photographs and measuring a larger than usual vertical fusional range.

Other causes include trauma, microvascular infarct, demyelinating disease and rarely tumour, giant cell arteritis, and hydrocephalus.

### Symptoms

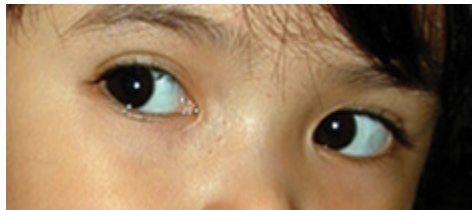- Binocular vertical diplopia, worse on downgaze and gaze to contralateral side to affected eye.
- Torticollis is a common presentation in childhood.

### Signs

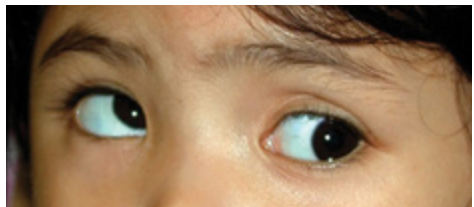- Patients frequently adopt a head tilt posture towards contralateral shoulder to maintain binocular vision.
- Cover test: small hypertropia in primary position that increases on gaze to contralateral side, and increases on head tilt to same side.
- Longstanding palsies of childhood onset frequently show facial asymmetry.

### Management

- Investigations including neuroimaging, ESR and CRP are directed by history and examinations. Treatment of acquired fourth nerve palsy is dependent on underlying cause.
- For congenital or longstanding disease, vision is maximised and any amblyopia attended to.



Right gaze. On gaze to the left there is elevation of the right eye compared to normal for both eyes on right gaze.




Left gaze.

Strabismus surgery is indicated for persistent diplopia, unacceptable abnormal head posture, or a strabismus that threatens visual acuity and binocular vision in the visually immature.

- For acquired palsies, treatment of diplopia with an eye patch or prisms on glasses will provide symptomatic relief until definitive surgery is performed (if required). Many can show spontaneous resolution.

### Referral guidelines

Patients with recent onset nerve palsy require urgent referral, and conversation of neuroimaging.



Typical tilted head position in fourth nerve palsy.

## 16.12 Sixth Nerve Palsy

Binocular horizontal diplopia, worse in the direction of the paretic lateral rectus muscle. The affected eye is unable to abduct (move laterally).

While this frequently occurs as an isolated deficit, coexisting neurologic signs and symptoms are critical for determining the location of the lesion.

### Symptoms

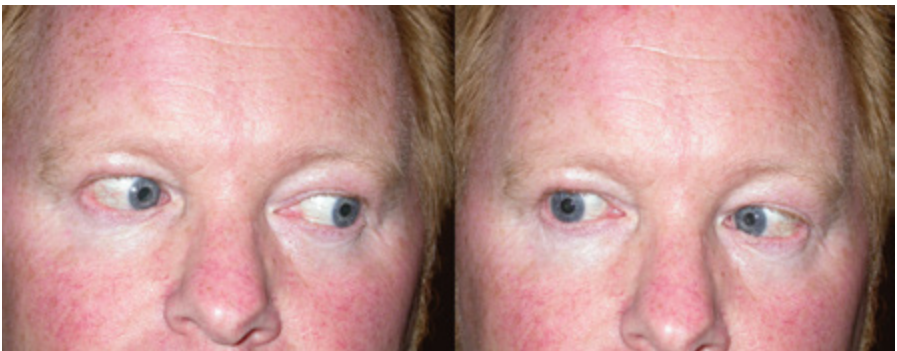- Horizontal diplopia.

### Signs

- Esotropia in primary position that increases with gaze towards the field of action of the paretic lateral rectus, and decreases with gaze in the opposite direction.

### Causes

- Childhood:
- Post-viral/post-vaccination, trauma, tumours, raised intracranial pressure, migrainous.
- Adulthood:
- Microvascular causes (diabetes, hypertension, and atherosclerosis) are common. Trauma, tumours, giant cell arteritis, and inflammatory causes are less common.



Sixth nerve palsy. Note normal movement of both eyes on left gaze then the incomplete movement of the right eye on right gaze.

## Differential Diagnosis

Other causes of abduction deficits include medial orbital wall fracture, thyroid eye disease, myasthenia gravis, orbital inflammatory disease, Duane's syndrome, Mobius syndrome, giant cell arteritis.

## Long-term management

- Complete neurologic and ophthalmic examination, with attention to other cranial nerves, including the fifth, seventh and eighth cranial nerves.
- Immediate ESR and CRP if suspicion of giant cell arteritis.
- Check and optimise risk factors for microvascular disease.
- MRI scan is indicated if associated with other neurologic signs, if the patient is young (< 55 years old), if there are no vasculopathic risk factors, for bilateral disease, or if there is papilloedema.
- All children require referral to the paediatric neurologist and neuroimaging.
- Treatment is based on the underlying aetiology.
- In children, visual acuity is maximised and amblyopia attended to. Alternate patching may help to prevent suppression of the vision in one eye with consequent amblyopia while time is given for investigations and recovery.
- Occlusion patch and prisms may relieve diplopia in the adult while recovery and progress is monitored.
- Microvascular sixth nerve palsy frequently recovers spontaneously within 3 to 6 months.
- In those that do not, strabismus surgery may be indicated after 12 months of stability.

## Referral guidelines

- Patients with recent onset nerve palsy require urgent ophthalmology referral.



## 16.13 Adie's Tonic Pupil Defect

This is a benign condition of sudden onset, presenting with a dilated pupil and sluggish response to light, usually related to viral ciliary ganglionitis. It often becomes bilateral and is more frequently seen in young females.

### Symptoms

- Often asymptomatic.
- Patient may notice anisocoria (difference in size of pupils).
- May experience photophobia and/or difficulty with reading.

### Signs

- Dilated or mid-dilated pupil unresponsive to light, but constricts on near effort.
- Diagnosis proven by hypersensitivity to weak pilocarpine 0.1% eyedrops, which will cause constriction of the affected pupil only.
- Long term, the affected pupil will become smaller and “tonic”.

### Slit lamp signs

- Irregular iris sphincter movements (vermiform) with bright illumination.

### Immediate management

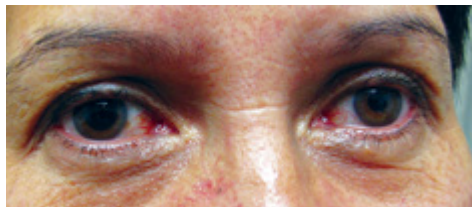- None indicated.

### Long-term management

- Pilocarpine 1% eyedrops can be used for blurred vision or where cosmesis is an issue.

### Referral guidelines

Non-urgent referral to ophthalmology. Patients will often notice anisocoria and may be unduly anxious due to media portrayal of pupil problems being indicative of neurological disorders.



Right dilated pupil compared to normal Left pupil

## 16.14 Horner's Syndrome

This is a condition that presents with unequal pupils (anisocoria), the smaller pupil being on the affected side (miosis). There is also ptosis, apparent enophthalmos and reduced sweating (anhidrosis).

It can be congenital due to, for example, brachial plexus injury at birth or acquired, with the underlying pathology being damage to the sympathetic nerve supply between the brainstem and the eye. Common aetiologies for acquired Horner's syndrome include CVA, tumours and vascular pathology.

### Symptoms

- Patients may complain of blurred vision, but usually notice the ptosis and miosis.
- Severe ipsilateral headache is reported if the aetiology is carotid artery dissection.

### Signs

- Miosis.
- Ptosis.
- Apparent enophthalmos.
- Cutaneous anhidrosis.
- Hypopigmentation of the iris in congenital cases.

### Immediate management

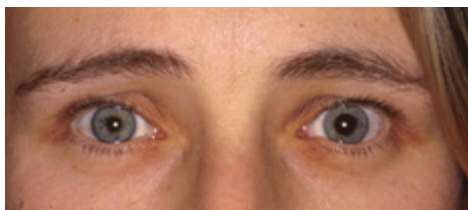- The diagnosis is confirmed with 2% cocaine eye drops to both eyes; the normal pupil will dilate. The alternative is iopidine eye drops.
- Look for localising conditions such as stroke (lateral medullary syndrome) and apical lung disease (Pancoast's tumour) in acquired cases.
- Imaging of the brainstem, neck, and mediastinum (MRI), with contrast and MRI.

### Long-term management

- Treat underlying aetiology.
- Surgical management of ptosis  
(See 6.5 Ptosis – Acquired on page 28).

### Referral guidelines

Semi-urgent referral is required to ophthalmology for acquired Horner's syndrome to confirm the diagnosis and arrange imaging.



Right Horner's syndrome with slight ptosis and smaller pupil compared to the normal left side.

## 16.15 Nystagmus

Nystagmus is rhythmic oscillation of the eyes described as either pendular (equal movements) or jerk (with slow initial movement and rapid recovery).

Congenital nystagmus presents within 6 months of age and is often associated with poor vision. It is usually horizontal and may have a “null position” where the eye movements are reduced

(See **20.6 Small Incision Lenticule Extraction (SMILE)** on page 316).

Acquired nystagmus suggests underlying brainstem pathology. It is usually a jerk form of nystagmus and upbeat nystagmus is associated with medullary pathology, whilst downbeat nystagmus is associated with craniocervical pathology (e.g. brainstem stroke/tumour).

### Symptoms

- Patients describe blurred vision rather than oscillopsia (visual disturbance in which objects in the visual field appear to oscillate).

### Signs

- Oscillation of the eyes can be observed directly.

### Slit lamp signs

- Some forms of fine nystagmus will be best seen with slit lamp examination.

### Immediate management


Acquired nystagmus requires neuro-imaging and exclusion of other causes including inflammatory, toxic, and metabolic disorders.

### Long-term management

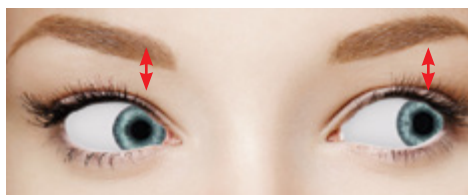Medications may be helpful to dampen down the nystagmus: Clonazepam/Baclofen with neurology supervision.

### Referral guidelines

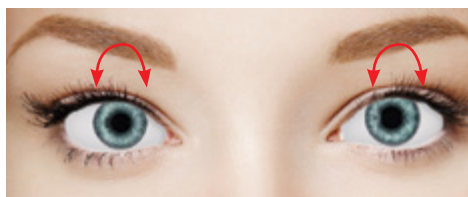- Acquired nystagmus requires urgent referral to ophthalmology or neurology.



Horizontal nystagmus.



Vertical nystagmus.



Torsional nystagmus.

## 16.16 Myasthenia Gravis

Myasthenia gravis (MG) is an autoimmune disease with impaired transmission across the myoneural junction, resulting in intermittent ptosis and diplopia.

If the disease only involves the ocular system, then it is referred to as “ocular myasthenia gravis”, but it can progress to involve the respiratory organs and is termed “generalised myasthenia gravis” with the potential for severe morbidity/mortality.

### Symptoms

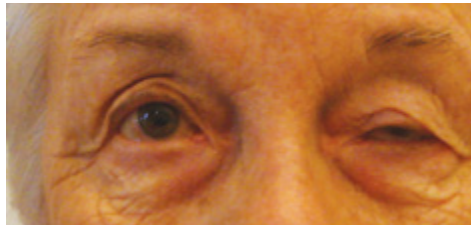- Diplopia from the variability of eye movements.
- Heavy feeling eyelids from the variable ptosis.
- Usually better in morning and worse later in day; fatigability is the hallmark of this condition.

### Signs

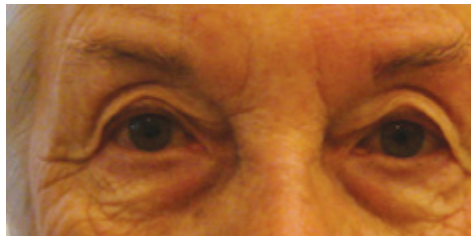- Ptosis, often worsening during the day or if tired.
- Weakness of orbicularis muscle.
- Lid twitch sign – seen after prolonged upgaze effort with the eyelid making a small deviation back up when the patient is asked to look directly ahead.

### Immediate management

- Confirmation of diagnosis with ice test, where crushed ice is placed over the closed eyes for 5 minutes, with resulting improvement in the degree of ptosis.
- Blood test for acetylcholine receptor antibodies.
- Tensilon (Edrophonium) test to show improvement in either the ptosis or eye movements.
- Single fibre EMG.



Patient with ptosis associated with myasthenia gravis before ice test.



Patient now showing complete resolution of the ptosis post ice test.

### Long-term management

- Treatment with Mestinon (physostigmine) and prednisone.
- Exclude thymoma with chest CT Scan – possible thymectomy.

### Referral guidelines

- Non-urgent referral to ophthalmology if ocular involvement only.
- Best managed by neurology long term, especially if additional immunosuppressive therapy is required and if generalised involvement.

## 16.17 **Blepharospasm** (*Benign essential Ocular Blepharospasm*)

Blepharospasm is intermittent or constant narrowing of palpebral fissure caused by contraction of orbicularis oculi muscle around the eye.

### **Symptoms**

- Excessive blinking initially, progressing to uncontrolled eyelid spasms.
- Worse with social interaction.

### **Signs**

- If unilateral facial weakness present consider hemi-facial spasm/Bell's palsy with aberrant regeneration or pontine disease.
- If bilateral and no other neurologic signs = essential blepharospasm (exclude neuro-muscular disease).
- Often will spread to involve other facial/cervical muscles with dystonic features.

### **Immediate management**

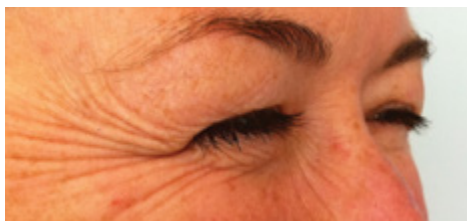- No indication for systemic medications.
- Neuro-imaging only required if other neurological symptoms/signs.

### **Long-term management**

- Local botulinum injections to peri-orbital lid skin with up to 12 weeks' relief.

### **Referral guidelines**

- Non-urgent referral to ophthalmology/neurology.



Uncontrolled blink in Blepharospasm.



## 17 *Oncology*

## 17.1 Ocular Oncology

### Uveal melanoma

Uveal melanoma is the most common primary ocular cancer in adults. The majority of tumours originate from the choroid (85%), followed by the ciliary body (5-10%) and the iris (5%).

### Choroidal melanomas

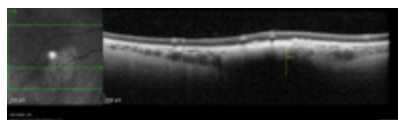
Choroidal melanomas can arise de novo or from pre-existing naevi, the latter present in 5-10% of the adult population. The reported incidence of choroidal melanoma in New Zealand is 13 new cases/million/year and is observed in older adults with fair skin. In contrast to cutaneous melanoma, choroidal melanoma has not been conclusively linked to high UV exposure.

### Risk factors

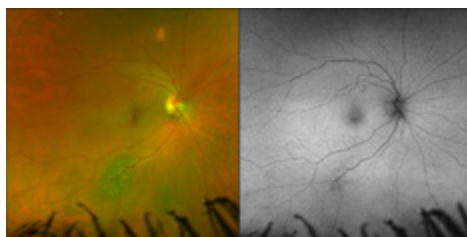
Age (>50 years), fair skin colour, light coloured eyes, congenital ocular melanocytosis, and those with tumour predisposition syndromes.

### Diagnosis

Approximately 30% of choroidal melanomas are detected during routine eye exams. The remainder present with blurred vision, flashing lights, or secondary complications from the tumour including retinal detachment, cataract, or neovascular glaucoma. Differentiating choroidal naevi from small choroidal melanoma can be challenging. Naevi are typically small and present as a minimally elevated, domed-shaped, brown coloured mass with irregular margins. They can also be minimally pigmented or amelanotic. The risk of naevi transformation to melanoma is 1:8845 per year, or 1% over the patient's life time. The diagnoses of choroidal is made clinically based on the presence of high-risk features, using the mnemonic **To Find Small Ocular Melanoma Do Imaging**. This refers to tumour **T**hickness of >2mm, presence of subretinal **F**luid, **S**ymptomatic visual loss (6/18 or worse), presence of **O**range pigment (lipofuscin), **M**elanoma acoustic hollowness on ultrasonography and **D**iameter >5mm based on photography.



Pigmented choroidal naevus, drusen on the surface but no orange pigment visible on widefield pseudocolour (A) or fundus autofluorescence imaging (B). The OCT image (C) confirms the lesion is in the choroid and measures approximately 800µm thick with no subretinal fluid visible.



A choroidal melanoma with orange pigment seen on widefield pseudocolour (A) and fundus autofluorescence imaging (B), with subretinal fluid visible on OCT (C) 4



The 5-year estimate of growth (implying malignancy) of a lesion can be predicted based on the number of risk factors present.

Risk factors	5-year estimate of growth
0	1.1%
1	11%
2	22%
3	34%
4	51%
5	55%

The assessment of tumour thickness and acoustic hollowness requires B-scan ultrasonography which is not available in most optometry and many ophthalmology practices. The MOLES grading system overcomes this issue. It was developed primarily to help optometrists estimate the likelihood of malignancy and whether referral to an ophthalmologist or ocular oncologist is required. The MOLES acronym is also based on clinical features including **M**ushroom shape (tumour broken through Bruchs membrane), **O**range pigment, **L**arge size >4 disc diameters, **E**nlargement over time and **S**ubretinal fluid. Each of these is scored as 0 if absent, 1 if subtle or uncertain, and 2 as present (see table 2).

Risk factor	Severity	Score
Mushroom shape	Absent	0
	Unsure	1
	Present	2
Orange pigment	Absent	0
	Unsure/trace	1
	Confluent clumps	2
Size (colour fundus photo)	<3 Disc Diameters (DD)	0
	3-4 DD	1
	>4 DD	2
Enlargement	None	0
	Unsure	1
	Definite	2
Subretinal fluid	Absent	0
	Trace (Detected on OCT)	1
	Definite (Visible without OCT)	2

The sum of these scores categorises a lesion as common naevus, low risk or high-risk naevus, or probable melanoma, with recommended management based on the total score (see table 3). This tool has been validated with high sensitivity for and specificity.

Score	Suggested management
0 = common naevus	Monitor in the community
1 = low risk naevus 2 = high risk naevus	Non urgent referral for specialist assessment/ monitoring
3 = probable melanoma	Urgent referral to ocular oncologist

Roelofs KA, O'Day R, Harby LA, Arora AK, Cohen VML, Sagoo MS, et al. The MOLES System for Planning Management of Melanocytic Choroidal Tumors: Is It Safe? *Cancers (Basel)*. 2020; 12 (5).

Finally, fundus photography is strongly recommended to document the baseline size and extent of all pigmented lesions, especially if the decision is made to observe the lesion by a community optometrist.

### Iris melanomas

Iris melanomas account for 5% of all uveal melanomas with several clinical variations recognised. Circumscribed iris melanomas typically present as a well-defined pigmented mass in the iris stroma and can result in changes to the pupil shape e.g. corectopia or ectopian uvae. The diffuse form is associated with iris discolouration (heterochromia) and the accumulation of pigment in the angle can result in secondary glaucoma.

### Diagnosis

Most patients are asymptomatic. The tumour is often detected by the patient, family members, or a health care professional. Old photos can be helpful to confirm growth of the lesion which is suggestive of melanoma over benign lesions such as iris freckles or naevi. Compared with iris naevi, melanomas are typically larger and more vascular, however differentiating the two can still sometimes be challenging. The ABCDEF guide can be helpful in identifying clinical factors predictive of naevus growth to melanoma:

- **A**ge  $\leq$  40 years
- **B**lood in the anterior chamber
- **C**lock hour (inferiorly)
- **D**iffuse configuration
- **E**ctropion uvae
- **F**eathery edges

## Management of uveal tumours

Baseline imaging should be acquired on all patients with naevi involving the uveal tract. Lesions which have been stable for years can be monitored by a community optometrist. New lesions, growth of preexisting lesions, or lesions exhibiting high risk features should be referred to an ocular oncologist.

Small non-growing iris melanomas do not require treatment and can be observed by an ocular oncologist. Lesions that exhibit growth usually require treatment with radiation therapy or surgery. Choroidal and ciliary body tumours are treated with plaque brachytherapy or enucleation. Lifelong surveillance for late distant metastasis is required, with the liver being the most commonly affected site.

## Congenital hypertrophy of the Retinal Pigment Epithelium (CHRPE)

Often mistaken for choroidal naevus or melanoma, these benign lesions are usually present at birth and exhibit slow growth over time. Solitary CHRPE are unilateral, flat, hyperpigmented lesions and often that often have large atrophic areas (lacunae) within the centre (Image A). The margins are well demarcated and typically exhibit hypoa autofluorescence (image B). In contrast to choroidal naevi, they are located at the level of the RPE confirmed on OCT imaging (C).

Grouped or multifocal CHRPE consist of a cluster of small lesions confined to one sector or quadrant of the fundus, and often resemble animal foot prints or “bear tracks”.

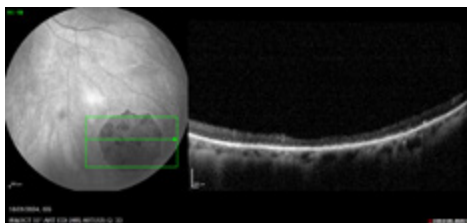
Atypical CHRPE or retinal pigment epithelial hamartomas associated with familial adenomatous polyposis (RPEH-FAP) are observed in patients with mutations in the APC gene which predispose them to colorectal cancer. These are usually characterised by multiple oval or round pigmented lesions in both eyes. These cases should be referred to an ocular oncologist for urgent assessment.

## Choroidal haemangiomas

These are benign vascular tumours of the choroid which can occur sporadically, or in association with other systemic associations. There are two main subtypes: circumscribed and diffuse, the latter observed in patients with Sturge-Weber syndrome. The circumscribed subtype appears as a red-orange mass located at the posterior pole. They can be easily overlooked and misdiagnosed as an amelanotic naevus or melanoma.

## Management

The decision to treat depends on the size, location and symptoms. Asymptomatic lesions can be observed, however symptomatic patients with subretinal fluid or macular oedema should be treated with photodynamic therapy +/- anti-VEGF therapy.

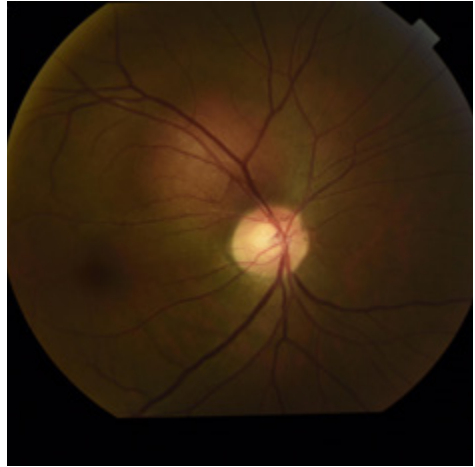


Solitary CHRPE (A/B/C)

## Ocular surface neoplasia

These lesions are observed in patients over 60. Fair skin, significant UV exposure, immunosuppressed patients/HIV and HPV virus are potential risk factors for this condition.

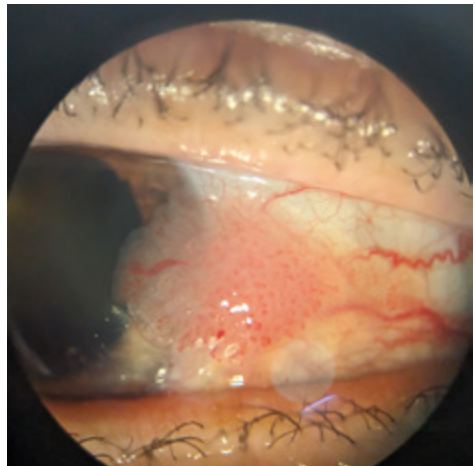
Often confused for pterygia, the typical appearance is of a gelatinous or plaque-like mass (leukoplakia) located in the interpalpebral conjunctival, with 95% involving the corneal limbus. Patients with corneal involvement can display a grey or frosted appearance.



Choroidal haemangiomas

## Management

Patients with OSSN or atypical pterygia should be referred for assessment. Medical and surgical options (or a combination) can be used to treat OSSN. Surgery involves complete excision with adequate margins performed using a 'no touch' technique. Alcohol assisted kerato-epitheliectomy and lamellar sclerectomy are usually required, along with cryotherapy to the surgical margins. Topical chemotherapy is often required as the recurrence rate after surgery is high. In some centres, topical chemotherapy can be used as the primary mode of treatment.



Ocular surface neoplasia

## Pigmented conjunctival lesions

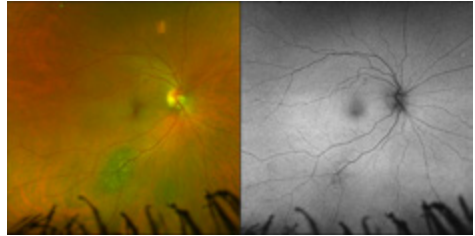
Most pigmented lesions involving the conjunctiva are benign. These include conjunctival naevi and complexion associated melanosis. Conjunctival naevi appear in the first two decades of life and become darker during puberty or pregnancy. They are well circumscribed and can often have cysts within them (IMAGE). Complexion associated melanosis also known as racial melanosis, is found amongst darkly pigmented individuals at the corneal limbus.

Conjunctival melanomas can arise spontaneously (de novo) or from pre-existing lesions such as primary acquired melanosis or naevus. Patients are generally over

60, and the lesions have a nodular appearance with feeder vessels. The most common location is the limbus, but they can also appear in the caruncle, tarsus and fornix.

### Management

Incisional biopsies should be avoided to prevent tumour seeding. Excisional surgery is required with techniques similar to those used in treating OSSN. Recurrence rates are high, and adjuvant topical chemotherapy is required. New pigmentation must not be ignored, and the eyelids should be everted as recurrences can be found distant to the primary site.



Tarsal conjunctival naevus with cystic changes visible within the lesion



## **18** *Orthoptics*

## 18.1 Orthoptic assessment

Orthoptists are health care professionals specialised in investigation, diagnosis and management of binocular single vision disorders, eye movements and visual development.

Their assessment is typically needed for paediatric patients to ensure the development of their binocular vision, eye motility and alignment. When treatment is needed, orthoptists monitor amblyopia treatment and any eye alignment disorder/ strabismus. In case of misaligned eyes, binocular diplopia, nystagmus or reduced eye movement, adult patients would also require such an assessment. Orthoptists are in charge of taking accurate measurements of eye deviation, and eye movement evaluation. These measurements are essential to monitor the progression of these eye conditions and provide adapted treatment hand in hand with the specialist.

### Treatments vary from one patient to the other:

- For strabismus surgery, the orthoptist supports the specialist providing the most accurate measurements to plan the correction.
- For amblyopia treatment, the orthoptist monitors the paediatric patients regularly to measure the vision, track the evolution and implement or adjust treatment as need.
  - with the specialist overview.
- Double vision, depending on its cause, is addressed with different treatments (surgical, prism, occlusion).
- For other disorders as convergence insufficiency or accommodation deficit, the orthoptist can prescribe specific eye exercises.

### Orthoptists at Auckland Eye

Here at Auckland Eye, we have 2 amazing orthoptists;

#### **Federica (Fefe) Ferruzzi and Aurélie Delhommais.**

First time appointments for strabismic or amblyopic eye conditions, are seen by an orthoptist, and then followed with an appointment with a specialist, ideally on the same day.

### Paediatric appointments

A paediatric appointment typically last around 1 hour and 30 minutes. This includes a 30 minute consultation with the orthoptist, followed by the instillation of dilating drops that will take at least 30 minutes to work, and then a consultation with the specialist.

### Adult appointments

An adult appointment will last around 1 hour and 30 minutes to 2 hours. This includes a 1 hour consultation with the orthoptist, followed by any additional test that may be required.





## 19 *Paediatrics*



## 19.1 Amblyopia

This is the decrease in visual acuity caused by a disruption to normal visual experience during the critical period of vision development.

### Normal Vision Development

- Visual acuity: increases exponentially in first months of life: approximately 6/30 at 6 months old, 6/15 at 1 year old, 6/6 at 3 years old.
- Central fixation, smooth pursuit: usually established by 2–3 months old.
- Critical period of visual development: occurs between birth and around 8 years of age. The younger the patient, the more vulnerable to disruption of vision, fusion and stereopsis.
- Any abnormality of the visual system that would interfere with a clear image falling on the fovea, or any misalignment of the eyes that interferes with normal binocular vision, may cause permanent damage to the system if left untreated in a visually immature person (<8 yo).

### Aetiology of amblyopia:

#### Unilateral

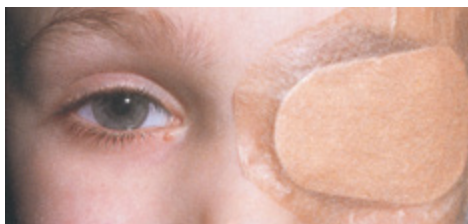- Strabismus.
- Anisometropia – a difference in the focusing error between the two eyes
- Vision deprivation – media opacities, ptosis (occlusion amblyopia).

#### Bilateral:

- High bilateral focusing errors.
- Vision deprivation.

### Signs and symptoms

- Reduced vision often identified at school screening test.
- Parents may mention that their child sits close to the TV, “can’t see as well as their siblings”, teachers may also make same comment or that there are learning issues.
- Strabismus.
- Ptosis.



Amblyopic child undergoing patching treatment.  
Note the stronger eye is patched.

## Immediate management

- Assessment to find cause for reduced vision, i.e. focusing error, strabismus, ptosis, etc.
- Treatment of the cause of amblyopia, i.e. prescribe glasses +/- occlusion.

## Long-term management

- Correction of the cause of amblyopia, such as glasses for focusing errors.
- Occlusion therapy – patching the preferred or stronger eye for several hours of a day
- Atropine penalisation – usually given as gutt. Atropine 1% one drop to the stronger eye every alternate night, to blur the vision in the better eye.
- The PEDIG (Paediatric Eye Disease Investigators Group) studies in the US have provided good objective data on patching protocols and have shown comparable effectiveness with patching or atropine penalisation for mild to moderate amblyopia. Patching still tends to be the mainstay of treatment although atropine penalisation can be used if there are compliance or cosmetic/social issues.

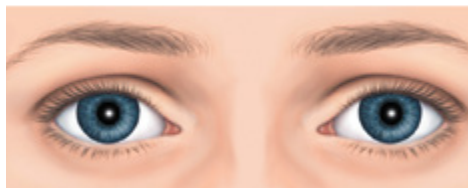
## Referral guidelines

- Amblyopia is most successfully reversible during the critical period of vision development. Early referral is therefore crucial for success.

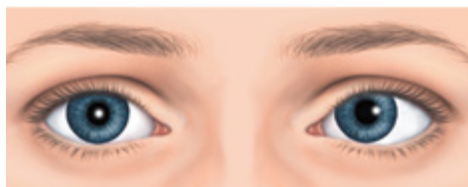## 19.2 Childhood Esotropias

A condition where the eyes turn inwards, also known as a convergent squint. This is a group of conditions that includes:

- Congenital esotropia.
- Accommodative and partially accommodative esotropia.
- Non-accommodative esotropia.
- Sensory esotropia.
- Pseudo-esotropia.
- Distinguishing features
- Congenital esotropia – constantly manifest, large angle esotropia arising in first 6 months of life.
- Accommodative esotropia – onset usually between 18 months and 3 years old. May be constant or intermittent. Caused by excessive convergence in a child with hypermetropia (long-sightedness) and usually most noticeable when the child focuses at a near target. Positive family history is common.
- Non-accommodative esotropia – may be constant or intermittent, and is caused by decompensation of fusional mechanisms. Rarely associated with CNS pathology.
- Sensory esotropia – occurs as a result of vision loss in the turned eye.
- Pseudo-esotropia – where there is no true strabismus, and the apparent deviation is caused by the lid contour, or a prominent epicanthal fold or a broad base of nose.
- Incomitant esotropias – where the angle of deviation varies with direction of gaze, such as sixth nerve palsy, medial orbital wall fracture, consecutive esotropia following surgery for exotropia, Duane's syndrome (See **19.4 Strabismus Syndromes** on page 276).



Normal eyes.



Left eye turned in with esotropia.

## Immediate management

- Establish diagnosis by history and examination.
- Maximise vision by correcting focusing errors with glasses, and reversing amblyopia with occlusion therapy or atropine penalisation.
- The deviation in accommodative esotropia is fully corrected with glasses alone. The strabismus is, however, still frequently seen when glasses are removed.
- The deviation in congenital esotropia, partially accommodative esotropia and non-accommodative esotropia is corrected with strabismus surgery.
- Patients with sensory esotropia and non-accommodative esotropia need the underlying cause of their loss of vision or fusion identified and, if possible, treated, prior to amblyopia treatment and surgery.

## Referral guidelines

- All children with strabismus should be referred.
- A child with sensory esotropia, particularly those with suspected retinoblastoma, cataract, nerve palsy or unexplained loss of vision requires urgent referral.

## 19.3 Childhood Exotropias

A condition where the eyes turn outwards, also known as divergent squint

**This group of conditions include:**

- Intermittent exotropia.
- Congenital exotropia.
- Convergence insufficiency.
- Sensory exotropia.
- Incomitant exotropias.

**Distinguishing features**

**Intermittent exotropia:**

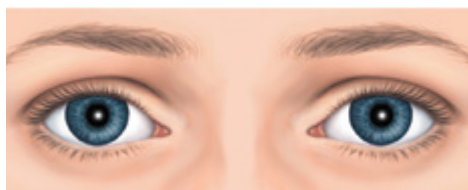
- the most common type of exotropia in childhood, with onset from infancy to around 4 years old. The divergence of visual axis is intermittently controlled by fusional mechanisms, so that the strabismus is initially only noticed when the child is tired, sick or daydreaming. In the majority of children, the frequency and duration increases over time, and is usually most noticeable with distance fixation. Occasionally, the frequency of the deviation remains constant, and on rare occasions, it may decrease.

**Congenital exotropia:**

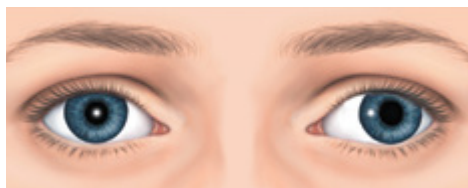
- a constant large angle exotropia, with onset at birth. Rare, with a high association with neurological and developmental abnormalities.
- Convergence insufficiency: a subset of intermittent exotropia that is manifest at near, and reflects the inability to maintain convergence on a near target. More common in teens and usually presents with diplopia or eye strain symptoms with reading.

**Sensory exotropia:**

- the divergence of an eye with poor vision.
- Incomitant exotropia: where the angle of deviation varies with direction of gaze, and includes third nerve palsy, Duane's syndrome (See 19.4 Strabismus



Normal eyes.



Left eye turned out with exotropia.

*Syndromes on page 276*), and consecutive exotropia that follows surgical overcorrection of an esotropia.

### Immediate management

- Intermittent exotropia: Visual acuity and binocular vision is typically maintained, so amblyopia treatment is not usually necessary. Children are regularly reviewed, and when the frequency of the strabismus increases to the point when binocularity is threatened, then strabismus surgery is performed. The age when surgery is performed is typically 4–5 years old.
- Congenital exotropia: Requires referral to paediatrician, and neuroimaging is frequently necessary. The deviation is corrected with strabismus surgery, though the prognosis for binocular vision is poor.
- Convergence insufficiency – this responds well to orthoptic exercises.
- Sensory exotropia/Incomitant exotropia – these patients need the underlying cause of their loss of vision and incomitance identified and, if possible, treated, prior to amblyopia treatment and surgery if indicated.

### Referral guidelines

- All children with strabismus should be referred.
- A child with sensory exotropia, particularly those with suspected retinoblastoma, cataract, nerve palsy or unexplained loss of vision requires urgent referral.

## 19.4 Strabismus Syndromes

These are a group of uncommon motility disorders that have characteristic features.

### Duane's syndrome

Due to a congenital miswiring of the medial rectus and lateral rectus muscles in one or both eyes causing:

- Globe retraction on attempted adduction, caused by co-contraction of medial and lateral rectus, and therefore narrowing of the palpebral aperture on attempted adduction.
- Limitation of adduction (Type 1), or limitation of abduction (Type 2), or both (Type 3).
- The eyes are frequently straight in the primary position, or there is a small deviation only.
- The patient may take up a slight face turn head posture to maintain binocular vision.
- Visual acuity is typically good, and amblyopia is uncommon.

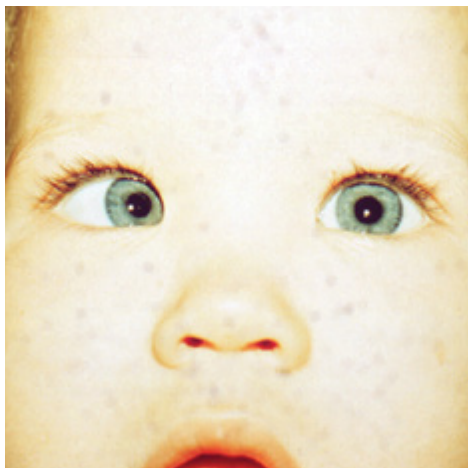Most do not require surgery.

Indications for surgery include a cosmetically unacceptable deviation in primary position or abnormal head posture, and the “up-shoot” or “down-shoot” of the eye caused by an anomalous vertical movement of the eye that occurs in side gaze when the tight muscles slip over the globe.

Some children have other congenital abnormalities, including sensorineural hearing loss, and cervical spine abnormalities.

### Brown's syndrome

This syndrome is thought to be caused by a tight or restricted superior oblique tendon. Causes include congenital, superior oblique tenosynovitis (associated with rheumatoid arthritis, SLE,



Child with left Duane's syndrome – the left eye does not look left on attempted left gaze (the right eye moves normally).

sinusitis), trauma and iatrogenic (after superior oblique tendon surgery, retinal detachment surgery).

- Hypotropia in primary position that increases on adduction, decreases on abduction.
- Limitation in elevation of the eye in adduction.
- Positive forced duction test (where the limitation to elevation is felt during attempted passive movement of the globe with forceps).

Treatment includes addressing the underlying cause, systemic anti-inflammatory drugs, local steroid injection. The deviation may improve with the course of the underlying disease. Surgery is indicated for a significant deviation in primary position or a significant abnormal head posture.

### **Congenital ocular fibrosis syndrome**

A rare restrictive strabismus secondary to fibrous replacement of the extraocular muscles, causing variable single or multiple muscle involvement, and characterised by limitation in elevation of eyes with ptosis.

### **Mobius syndrome**

Congenital aplasia of the sixth and seventh (+/- ninth and twelfth) cranial nerve nuclei, causing esotropia with limitation in abduction of the eyes, expressionless face, inadequate lid closure and risk of exposure keratopathy. Patients may have feeding difficulties.

### **Nystagmus blockage syndrome**

This is characterised by an esotropia that occurs with a horizontal nystagmus, where the convergence of the eye is thought to dampen the nystagmus. A face turn head posture is frequently adopted. Management is surgical though unpredictable.

### **Referral guidelines**

- All patients with suspected strabismus syndrome should be referred.



## 19.5 Strabismus Surgery

### Principles

Strabismus is not usually an “eye muscle problem”. With the exception of muscle palsies and restrictive problems, most strabismus is caused by a weakness in the fusional system. Eye muscle surgery aims to improve the position of the eyes to make it easier for this weak fusional system to keep the eyes aligned.

The eye that is turned is the non-dominant eye. It is not necessary to operate only on this eye. The purpose of the surgery is to improve the alignment between the two eyes and, with some exceptions, it typically doesn't matter which eye is operated on – in fact it is most common for surgery to be split between the two eyes. Surgery to partially palsied muscles may be helpful but if the muscle is completely paralysed surgery will be ineffective. The amount of surgery is based on the pre-operative assessment of the amount of misalignment because one cannot judge alignment when the patient is anaesthetised.

### Types of surgery

#### 1 Weakening muscles

- Recession – the muscle is moved posteriorly from its original insertion and reattached to the sclera. This is the commonest weakening procedure. A recession of the medial recti is done to correct an esotropia for example. The more posteriorly the muscle is moved the greater the weakening effect.
- Myectomy – a piece of the muscle is removed. This is done only to the inferior oblique muscle as it will retain some function through its muscle sheath.
- Tenotomy – a tendon is divided. This is sometimes done to weaken the superior oblique tendon.
- Tendon-spacer – this is a graded weakening of the superior oblique tendon whereby a length of silicone band or non-absorbable suture material is placed between the cut ends of the tendon.
- Posterior fixation/Faden suture – a non-absorbable suture is used to secure the muscle to the scleral wall at least 15 mm posterior to the limbus. This limits the action of the muscle in its direction of action without altering the position of the eye in the primary position. This technique is used on one eye to match a weakness on the other in order to maximise the zone of single vision.
- Suturing to the orbital wall – this is the most profound weakening procedure and involves removing the muscle from the eye completely and securing it to

the orbital wall. This is only done in extreme situations such as with a lateral rectus for a complete third nerve palsy with a large exotropia.

## 2 Strengthening muscles

- Resection – a suture is placed across the muscle a measured distance posterior to the insertion and the muscle between the suture and the insertion is excised. The muscle is then re-sutured to the original insertion. A resection therefore shortens/tightens the muscle. A resection of the lateral recti may be used to correct an esotropia. The greater the length of muscle removed the greater the effect.
- Tuck – the superior oblique tendon may be tightened by folding it over and securing the fold with a non-absorbable suture.

## 3 Re-positioning/transposing muscles

- Transposition procedures for muscle palsies – with a complete sixth nerve palsy, the entire or just the lateral halves of the superior and inferior recti may be moved adjacent to the lateral rectus insertion in order to provide some abducting power.
- Vertical transposition of the horizontal recti – if an esotropia is more marked in upgaze or downgaze then the horizontal recti can be transposed vertically (usually just a half tendon-width) at the time of recession or resection to ensure that this difference is accounted for.
- Temporal transposition of the anterior half of the superior oblique tendon/the Harada-Ito procedure – torsional diplopia is a common problem with acquired superior oblique palsy and this procedure can increase the intorsion power of the superior oblique and correct the double vision.
- Nasal transposition of the inferior recti – tight inferior recti, in thyroid eye disease for example, often cause significant torsion and this can be corrected by nasally transposing the muscle when it is recessed.

## Pre-operative assessment

To successfully correct a misalignment it may be necessary to deal simultaneously with horizontal, vertical and torsional/rotational aspects. The degree of misalignment is measured with prism cover tests. This involves cover testing with varying strength prisms until the correctional movement on the cover test is neutralised. The strength of prism required to achieve this defines the angle of deviation in “prism dioptres”. To establish a comprehensive surgical plan these measurements may need to be documented in up to 9 different gaze positions at both near and distance.

Surgeons use age-related tables to translate the measurements in prism dioptres into millimetres of recession or resection of the muscles. There are many

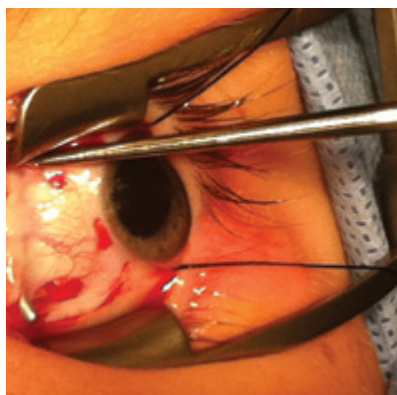
published tables which an experienced surgeon will have adapted to his/her own surgical technique.

## Types of anaesthesia

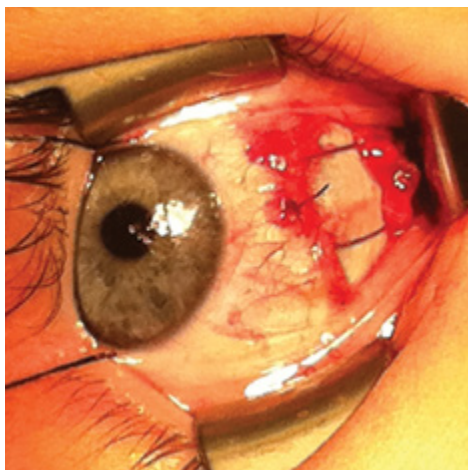
- General anaesthesia is used for children and commonly in adults also.

Local anaesthesia is suitable and well-tolerated for adults when only one eye is being operated on. The type of anaesthesia is the same as that used for [Cataract Surgery](#) and ensures that as well as being numb the eye muscles are paralyzed and the vision blocked.

Adjustable suture surgery: for adults, particularly when surgery is aiming to correct double vision, having the option of adjusting the eye position with the patient awake may be invaluable. This surgery requires a general anaesthetic to place the muscle in what is expected to be the most appropriate position but instead of the muscle suture being knotted it is secured on a bow. The patient is woken up and allowed to recover for at least an hour or two. The alignment of the eyes is checked and the muscle suture can be tightened or loosened to fine-tune the outcome. The adjustment is done with topical anaesthesia and often some intravenous sedation or analgesia. There is still the potential for some change during the healing period but the technique does increase the likelihood of a successful outcome.



Accessing the medial rectus muscle – note how the squint hook is looped around the muscle.



The medial rectus is moved back from its site of insertion.

## Post-operative care

- Simple analgesics, such as Paracetamol, taken regularly over the first 3–4 days, are recommended for comfort.
- Topical antibiotics and steroid eye drops may be prescribed for the first 1–2 weeks in some patients.
- Swimming should be avoided for the first 1–2 weeks.
- Reading and use of the eyes, such as with electronic devices may continue as per patient comfort.

Reviews are typically performed at one week and 6–8 weeks post-surgery, and it is not until the later appointment that the outcome can be considered stable.

## Risks with strabismus surgery

- General anaesthetic risk – with an experienced anaesthetist, excluding children in the first 2 months of life, the risk of death from a general anaesthetic is approximately 1:200,000.
- Visual loss is extremely rare but could occur through an intraocular haemorrhage or infection. Few surgeons will encounter even one case of this in their practising lifetime.
- Infection outside the eye involving the orbit or conjunctiva is rare with an incidence of approximately 1:1000.
- Redness, light sensitivity and over-watering invariably occur but are usually mild and resolve slowly over a few weeks.
- Scarring of the eye – occasionally there is persistent redness of the conjunctiva over the area where strabismus surgery has been performed.
- Unsatisfactory alignment at the 2-month post-operative check. The likelihood of this varies with the type of strabismus but it is not uncommon for another procedure to be required and this should be understood by the patient or family before the initial surgery is contemplated.
- Recurrence of strabismus – because many of these patients have an underlying fusional weakness the eyes may wander again over time and further surgery may be required long term.

## 19.6 The Child Who Does Not See

Vision in children develops over the first few months and by 2–3 months most children are visually attentive and fixing and following reliably.

Delayed visual maturation can occur with the normal response not developing until 6–9 months of age. In approximately a third of these cases the child is otherwise normal, in a third there is an established systemic/congenital/chromosomal abnormality such as cerebral palsy, Down's syndrome, etc., and in a third there is a more subtle underlying problem but delay in other areas will occur also. An assessment by a paediatrician is appropriate for all these cases.

### Signs

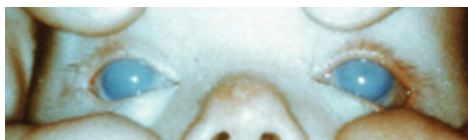Eyes look “unfocused”, no fix-and-follow response, not visually attentive.

### Immediate management

If a child clearly does not see, with no fix-and-follow, and wandering “unfocused” eyes then you should confirm with a red reflex test that the ocular media are clear. An assessment by a paediatric ophthalmologist is required. There are many potential causes including incomplete development of the retina or optic nerve or neurological abnormalities. Further investigation with MRI scanning or electrophysiological testing of the retinal function may be warranted. The latter involves flashing patterns of light into the eyes and assessing the retinal response via electrodes placed on the eyelids. This can be done under general anaesthetic for young children.

### Referral guidelines

Urgent referral to paediatric ophthalmologist.



Cloudy corneas leading to long term poor vision.

## 19.7 Vision Problems – Overview

### Vision problems

For children who fail a screening test, a fuller assessment is warranted. For the over-5 age group this may be done by a community optometrist. For families with a community services card there is an annual subsidy for assessment and spectacle costs. For the under-5 age group, and if the option is available, then review by an ophthalmologist or the hospital ophthalmology department is preferable.

### Focus problems / Refractive Errors

#### Assessing the focus in children

Cycloplegic refraction is the term for checking the focus with drops in the eyes that paralyse the accommodative system. Cyclopentolate is the commonest drop used and relaxes the focusing muscle and dilates the pupil. The drops take 30–40 minutes to work and last 12–24 hours. The ophthalmologist uses a retinoscope, which is a hand-held instrument used to bounce light off the retina. In conjunction with different strength lenses, assessment of the reflected light allows accurate measurement of focusing errors in the eye, even in very young children.

Very dark eyed children respond poorly to cyclopentolate and atropine may be required. This is put in for 3 days prior to the appointment and takes 2–3 weeks to wear off.

#### Short-sightedness/myopia

This is becoming an increasingly prevalent condition among school aged children, and can present with difficulty seeing distant targets clearly. There is frequently a familial tendency and an association with prolonged near tasks such as reading and use of electronic devices. It can continue to progress throughout childhood and teenage years, typically stabilising in the late teens. High myopia of more than  $-6.00$  dioptres may be associated with a higher risk of retinal detachment, macular disease, glaucoma and cataract. While myopia cannot be reversed, there are now several proven interventions that may help to slow the rate of progression to reduce the chance of reaching high myopia. (See [Myopia \(nearsightedness\)](#) on page 309)

#### Long-sightedness/hyperopia

Children are typically hyperopic at birth, with the degree gradually decreasing with growth and frequently disappearing around 7–8 years of age. Many children with mild to moderate degrees can overcome the hyperopia with focussing effort. If the effort is too great, then the visual acuity may be reduced leading to a risk of amblyopia. High hyperopia can stimulate so much focussing effort that the child develops a convergent squint, known as refractive or accommodative esotropia.

## **Astigmatism**

This occurs when the focussing surfaces of the eye (cornea / lens) has an irregular shape, often likened to a rugby ball, where the curve in one meridian is steeper or flatter than the other. This can cause a shadowing or distortion of letters. Infants often have a degree of astigmatism that lessens as they approach 4–5 years of age. In some children it may persist throughout their lives. High degrees can cause amblyopia, so glasses may be necessary.

## **Anisometropia**

This refers to a difference in focus between the two eyes, such as one eye being more hyperopic than the other. Anisometropia is a potent stimulus of amblyopia. Identifying this early during the critical period of vision development, well before age 8, and correcting with glasses is critical.

## **Symptoms**

Reduced vision, usually detected on routine screening or because of a family history.

## **Signs**

Vision less than 6/9 in either eye under the age of 5, or a difference of two or more lines on the vision chart between the two eyes warrants review. With less clear cut cases reassessment in 6 months is reasonable.

## **Long-term management**

Most children who are put into glasses need to wear them full time to prevent or treat amblyopia. In some circumstances glasses may become optional from the age of 8 or 9.

Contact lenses are used only in specific circumstances in children under 12 years.

## **Referral guidelines**

Children over 5 who fail vision screening should be referred to a community optometrist, while those under 5 should see an ophthalmologist or be referred to the hospital ophthalmology department.

Assessment by optometrists or ophthalmologists in the private sector, and the cost of obtaining glasses, is subsidised for children with a community services card.

## 19.8 Watery Eyes in Children

Children are commonly born with incompletely patent tear ducts. This will lead to excess watering and stickiness. If the duct is totally blocked then tears build up in the lacrimal sac and bacteria will proliferate.

This leads to discharge in the eye. The eye itself very rarely becomes infected and there is no threat to visual development. The lid may become quite inflamed and sensitive, however, and the appearance is socially problematic. Children are sometimes declined attendance at daycare, which is unnecessary as they are not contagious.

### Symptoms

Excessive tearing (epiphora) and recurrent discharge.

### Signs

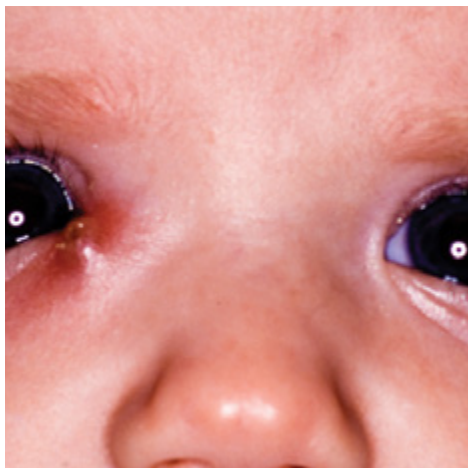- An increased tear level in the eye.
- Discharge.
- Eyelid erythema.

### Immediate management

- Treatment is supportive with moist warm tissues/facecloth to clear away any discharge and occasional brief courses of topical Chloramphenicol or Fucidic acid if it is particularly mucky. The parents should understand that antibiotics are not curative but only settle things briefly.
- Massage is difficult to perform adequately as the lacrimal sac is in the medial orbit rather than on the side of the nose. Children will object to it as it is uncomfortable for them. Massage may expel the contents of the sac out through the puncta, and therefore provide a temporary improvement, but it will not unblock the tear duct.

### Long-term management

- 95% of congenitally obstructed tear ducts will resolve



Congenitally blocked nasolacrimal duct with infection of the sac.

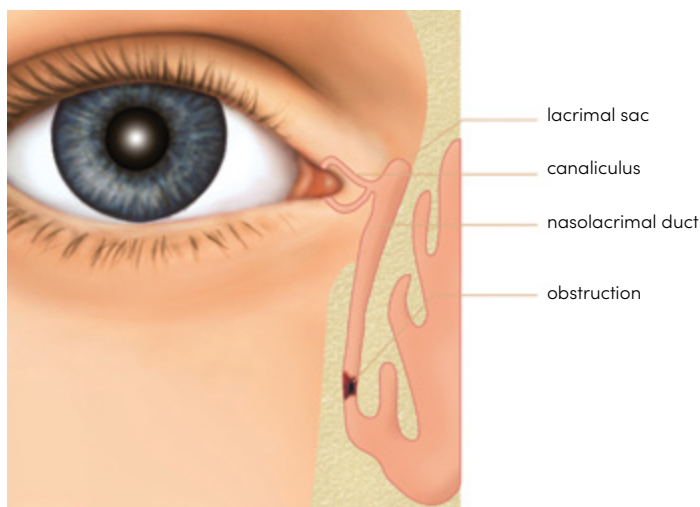


spontaneously by 12 months so we prefer to delay surgical probing of the ducts until the child is over a year old. Generally if families understand this they are happy to wait. Occasionally the problem is severe enough to justify earlier intervention.

- Probing is performed under general anaesthesia, takes about 15 minutes and is quite atraumatic. Drops are usually recommended for a few days post-op to clear away any residual infection. The success rate is 80–90%. The next option is to repeat the probing and place silicone tubes down the duct for several months to prevent it closing again. Another anaesthetic is required to remove the tubes.

### Referral guidelines

Only refer if the watering persists beyond 12 months of age or if the eyelid is severely inflamed from a constant discharge.



Congenital nasal lacrimal duct obstruction.

## 19.9 Blinking Eyes

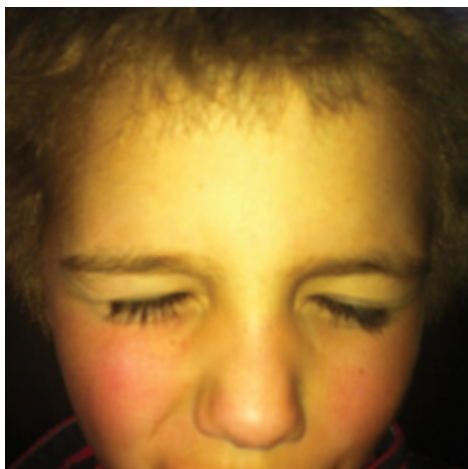
Frequent blinking is common for children. It is rarely due to any significant problem though it can be quite disturbing for parents. It may arise from a brief irritation/scratch/dry area and then becomes a habit.

It's not unusual for it to last several months. No particular treatment is required unless the eye is uncomfortable, in which case artificial tears can be tried on an as required basis. Remember though that drops are rarely tolerated well by children.

### Referral guidelines

Occasionally there is an underlying allergic problem, latent squint, or focusing problem, so if it persists beyond 4–6 months then an assessment to rule these out is recommended.

Closing one eye in particular, rather than blinking, can be a sign of a fusional weakness (latent squint) or vision problem and warrants assessment by an optometrist or ophthalmologist.



Child with pronounced blink

## 19.10 Abnormally sized eye

A large eye always raises concern about infantile glaucoma and urgent assessment is required. Sometimes it is due to megalocornea, a non-progressive congenitally increased corneal diameter. These children have a definite but low risk of glaucoma and need long-term monitoring.

A small eye suggests a structural developmental abnormality, which will sometimes have serious implications for visual development. These children need assessment.

Parents may say a child has a small eye when in fact they are noticing a ptosis with less of the eye visible on one side. A ptosis can be a cosmetic problem but is amblyogenic only if the lid is low enough to partially or fully cover the pupil. Vision threatening ptosis is operated on in the first few months of life while those that are more of a cosmetic problem are left until the child is over 3 years of age.

### Referral guidelines

Mild ptosis which is not amblyogenic is of no concern, but any true size difference between the eyes needs prompt assessment by an ophthalmologist.



Right microphthalmos.

## 19.11 Childhood Nystagmus

Nystagmus is a rhythmic, involuntary, to and fro movement of the eyes. Nystagmus of congenital onset is typically of benign origin. Acquired forms require investigations. The aims of the history and examination are to answer:

1. Is it congenital or acquired?
2. Is there visual loss?
3. Is there CNS disease?

### Symptoms

#### Congenital motor nystagmus

The defect is in the efferent pathways for motor control of eye movements and fixation.

Presents at birth or soon after, and persists throughout life, though may diminish with time.


Typically horizontal, uniplanar and conjugate (eyes move together).

Amplitude and frequency varies in different positions of gaze, increasing with distance fixation, decreasing at near with convergence, and may have a "null point". where the nystagmus dampens in one direction of gaze.

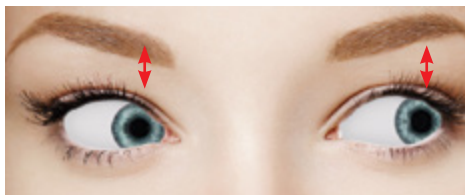The patient may adopt an abnormal head posture to achieve better vision if there is a null point.

No oscillopsia (no subjective oscillation of the environment due to the oscillating eye movements).

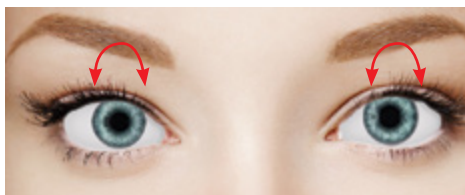Visual acuity is limited by the movement, though is frequently enough to allow mainstream schooling.



Horizontal nystagmus.



Vertical nystagmus.



Torsional nystagmus.

### Latent nystagmus

Congenital, conjugate nystagmus that occurs under conditions of uniocular fixation, such as when one eye is covered. Frequently associated with infantile strabismus.

Becomes manifest with both eyes opened in patients with history of strabismus, where one eye is suppressed.

### Sensory nystagmus

Secondary to poor vision arising from ocular or optic nerve disease.

Onset usually after 10 weeks old, and before 2 years old.

Causes can include cataract and other media opacities, high refractive (focusing) errors, foveal hypoplasia, albinism, optic nerve hypoplasia, optic atrophy, retinopathies such as Leber's congenital amaurosis.

Requires paediatric assessment and investigations usually include neuroimaging and electrodiagnostic testing.

### Spasmus nutans

Acquired nystagmus that may have a benign self-limiting course, with onset in infancy, and resolving within 2 years. However, this clinical appearance may also be caused by tumours of the diencephalon.

Triad of a very fine, rapid nystagmus, likened to a "shimmering" movement, head tilt and head nodding.

Neuroimaging and monitoring for visual, neurologic and endocrine decline is mandatory.

### Referral guidelines

- All patients with nystagmus require referral.

Those with acquired nystagmus, or in whom the time of onset is unclear, require urgent referral.

## 19.12 Congenital Ptosis

In most cases of congenital ptosis there is a dystrophy of the levator muscle. Occasionally dystrophic ptosis is seen with other ocular conditions such as elevator palsy, jaw-wink ptosis or blepharophimosis syndrome. Congenital neurogenic ptosis, i.e. Horner's syndrome or third nerve palsy may also occur.

### Symptoms

Most patients with congenital ptosis are brought for assessment by their parents. They are aware of a droop to one or both upper lids, which remains relatively unchanged as the child grows. There is usually lag in downgaze due to inability of the dystrophic muscle to relax and the eye(s) may remain open at night.

### Immediate management

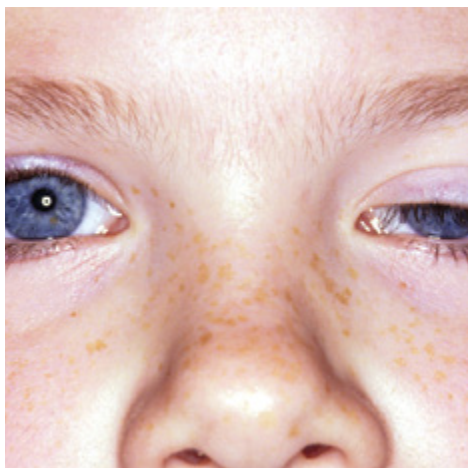It is important to assess whether the ptosis is causing amblyopia. In this situation there may be strabismus present and the lid may sit below the visual axis (pupillary centre). If there is a risk of amblyopia relatively urgent surgery is required to allow normal visual development.

### Long-term management

In non-amblyogenic ptosis, a corrective procedure can be delayed until just before the patient starts school or at a time when the patient is old enough to make their own decision on the surgery.

### Referral guidelines

Children with congenital ptosis should be referred for early assessment as amblyopia, if present, needs immediate treatment. Most will require regular clinic follow-up, either with or without surgery, until they have at least reached visual maturity at around 8 years of age.



Left congenital ptosis.

## 19.13 Paediatric Orbital and Preseptal Cellulitis

Cellulitis in children may arise from a skin source (an abrasion or cut) but commonly occurs secondary to ethmoid sinus infections.

### Symptoms

- Eyelid swelling and erythema
- Usually some discharge
- Possible proptosis and reduced vision

### Signs


- The signs of orbital rather than preseptal (eyelid only) infection include proptosis, reduced eye movements and decreasing vision (possibly with an afferent pupil defect if the optic nerve is compressed)

### Immediate management

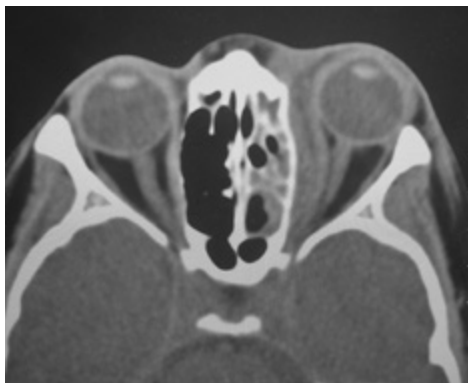- Treatment with oral antibiotics is appropriate with Amoxycillin/Clavulanic acid a good first choice as it covers some of the sinus anaerobes. There should be some improvement in the cellulitis (reduced swelling, erythema) within 48 hours
- Daily monitoring is needed to ensure resolution

### Referral guidelines

If there is suspicion of orbital involvement or failure to improve after 48 hours of oral antibiotics then referral is warranted. Scanning may reveal an abscess that requires draining.



Left orbital cellulitis with loss of up gaze.



CT showing left orbital cellulitis with involvement along the medial wall of the left orbit adjacent to the sinus with infection.

## 19.14 Ophthalmia Neonatorum

Early onset conjunctivitis may be due to tear duct obstruction but one must consider the possibility of ophthalmia neonatorum. The two most likely infective agents are *Gonococcus* (presents 3–5 days after birth) and *chlamydia* (5–14 days postnatally), but it may also be caused by *staphylococcus* and *streptococcus*.

### Symptoms

- Sticky red eyes from soon after birth.

### Signs

- Discharge.
- Conjunctival inflammation and swelling.
- Eyelid swelling.

### Immediate management

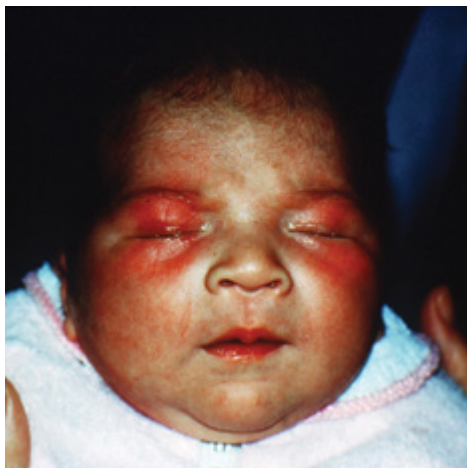- Swabbing is appropriate with special kits required for chlamydial swabbing of the inferior tarsal conjunctiva.
- Treatment is with Ceftriaxone 25–50 mg/kg iv or im as a single dose (up to maximum of 125 mg). The parents must be counselled and treated as appropriate.

### Long-term management

- With treatment the infection should resolve without sequelae.

### Referral guidelines

These children should be seen by an ophthalmologist and a paediatrician. Chlamydial infections can cause pneumonitis.



Bilateral swollen red lids and discharging eyes in ophthalmia neonatorum.

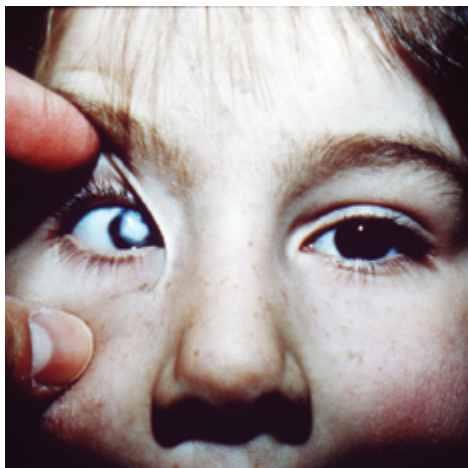

## 19.15 Cloudy Cornea and Leukocoria

Any condition which prevents a normal red reflex is a threat to the visual development. Sometimes in very dark-eyed children the reflex is difficult to assess and it may be necessary to dilate the pupil with Mydriacyl 1% (Tropicamide).

**Any opacity in the ocular media can impair the red reflex. This includes:**

- Cornea
  - Bacterial infection with ulceration or haze secondary to intrauterine infection.
  - A developmental abnormality such as Peter's Anomaly (a central corneal opacity with strands of iris adherent to the posterior corneal surface and a high risk of glaucoma).
  - Sclerocornea – an opacified patch extending from the edge of the cornea (limbus) caused by that part of the cornea being structurally similar to sclera.
  - Limbal dermoids – various dermal skin elements form a rounded elevated structure at the limbus, extending into the cornea. Dermoids need early assessment as they can induce astigmatism and affect the visual development, but they are best removed when the child is older.
  - A metabolic storage disease (usually arise later rather than from birth).
  - Trauma, possibly from a forceps delivery
  - Corneal haze due to oedema secondary to glaucoma.
- Media
  - Cataract (*See 19.16 Congenital Cataract on page 296*).
  - Inflammation (iritis/vitritis) – very unlikely at birth.
- Retina
  - Chorioretinal colobomas occur when the foetal cleft in the developing eye fails to close. This produces an inferonasal defect in the choroid, retina and/or iris. It's not uncommon to have iris involvement with a keyhole pupil without any posterior defect; in this case the vision is normal though a check for astigmatism is advisable. Posterior defects produce visual field defects which are largely irrelevant unless the optic nerve



Right corneal opacity with concomitant esotropia due to the poor vision in the eye.

and macula are involved. It is the degree of macular involvement that is the key determinant of vision long term. No specific treatment is possible for these abnormalities.

- Retinal dysgenesis is rare and arises through maldevelopment of the retina with features resembling retinal detachment. This is often bilateral and is untreatable.
- Retinoblastoma – (See **19.19 Uveitis in Children** on page 300).

### Referral guidelines

Any child with leukocoria needs urgent assessment by an ophthalmologist.

## 19.16 Congenital Cataract

Congenital cataracts occur in about 1 in 2000 live births. They may be familial with an autosomal dominant inheritance, and they are more common with some systemic and chromosomal conditions such as Downs. They can also arise sporadically.

There are different types of paediatric cataract some of which, like nuclear and persistent hyperplastic primary vitreous (PHPV) cataracts, are always present at birth, and others like lamellar and posterior lenticonic types which can arise later.

Bilateral cataracts can be caused by intrauterine infection or metabolic disease (e.g. galactosaemia) and depending on the nature of the cataract and the history, investigations may be recommended.

### Symptoms

Poor vision/fixation, strabismus.

### Signs

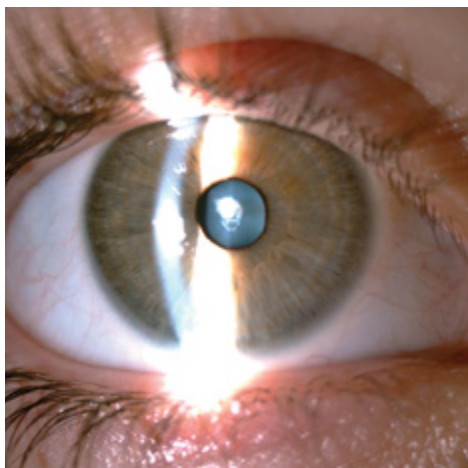
Reduced red reflex.

### Slit lamp signs

Reduced red reflex, lens opacities.

### Immediate management

Urgent referral is required as early surgery is needed to prevent dense amblyopia



Congenital polar cataract.

## Long-term management

- For those that are visually significant at birth early surgery is required, ideally within the first 2 months of life. The surgery involves removing the entire lens and some of the anterior vitreous. A rim of lens capsule is left behind to support an intraocular lens if one is inserted at a later date. Currently implants are considered for children older than 6 months but not usually in infants. The eye grows so much in the first couple of years that any implant quickly becomes the incorrect strength. Contact lenses are used to correct the focus and these are altered as the eye grows. The family must learn to manage the lenses with weekly removal for cleaning.
- Amblyopia is very difficult to overcome, particularly with unilateral cataracts and the visual outcome may be disappointing. For bilateral cataracts operated on in the first 2 months 80% will achieve  $> 6/18$  in at least one eye. For unilateral disease the visual outcomes range from  $6/9$  to  $< 3/60$  but are more often toward the poorer end of this range. The family must be involved in the decision-making about the aggressiveness of treatment. Secondary glaucoma is a long-term risk so ongoing review is required even beyond the amblyogenic period.

## Referral guidelines

Any child with suspected cataract should be referred urgently, within a few days, to an ophthalmologist.

## 19.17 Glaucoma in Children

Primary congenital glaucoma is rare but serious and needs to be dealt with promptly to minimise amblyopia and optic damage.

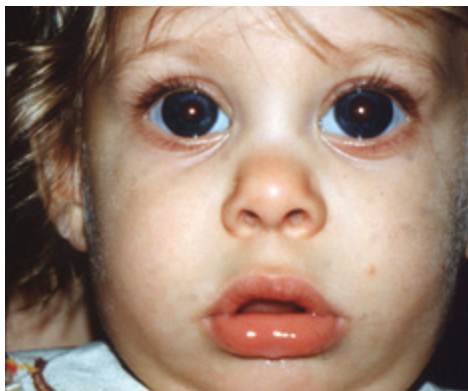Secondary glaucoma is common with Sturge-Weber and some other systemic conditions. It can also occur with ocular problems like iritis and aphakia and developmental abnormalities like Peter's anomaly (opaque central cornea with attachments from the iris to the cornea) and Axenfeld-Rieger (an abnormal angle sometimes with iris atrophy).

### Symptoms

- Watery eye, photophobia.

### Signs

- Excess watering, photophobia and corneal haze, which may be subtle. The sclera is softer in children and with high pressure the eye will enlarge; this is known as buphthalmos.



Buphthalmos (large eyes) caused by raised intraocular pressure in congenital glaucoma.

### Slit lamp signs

- Enlarged corneal diameter and hazy cornea with elevated pressure and optic nerve cupping.

### Immediate management

- Prompt referral is vital.

### Long-term management

- Although drops may be used as an adjunct, primary congenital glaucoma is largely a surgical problem. There are specific paediatric glaucoma operations like goniotomy where a 23-gauge needle is passed across the anterior chamber and used to incise the trabecular meshwork through about 120 degrees. 90% of paediatric glaucoma cases can be adequately controlled with one or two of these operations. Adult glaucoma procedures like trabeculectomy, tube drainage surgery and laser destruction of the aqueous production area in the ciliary body are sometimes used in children.
- Regular examination under anaesthesia may be needed to monitor young children. Amblyopia is an ever-present threat. About 2/3 will ultimately achieve > 6/18 but if symptoms are present at birth then < 50% reach 6/60.

### Referral guidelines

- Any child with a hazy cornea or enlarged eye needs urgent assessment by an ophthalmologist.

## 19.18 Albinism

- There are two inheritance patterns for albinism:
- Oculocutaneous albinism is an autosomal recessive, hypopigmentation of hair, skin and eye and can be tyrosinase positive with some degree of pigmentation or tyrosinase negative with no pigmentation.
- Ocular albinism is usually X-linked recessive with ocular hypopigmentation only.
- Hermansky-Pudlak syndrome is an association between albinism and platelet dysfunction.
- Chediak-Higashi syndrome is an association between albinism and white blood cell dysfunction.

### Symptoms

- Decreased vision and photosensitivity.

### Signs

- Range of acuity 6/12 to 6/60, refractive error, strabismus, nystagmus starting at 2–3 months, amblyopia secondary to strabismus or differing refractive error, iris transillumination, retinal hypopigmentation and foveal hypoplasia, almost complete decussation of optic nerve fibres at the chiasm give an abnormal flash visual evoked potential (VEP).

### Slit lamp signs

- Iris transillumination, retinal hypopigmentation and foveal hypoplasia.

### Immediate management

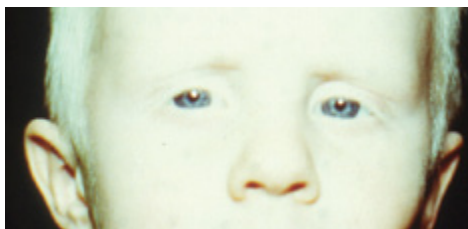- Check for easy bruising and repeated infections to rule out the syndromes associated with albinism.
- Refer for a complete ocular examination. Treating amblyopia may reduce nystagmus.

### Long-term management

- Eye muscle surgery may be considered for significant strabismus or abnormal head posture, genetic counselling, dermatologic consultation.

### Referral guidelines

Early referral to a paediatric ophthalmologist recommended.



Typical colouration of a child with oculocutaneous albinism.

## 19.19 Uveitis in Children

HLA B27 uveitis can occur in children, though it is uncommon. An asymptomatic anterior uveitis can arise due to juvenile idiopathic arthritis (JIA). Children with this condition require regular eye review for at least 5 years after diagnosis and will sometimes need very aggressive treatment for intraocular inflammation with topical steroids and systemic agents such as methotrexate.

### Symptoms

- In juvenile arthritis any associated anterior uveitis is usually asymptomatic.
- With HLA B27 and other forms the eye is red, aching, light sensitive and possibly blurry.

### Signs

- Nil with JIA.
- Otherwise conjunctival injection, mainly around the limbus.

### Slit lamp signs

- Cell and flare in the anterior chamber, keratic precipitates on the endothelium, posterior synechiae.
- Band keratopathy with calcification deposition starting in the peripheral cornea

### Immediate management

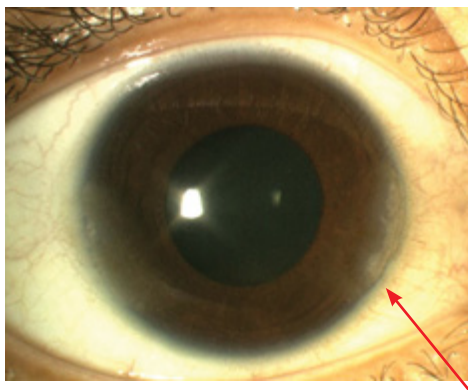
- Intensive topical steroids, plus pupil dilation to prevent/break any synechiae.

### Long-term management

- Keeping the eye quiet with steroids and/or systemic therapy and managing any secondary cataract and glaucoma.

### Referral guidelines

All children with JIA need regular screening. Other diseases associated with anterior uveitis will have symptoms if they get inflammation and should be referred promptly (within a day or two).



Early calcification across the anterior cornea (band keratopathy) in chronic uveitis.

## 19.20 Retinoblastoma

Retinoblastoma usually presents between 1 and 2 years of age with a white pupil but sometimes with a wandering poorly seeing eye. It can be hereditary but is often sporadic.

Hereditary forms, either inherited or with a germline mutation (there is no previous family history but transmission to subsequent generations is possible) often have multiple and bilateral tumours, while the sporadic forms are usually single tumours.

### Symptoms

Wandering eye in a child, with poor visual responses.

### Signs

Poor red reflex, white pupil, visible mass in the eye, proptosis.

### Slit lamp signs

Mass may be visible behind the pupil.

### Immediate management

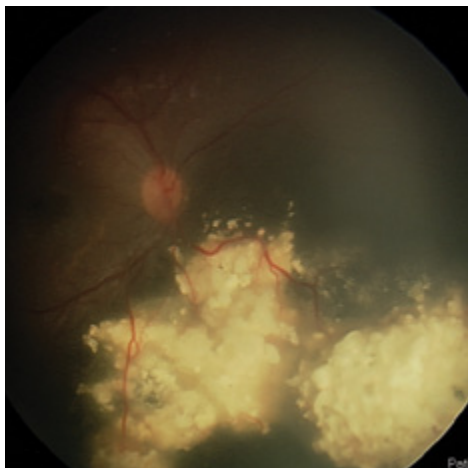
Urgent assessment required.

### Long-term management

- Serial examination under anaesthesia is required to plan and execute treatment and to monitor progress. Triple agent chemotherapy is often used to shrink tumours prior to local treatment with cryotherapy, laser or radiation plaques. External beam radiation is infrequently needed. Enucleation is sometimes required for advanced disease.
- The prognosis with treatment is extremely good with an average 98% life survival. Those with germline mutations carry a long-term risk of other tumours such as osteogenic sarcoma so lifelong monitoring is advisable.
- Genetic testing is available which can help determine whether siblings and offspring are at risk. For those without the mutation, serial EUAs can be avoided.

### Referral guidelines

Any child with leukocoria (white or abnormal red reflex) needs urgent assessment by an ophthalmologist.



White 'cottage cheese' like tumour typical of retinoblastoma.



## 19.21 Retinopathy of Prematurity (ROP)

ROP is caused by an interruption to the normal vascularisation of the retina in premature babies. It occurs because of fluctuations in oxygenation to the retinal tissues in the post-partum, pre-term period. ROP can progress to retinal neo-vascularisation, vitreous traction on the retina, retinal dragging or detachment and blindness.

Many children will get lesser grades of ROP (grades 1–2), which resolve with no sequelae. Only children who reach a certain level will require treatment.

Risk factors: Gestational age < 32/40, birth weight < 1500g, systemic illness.

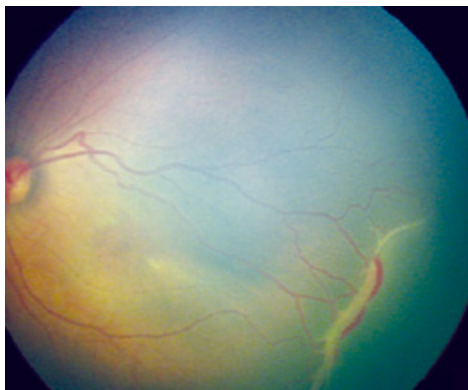
About one third of babies born under 32/40 and two thirds born under 28/40 gestation have some R.O.P. 10–20% have stage 3 or greater (i.e. more severe levels that may require treatment).

Babies are screened from 30 weeks gestational age at 1–2 weekly intervals depending on the risk level. ROP is graded by stage (1–5), extent (clock hours of retina involved) and zone (zones 1–3, with more posterior disease closer to the optic nerve being zone 1 and more worrying). If there is vascular engorgement (Plus disease) then this signifies greater activity and greater risk.

### Immediate management

Treatment is recommended for more advanced disease, particularly grade 3 with Plus disease in zones 1 or 2. In some circumstances, particularly with very severe or aggressive ROP the injection of anti-VEGF agents (e.g.: Avastin) is the preferred treatment. Laser is applied to the avascular peripheral retina to reduce the production of vasoproliferative substances.

Ideally this causes regression of the neovascularisation and slow resolution of the disease. The treatment may not be curative, and although the long-term outcomes with treatment are clearly better than without treatment, the difference is not as great as one would hope.



Retinopathy of prematurity: stage 3 with plus disease. The plus disease is demonstrated with the dilated tortuous vessels. Note too the raised ridge with avascular retina beyond it.

### Long-term management

Children who have had ROP are at greater risk of strabismus, focusing problems and amblyopia, therefore require long-term monitoring.

### Referral guidelines

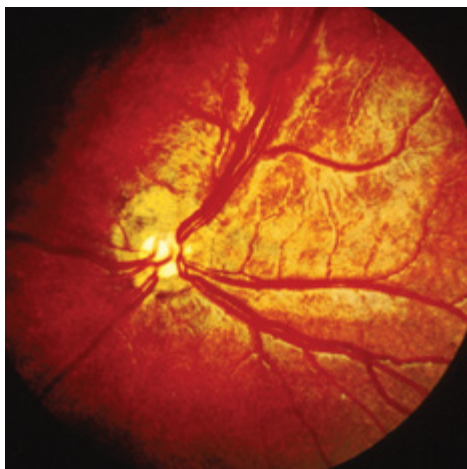Any baby born in the Auckland area less than 30/40 or weighing less than 1250 g is screened. Those outside these guidelines thought to have high risk are also screened.

## 19.22 Optic Nerve Hypoplasia

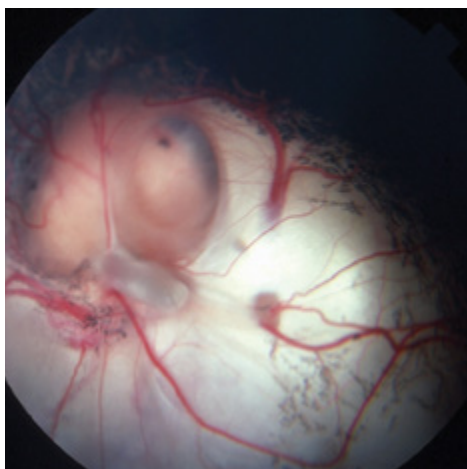
Optic nerve hypoplasia is not uncommon, with the degree of maldevelopment determining the visual potential.

If it is bilateral then paediatric assessment and scanning to look for midline brain defects is required. With bilateral optic nerve hypoplasia one must always consider septo-optic dysplasia (de Moursier's Syndrome) where involvement of the hypothalamus and pituitary can lead to hormone deficiencies and growth and developmental retardation.

If a chorioretinal coloboma (failure of the inferior retina and choroid to develop) involves the optic nerve then it may be hypoplastic.



Optic nerve hypoplasia.



Chorioretinal coloboma with failure of an inferior area of the ocular tissues to form correctly.

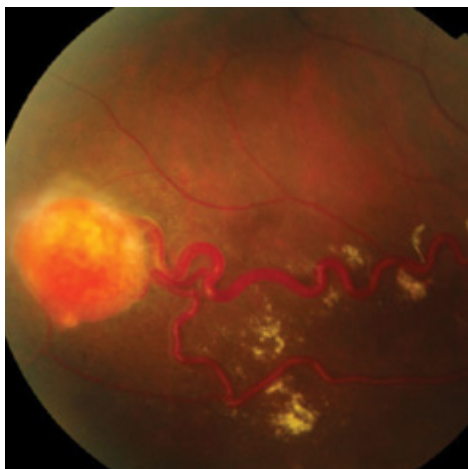
## 19.23 Phakomatoses

Also known as neurocutaneous syndromes these are a group of multisystem diseases affecting structures derived from neuroectoderm.

Sturge-Weber: a naevus flammeus that involves the eyelids, even in the absence of Sturge-Weber, carries a significant risk of glaucoma. It is thought that elevated episcleral venous pressure from the haemangioma reduces aqueous drainage and elevates the pressure. Drops may be insufficient to control the glaucoma and surgery carries greater than usual risks because of the increased vascularity. Sturge-Weber children may have choroidal haemangiomas which can cause serous choroidal detachment but usually are quite benign.

Neurofibromatosis Type 1 (NF1): lisch nodules are small elevated areas of increased pigmentation on the iris which can be detected on slit lamp examination. They are benign but can be a useful sign in the diagnosis of the disease. 90% of those with NF1 have them by 9 years of age. Optic nerve gliomas can involve the orbital, intracranial or chiasmal components of the nerve. If present they do not necessarily cause visual impairment and they are very unlikely to develop or grow once a child is beyond 6 years of age. Annual review of the vision, colour vision and pupil responses is a useful way of monitoring children with NF1. Follow-up is more frequent for those who actually have a glioma.

Tuberous sclerosis: a rare autosomal dominant condition with variable penetrance that results in seizures (90%) and mental retardation (60%). 50% have facial angiofibromas and astrocytic hamartomas can occur in the retina or optic disc. The latter may be smooth and grey or tapioca-like. They are benign.



Orange retinal haemangioma with prominent feeder vessels in von Hippel-Lindau disease.

## 19.24 Child Abuse/ Non-Accidental Injury (NAI)

Retinal haemorrhages in the absence of a bleeding disorder or known other cause are highly suspicious for non-accidental injury.

Haemorrhages are rare with accidental trauma and usually occur only with major trauma such as road traffic accidents. An incidental finding of retinal haemorrhages requires referral for NAI assessment.

### Symptoms

Serial injuries with poor or inconsistent histories should cause suspicion.

### Signs

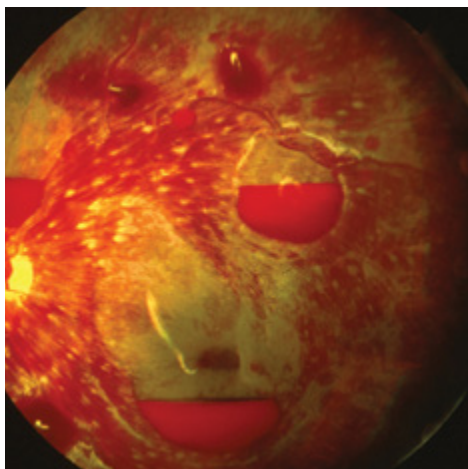
Burns, fractures, abrasions, subdural and retinal haemorrhages are key features.

### Immediate management

Urgent referral to the child abuse specialists at the Children's Hospital.

### Referral guidelines

If there is any suspicion of child abuse then referral is mandatory.



Retinal haemorrhages in all layers of the retina and pre-retinal blood typical of non-accidental injury.

## 19.25 Dyslexia and Learning Disorders

Dyslexia is a processing rather than a vision problem. It is diagnosed when a child is intellectually equal to other children the same age but fails to achieve in certain areas (usually reading and writing). The diagnosis is best made by a child psychologist.

It is appropriate to rule out vision problems in these children, to ensure there is no alignment problem or any need for glasses. There is a branch of optometry which recommends “vision training”, an expensive course of computer-based activities, on the assumption that using the eyes can improve the processing. Ophthalmologists don’t support this approach.

Irlen syndrome has the same diagnostic criteria as dyslexia but its promoters recommend tinted lenses to help cancel out “visual noise”. Some children do seem to find these helpful but rarely continue with the lenses long term. There is no evidence to support their use.

### Symptoms

Despite normal intelligence the child has difficulty with a particular type of task, e.g. reading and writing (dyslexia), maths (dysgraphia).

### Signs

A normal IQ but well behind his/her peers in the particular activity.

### Immediate management

Non-urgent vision check and referral to a child psychologist.

### Long-term management

- For more information and a useful handout for parents please refer to the American Academy of Ophthalmology website – [www.aao.org](http://www.aao.org) – for their policy statement on dyslexia, or contact the orthoptists at Auckland Eye to have a copy forwarded to you.
- Paediatric or educational psychologists are best placed to make the diagnosis of dyslexia and make the appropriate management recommendations.

### Referral guidelines

An optometric or ophthalmic assessment is warranted to rule out any vision problem.



## 20 *Focusing*

## 20.1 Myopia (Short Sighted)

An optical state of the eye where images of near objects are in focus but images of distant objects are blurred. Low and moderate degrees usually stabilise by late teens, whereas higher degrees may be progressive and associated with retinal problems, glaucoma and poor vision.

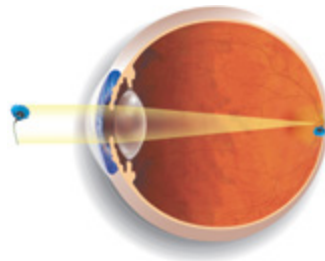
### Signs

Blurred distance vision, with onset usually from age 6-12, progressing in magnitude to varying levels, until stabilising typically in the early 20's. Moderate to high myopia has associated increased risk of retinal detachment which causes symptoms of flashes and floaters, progressive field defect and reduced visual acuity.

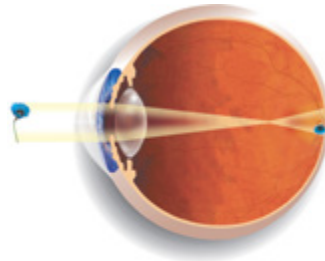
Glasses worn to correct myopia may be recognised because they minify the image of the eye as seen through the glasses. A highly myopic eye has an increased axial length, which may give an appearance of proptosis. In general the cornea is normal on slit lamp examination unless the myopia is part of the focusing change of keratoconus.

### Long-term management

- Glasses and contact lenses are traditional means of correcting myopia.
- Orthokeratology, under the care of an optometrist, uses overnight contact lenses wear to induce semi-permanent changes in corneal shape, and is an effective and reversible way of treating myopia. Used in children it can reduce the rate and degree of progression of myopia, and appears to be relatively safe, with the major risk being very rare microbial keratitis.



Normal eye.



Myopia (nearsightedness).



- Surgical treatments include corneal laser (SMILE, LASIK or PRK), phakic intraocular lens implantation and lens replacement surgery/refractive lens exchange. These methods are generally safe and effective. Whilst there are risks these usually cause only minor worsening of vision and are exceedingly rare.

## Myopia Control/Prevention

- Strategies to slow (and occasionally stop) the progression of myopia can be considered particularly if there is a family history of high myopia or if it comes on at a young age.
- Natural sunlight is protective with research suggesting a minimum of 12 hours per week outside. It is also sensible to match any time inside reading or looking at screens with time outside. Sunglasses do not cancel out the beneficial effect of sunlight on myopia progression.
- Intense near activities are linked to myopia progression in childhood – and should where possible be limited to 20 minute sessions followed by 5 minute breaks.
- Keeping glasses up to date is important so an optometry review every 6 months is sensible. Avoiding glasses or under-powering them risks more rapid progression.

## There are several specific treatment options that can be discussed with an optometrist or ophthalmologist:

- Dilute Atropine eyedrops (0.01% to 0.05%) used daily
- OrthoK contact lenses worn overnight
- Dual-focus soft contact lenses worn daily
- DIMS, HALT and other special spectacle designs

## Referral guidelines

- Immediate referral for significant sudden subjective vision change especially associated with flashes or floaters (*See 13.1 Posterior Vitreous Detachment (PVD) on page 164*)(*See 13.24 Retinitis Pigmentosa (RP) on page 203*).
- Routine referral for assessment of suitability for refractive surgery.
- Routine referral for discussion of myopia control options for children.

## 20.2 Hyperopia/Hypermertropia (Long Sighted)

An optical state of the eye resulting in progressive blurring of vision, more pronounced for near than for distance images.

### Symptoms

- The youthful accommodative mechanism (steepening of the lens) may be able to overcome this focusing error, so it is often asymptomatic until middle-age. In children, it may be associated with strabismus, and is an important cause of amblyopia. As accommodative power decreases, symptoms of eye strain, headaches and variable vision (near more than far) become common. Typically hyperopic patients will initially require reading glasses, then a few years later distance glasses as well.
- An angle closure crisis is more common in patients with hyperopia and causes symptoms of intermittent blurring and haloes, or reduced vision and pain. Anticholinergics should be prescribed with caution.

### Signs

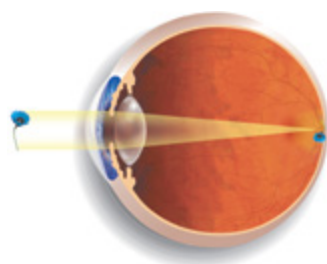
Glasses worn to correct hyperopia may be recognised because they magnify the image of the eye as seen through the glasses.

### Long-term management

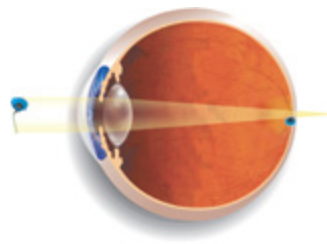
- Glasses or contact lenses are traditional means of correcting hyperopia once it becomes symptomatic.
- Infants with strabismus may need to wear glasses as part of the strabismus and amblyopia management.
- Surgical treatments include corneal laser (SMILE, LASIK and PRK), phakic intraocular lens implantation and lens replacement surgery/refractive lens exchange.

### Referral guidelines

- Patients with low levels are generally managed by their optometrists.
- Patients can be referred for consideration of laser vision correction. Those with higher levels will achieve good long-term outcomes with lens replacement surgery/refractive lens exchange. These Patients may be good candidates for presbyopia correcting IOLs.



Normal eye.



Hyperopia (farsightedness).

## 20.3 Astigmatism

Astigmatism is a focusing problem which affects the vision at all distances. It is usually caused by an uneven curvature of the cornea (or lens). While the surface of a perfect eye is round like a soccer ball, an eye with astigmatism is shaped more like a rugby ball, more curved in one plane than in the other.

Light rays are focused at more than one point on the retina and this degrades the quality of the image on the retina. Astigmatism may occur on its own, or in combination with near or far-sightedness.

### Symptoms

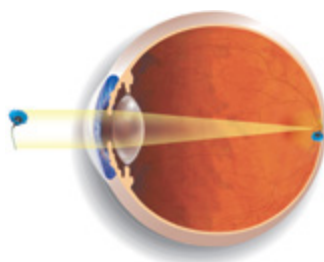
Blur. May make objects appear a little distorted.

### Signs

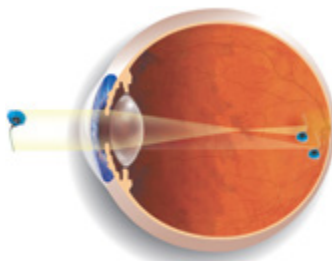
The irregularity is detected on a focus test (refraction) or by mapping the ocular surface (topography).

### Long-term management

- Glasses are the mainstay of treatment and low levels of astigmatism can be treated with standard contact lenses. For higher levels specific astigmatism-correcting (toric) contact lenses are available.
- Astigmatism is correctable with SMILE or LASIK or PRK surgery.
- When someone has [Cataract Surgery](#) any visually significant astigmatism is addressed by inserting an astigmatism-correcting (toric) intraocular lens implant, or occasionally with incisions on the cornea to even out the curvature (astigmatic keratotomies or limbal relaxing incisions).



Normal eye.



Astigmatism.

### Referral guidelines

Astigmatism is managed by optometrists unless the patient wishes to have vision correction surgery (SMILE, LASIK or PRK), or lens replacement / [Cataract Surgery](#).

## 20.4 Presbyopia = “Near vision failure”

The age-related loss of near or reading vision associated with decreased flexibility of the crystalline lens. This is inevitable for all eyes and becomes symptomatic in patients with normal focus at an average age of 45.

For those who have hyperopia it may be earlier, for those who have myopia it may be later. At this age, the requirement for glasses changes. Those with good distance vision will simply require reading glasses. Myopic patients will begin to remove their glasses for near, or alternatively change to bifocals. Hyperopic people will need reading glasses initially, then later bifocals or separate reading glasses.

### Symptoms

- Blurred, variable or fluctuating near vision.
- Brow, eye or headache.

### Immediate management

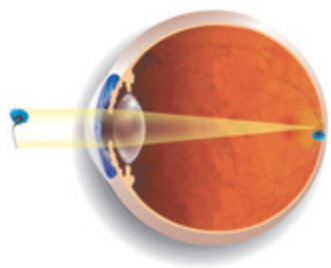
- This is a good time for an eye check by an optometrist, who will be able to identify the corrections available, as well as to carry out screening examinations for other eye disease including glaucoma. It may take a patient several weeks to adapt to any new glasses correction. Some patients may never adapt to bifocals or progressive lenses, and will instead require separate pairs of distance and reading glasses.

### Long-term management

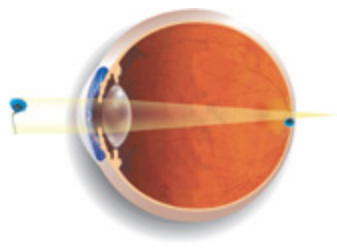
- Glasses for treatment of presbyopia will need to be updated every 2–5 years because of the normal progressive loss of accommodative amplitude. The process tends to stabilise by age 60.
- Surgical methods of correcting presbyopia include Presbyond LASIK (blended vision / monovision), and lens replacement surgery/ refractive lens exchange. For lens surgery this can be performed using premium lens technology (eg multifocal / EDof lenses) to correct presbyopia, or choosing an intraocular lens power to leave one eye focused for near and one for distance (blended vision/monovision).

### Referral guidelines

Glasses are the safest option for patients, but those with very high motivation for a surgical solution should be referred for a refractive surgical opinion, especially if aged over 50.



Normal eye.



Presbyopia.

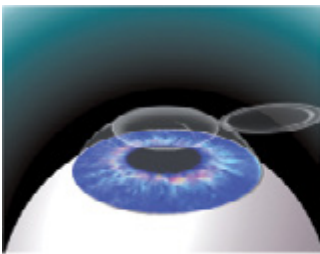
## 20.5 Laser In-Situ Keratomileusis (LASIK)

Laser in-situ keratomileusis (LASIK) is a surgical method of permanently correcting the refractive errors of myopia, astigmatism and hyperopia. Under topical anaesthesia, a superficial flap approximately 100 microns thick is created in the cornea, with a femtosecond laser (or historically with a precision microkeratome blade).

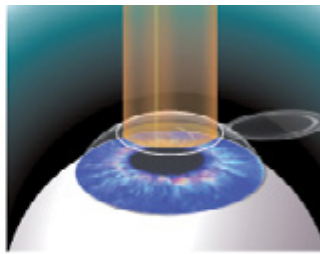
The hinged flap is folded back and the underlying surface of the cornea is treated with the Excimer laser, which accurately ablates corneal collagen to reshape the cornea. The flap is then repositioned to restore a smooth intact corneal surface.

### Indications and contraindications

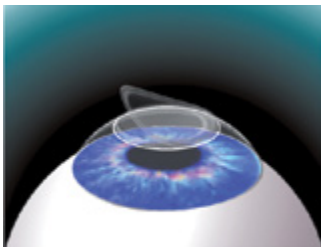
- LASIK is not generally carried out before age 20. Patients 50 and older may consider other refractive surgical options, such as lens replacement surgery/ refractive lens exchange. Myopia up to 10 diopters, astigmatism and hyperopia up to 5 diopters may be treated. The refractive error must be stable for at least 12 months. The cornea, especially corneal shape is carefully examined prior to surgery to exclude ectatic diseases such as keratoconus and any other corneal pathology. Systemic diseases that may affect corneal healing, such as connective tissue disorders are a contraindication to LASIK. Dry eye is a relative contraindication.




Step 1  
Flap is created and folded away from the central cornea.



Step 2  
Excimer laser reshapes the cornea.



Step 3  
Corneal flap is replaced.



Step 4  
LASIK surgery is complete.

### Post-operative symptoms and signs

- Grittiness, and mildly blurred vision may last 1–3 days and is normal.
- Pain and reduced vision in the first post-operative week may be caused by inflammation of the flap interface. Diffuse lamellar keratitis is rare, non infective, usually mild and responds to steroids, however severe inflammation can lead to flap melt and reduced vision. Corneal infection (microbial keratitis) is an extremely rare but devastating complication of LASIK and may require hospital admission.
- Dryness and variability in vision due to alteration in the corneal sensation and poor quality tear film may last up to 9 months.
- Transient light sensitivity may occur within the first month and is thought to represent mild corneal inflammation. It will normally respond to topical steroids.
- Changes in focusing in the post-operative weeks may be a sign of loss of refractive effect (regression) and may lead to the need for further laser (retreatment or enhancement).
- Late (months or years) changes in focusing may simply represent a progression in the eye's pre-existing refractive error, or may represent the rare progressive iatrogenic corneal weakening condition keratectasia.

### Post-operative care

- Post-operative steroid and antibiotic eyedrops for 1 week.
- Topical lubricants as required for grittiness and variable vision. These symptoms of dryness should improve progressively over the first year.

### Referral guidelines

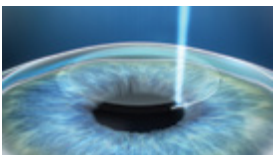
People who wish to be less dependent on/eliminate their corrective eyewear (glasses or contact lenses) can be referred routinely for a laser assessment. Generally patients need to be 20 years or older, have a stable prescription, have healthy eyes with sufficient corneal thickness, good general health (certain medical problems prevent laser eye surgery) and if female, not pregnant or breastfeeding. Laser eye surgery can treat all focusing errors, general guidelines being up to -8 dioptries of myopia, +4 dioptries of hyperopia and 4 dioptries of astigmatism.

## 20.6 Small Incision Lenticule Extraction (SMILE)

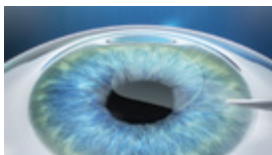SMILE is a minimally-invasive corneal refractive surgery technique for the correction of myopia and astigmatism using purely femtosecond laser technology.

Under topical anaesthesia, a femtosecond laser is used to create a thin disc of tissue (lenticule) inside an intact cornea, which is then removed through a 3mm keyhole opening, in contrast to LASIK where a corneal flap is created and the underlying tissue ablated with an excimer laser. One of the advantages of SMILE, other than being “flapless” is that dry eye is less common afterwards in comparison to LASIK.


- Indications and contraindications
- SMILE is suitable for people 20–55 years of age
- Myopia up to -10 dioptres and astigmatism up to 4 dioptres
- The refractive error must have been stable for at least 12 months
- The cornea, especially the corneal shape is examined carefully prior to surgery to exclude ectatic diseases such as keratoconus and any other corneal pathology
- Systemic diseases (such as connective tissue disorders) that may affect corneal healing.
- Post-operative symptoms and signs
- Grittiness, and mildly blurred vision may last 1–3 days and is normal
- Glare, haloes or starbursts at night are common, usually very mild and can take weeks to months to resolve
- Most patients will experience some dryness in the first week though for some it may take longer to settle
- Corneal infection (microbial keratitis) is an extremely rare complication of SMILE and may require hospital admission
- Retreatment within the first few months is occasionally required but late regression is rare, as this usually represents a progression of the original pre-existing refractive error.



Creation of lenticule and small access (< 4 mm)



Removal of the lenticule



Refractive error is corrected

- Post-operative care
- Post-operative steroid and antibiotic eyedrops for 1 week
- Topical lubricants as required for grittiness and variable vision in the first few weeks.

### Referral guidelines

People who wish to be less dependent on/eliminate their corrective eyewear (glasses or contact lenses) can be referred routinely for a laser assessment. Generally patients need to be 20 years or older, have a stable prescription, have healthy eyes with sufficient corneal thickness, good general health (some medical problems prevent laser eye surgery) and if female, not pregnant or breastfeeding.



## 20.7 Photo Refractive Keratectomy (PRK)

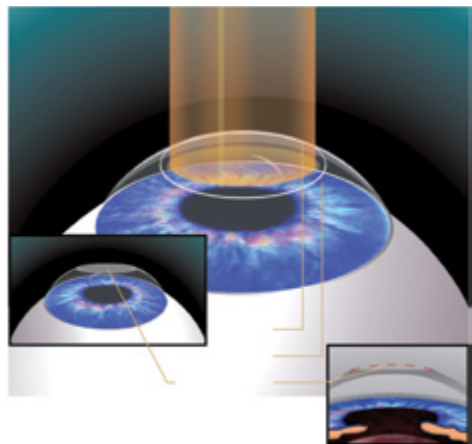
Photo refractive keratectomy is a surgical method of permanently correcting the refractive errors of myopia and astigmatism. Other names include advanced surface ablation, custom surface ablation and epilasik.

All of these techniques involve, under topical anaesthesia, removing the corneal epithelium, with subsequent reshaping of the anterior corneal stroma with the excimer laser. Unlike LASIK, a corneal flap is not created. The procedure is more painful than LASIK and visual recovery slower. However, PRK weakens the cornea less than LASIK so is safer in patients with thin corneas. However, PRK has a greater risk of infection than LASIK as the corneal epithelium takes longer to heal. The final refractive outcomes are the same for the two procedures. Most patients opt for LASIK/SMILE due to its association with faster visual recovery and minimal pain.

### Indications and contraindications

PRK is not generally carried out before age 20. Patients 50 and older may consider other refractive surgical options such as refractive lens exchange. Myopia up to 7 diopters and astigmatism may be treated. The refractive error must be stable for at least 12 months. The cornea, especially corneal shape is carefully examined prior to surgery to exclude ectatic diseases such as keratoconus and any other corneal pathology. Systemic diseases that may affect corneal healing such as connective tissue disorders are a contraindication to PRK. Dry eye is a relative contraindication.

- Post-operative symptoms and Signs
- Post-operative pain which varies tremendously, can be expected for 2–4 days as epithelial healing occurs.
- Visual recovery is variable, and may occur within a week, but is more likely to take 2–3 weeks. Remodelling of the epithelium can cause regression (loss of treatment effect) or haze (opacity of the epithelium) affecting the visual outcome.



Photorefractive keratectomy (PRK).

- Severe pain and reduced vision within the first week may be caused by microbial keratitis. As this is difficult to distinguish from normal post-operative pain, close specialist follow-up is important.

### Referral guidelines

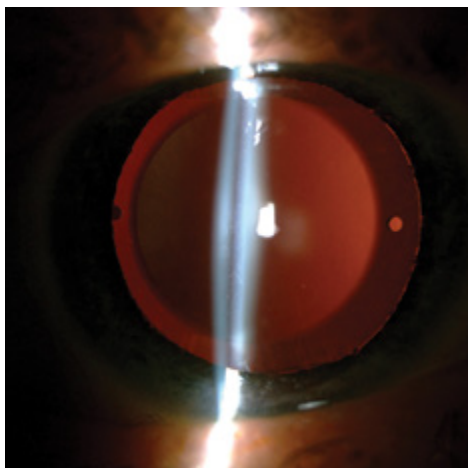
People who wish to be less dependent on/eliminate their corrective eyewear (glasses or contact lenses) can be referred routinely for a laser assessment. Generally patients need to be 20 years or older, have a stable prescription, have healthy eyes with sufficient corneal thickness, good general health (certain medical problems prevent laser eye surgery) and if female, not pregnant or breastfeeding. Laser eye surgery can treat all focusing errors, general guidelines being up to -10 dioptries of myopia, +5 dioptries of hyperopia and 5 dioptries of astigmatism.

## 20.8 Phakic Intraocular Lenses (Phakic IOLs)

These are intraocular lenses that are put into the eye as an addition to the natural crystalline lens. They are used to treat refractive error, offering an alternative to laser vision correction (SMILE, LASIK and PRK), and are generally reserved for patients who have a focusing error that is outside the limits of safe correction by laser. Pre-operative laser iridotomies (small peripheral hole in the iris created with the YAG laser) are now only necessary to prevent pupil block in hyperopes. As these lenses are an addition to the normal physiological optics, they tend to provide extremely good levels of vision clarity. If [Cataract Surgery](#) is required at a later date the phakic IOL will need to be removed. This is a simple step and thus does not complicate long term visual outcomes of patients. These IOL's have without doubt provided visual rehabilitation beyond any other surgical technology available, with incredibly safe parameters. The first ICL in the North Island was put into a patient's eye in 2003 By Dr Dean Corbett.

### Types of phakic IOLs

- STAAR ICL, also known as Implantable Contact Lens (ICL): this lens is placed between the iris and the natural crystalline lens. This IOL has over 25 years of success, and is essentially the only phakic IOL option a patient should consider. A recent modification of design means that preoperative laser iridotomies are no longer necessary for myopic patients. The ICL range has been expanded to include low myopia and mixed astigmatism.
- The STAAR ICL was been released in Europe in 2023 in a presbyopia correcting version "VIVA" I expect it will be available in 2024. This uses Spherical aberration to increase depth of Focus
- AMO Verisyse and Veriflex (also known as Artisan and Artiflex): these lenses sit in the anterior chamber clipped to the iris. These are a rarely used solution having fallen from favour in most surgeon's experience.
- Alcon Acrysof Phakic IOL: this lens sits in the anterior chamber supported at the angle. This IOL has been withdrawn from the market.



Implantable contact lens (ICL) in situ.

## Patient indications

- High to extreme myopia.
- High Hyperopia.
- Keratoconus or other ectatic or weak corneas.
- Other corneal disease.
- Desire for potential reversibility.
- Adequate anterior chamber depth.
- Vision correctable with spherocylindrical lenses.

## Risks

- Cataract – 1%.
- Endophthalmitis – 1:3000.
- Intractable intraocular pressure (IOP) rise < 1%.

## Outcomes and Followup

- Patients generally have very rapid visual recovery with excellent vision obtained on the first post operative day. Patients may experience pain from raised pressure in the first few hours post surgery. On very rare occasions (< 1%) patients may need admission for IOP control with intravenous agents.

## Long Term

- These lenses are usually very difficult to see with the slit lamp. They may accumulate a small amount of pigment from contact with the posterior iris surface in the first 3 months but this is non progressive and not of clinical significance.

## Referral Guidelines

People who wish to be less dependent on or eliminate their corrective eyewear (glasses or contact lenses) can routinely be referred for an ICL (Implantable Collamer Lens) assessment. Generally, patients need to be:

- 20 years or older
- Have a stable prescription
- Have healthy eyes
- Be in good general health (certain medical conditions may prevent ICL surgery)
- If female, not pregnant or breastfeeding

ICLs can treat all focusing errors but are generally reserved for people with high prescriptions (e.g., over -6, over +3) or if patients' eyes are not suitable for laser eye surgery because they are structurally weaker or more prone to eye diseases.

## 20.9 Refractive Lens Exchange (Clear Lens Extraction)

This is a relatively recent term. It was previously called clear lens extraction. The crystalline lens in fact begins to lose its transparency in the third decade, so the term is somewhat of a misnomer.

For funding purposes, a “clear lens” is one that still provides adequate optics to maintain good high contrast visual acuity (Snellen Chart). In truth, however, it is possible to document loss of vision with regard to colour perception, and low contrast in most patients well before this time.

For most patients a refractive lens exchange will be performed to correct a focusing error. This is usually hyperopia, as it is such a debilitating handicap for some patients.

Refractive lens exchange is simply lens replacement or *Cataract Surgery* before a visually significant cataract has developed. Due to the risk of iatrogenic vitreous detachment and subsequent retinal detachment, this type of surgery is best performed after age 50 or when a vitreous detachment has already occurred.

As it is *Cataract Surgery* it carries with it the same set of risks.

### Options

There are several options to choose from with regard to the planned focusing target.

1. Both eyes distance focus: this gives the best visual quality due to binocular visual summation. Reading glasses for all near tasks will almost always be necessary.
2. Both eyes near focus: this gives the best vision for near tasks and is popular with patients who have always been myopic / short-sighted. Distance glasses for all distance tasks (eg driving / TV) will always be necessary.
3. One eye distance focus, one eye near focus (monovision / blended vision): this option is a reasonably common choice for patients. It offers an increase in the ability to see up close, but there is usually an accompanying reduction in distance vision clarity, due to lack of binocular visual summation. In order for this to provide adequate vision, the eye that has been chosen to achieve good distance vision, must have an accurate result. If there is any significant focusing error – particularly myopia, the patient is likely to find difficulty with some vision tasks such as night driving.
4. Multifocal or extended depth-of-focus (EDOF) IOLs: like the two above options this option also has a number of compromises. Although 92% of people will be very happy with the outcome of multifocal IOLs a small group are bothered by grey or “waxy” vision. A small percentage may also experience intolerable night haloes, but the vast majority find this option gives the greatest range of vision across all distances.

## 20.10 Intacs and Kerarings

Arcuate PMMA implants that are inserted into the mid peripheral corneal stroma to induce a shape change thereby altering corneal power. Originally developed as a treatment for myopia, they are now used to correct early to moderate keratoconus and the iatrogenic corneal weakening Keratectasia, (a rare complication of refractive surgery).

The Intralase femtosecond laser is used to create small arcuate channels in the mid peripheral corneal stroma at a depth of 300 to 400 microns. The implants are then slid into these channels. The surgery is carried out under topical anaesthesia as an outpatient procedure.

Various algorithms are used to choose the exact implant sizes and thicknesses to use, and either one or two segments, which may be symmetrical or of different sizes, may be implanted.

### Indications and contraindications

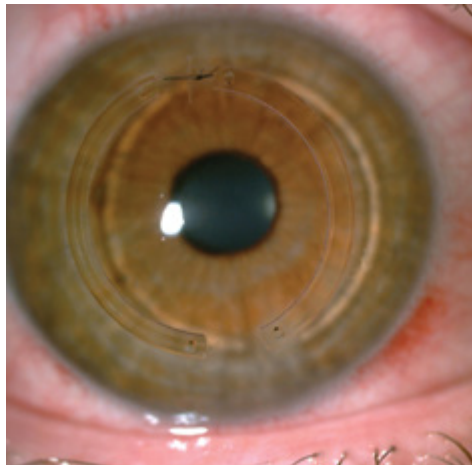
- This procedure is indicated for keratoconus patients who are not able to achieve adequate quality of vision with spectacles or contact lenses but do not have sufficient severity of disease to require corneal transplantation, or patients at high risk for graft failure, e.g. severe atopy, poor compliance
- Contraindications include central corneal scarring, corneal thinning to less than 350 microns, and very steep corneal curvature. Age should be > 20, and the patient should not be pregnant or breastfeeding or have a collagen vascular disorder.

### Signs

The implant may be visible as a translucent semicircular or arcuate segment in the mid peripheral cornea.

### Immediate management

Post-operative antibiotic and steroid eyedrops are used for 1 to 2 weeks. Normal symptoms include glare, haloes, fluctuating vision and foreign body sensation. Complications are rare and include infection, visible deposits within the



Intac implants in situ.

stromal channels, corneal melt, and implant extrusion. Rarely the implant may be removed.

### **Long-term management**

Most will still need glasses or contact lens correction but 75% gain two lines of vision or more. The procedure does not stop progression of the ectasia and so may need to be combined with corneal collagen crosslinking. The main aim of this procedure is to defer corneal grafting.

### **Referral guidelines**

A range of treatment options are now available for keratoconus. The initial management is generally with glasses or contact lenses and is carried out by the optometrist. However, if progression is occurring or the patient is becoming contact lens intolerant then keratoconic patients should be referred to a corneal specialist.



## **21** *Other Areas of Expertise*



## 21.1 Auckland Eye Clinical Research

Since its establishment in 1996, Auckland Eye's ophthalmology research unit has been engaging in clinical trials.

Through partnerships with Sponsors and Contract Research Organisations (CROs) we conduct commercial clinical trials that contribute to the development of new medicines and medical devices used in the diagnosis and treatment of a wide range of eye conditions.

### Advancing Eye Health and Patient Care

Our dedicated team of ophthalmologists, researchers, nurses and technicians have contributed significantly to the development of innovative treatments and surgical techniques. Our patients have been among the first in the world to benefit from life-changing devices and procedures.

Engaging in clinical trials provides several key benefits including:

- **Advancing Medical Knowledge.** Clinical trials are the primary catalyst for advancing medical knowledge and improving treatment options, resulting in more effective therapies and procedures.
- **Access to Cutting-Edge Treatments.** Patients participating in clinical trials have access to potentially beneficial surgeries or medicines that may not be otherwise available.
- **Improving Patient Care.** Through clinical trials Auckland Eye specialists remain at the forefront of ophthalmology, ensuring the delivery of the best and most effective treatments worldwide.

### Notable Clinical Trials

Key contributions to research have included:

- **Cataract Surgery / Lens Replacement:** We have helped advance *Cataract Surgery* techniques and intraocular lens (IOL) technologies, leading to the development of new generation IOLs that offer patients improved visual outcomes and reduced dependence on glasses. We have also helped develop IOL injection techniques being the lead site in the development of the technis preloaded injector systems, both cartridge and one piece injector. In addition

we have evaluated investigational Phaco machines that have found their way to market.

- **Glaucoma:** Our research team has participated in trials assessing the effectiveness of novel glaucoma medications and surgical techniques, contributing to more successful glaucoma management.
- **Dry Eye:** Our work in this area has focussed on evaluating innovative treatments for dry eye, to alleviate the discomfort and improve the quality of life for patients affected by this common condition.
- **Vision Correction:** We were part of an international team that evaluated an innovative corneal inlay device for the treatment of presbyopia, which subsequently achieved FDA approval.
- **Macular Degeneration:** Our participation in clinical trials for macular degeneration has contributed to new medications and therapies.

### Contact Us

For more information or to refer a patient for one of our clinical trials visit the Auckland Eye website or email [research@aucklandeye.co.nz](mailto:research@aucklandeye.co.nz).

## 21.2 Dry Eye Clinic

### Dry Eye Therapy

At Oasis (located at Auckland Eye, Remuera and Takapuna), we provide a full clinical evaluation of the likely cause of a patient's Dry Eye and offer a tailored treatment plan. During a comprehensive assessment we will evaluate the patient's tearfilm and examine their meibomian glands and the health of their Meibomian glands to determine the reason for their Dry Eye.

Throughout the tailored treatment plan, patients will have access to proven, state-of-the-art dry eye technology including LipiFlow® and Lumenis IPL, and their treatment will be delivered by our expertly trained clinical team.

LipiFlow® is a procedure designed to treat the root cause of Evaporative Dry Eye, which can be caused by blocked Meibomian glands. Opening and clearing these glands can allow them to resume natural production of lipids (oils) needed for healthy tears.

### LipiFlow® Treatment

- 1-2 drops of a mild anaesthetic will be placed in the patient's eye. The LipiFlow® eyepiece will then be gently placed into the eye, with the lid warmer under the eye lids and the eye cup underneath the eye lids. Patients will be asked to close their eyes and keep them gently closed for the treatment.
- The LipiFlow® device will be activated and the patient will begin to feel both warmth and gentle pressure on their eyelid. The device has two six minute cycles which include the warming phase, followed by intermittent pulsations and then constant pressure. The different phases are required to facilitate the removal of blockages from the meibomian glands.
- On average, patients report little to no pain during treatment, and most patients will start to notice the most symptom relief around 4-6 weeks post treatment. This should continue for 9 months to a year.
- Two months after treatment, we will ask patients to come back to the Dry Eye Clinic to evaluate progress.

## Lumenis IPL Treatment

- The Lumenis IPL is a revolutionary treatment that is gentle and effective in treating Dry Eye caused by eyelid and skin inflammation. IPL stands for Intense Pulsed Light, which is used to create heat and target the abnormal blood vessels that are the root cause of inflammation.
- The Lumenis IPL treatment is a safe, comfortable 40 minute procedure. Treatment commences with protective shields that are placed on the patient's eyelids to ensure that the patient's eyes are protected during the treatment, thereafter a gel is placed on the treatment area (Cheeks and nose).
- A warm sensation can be felt as the light is applied to the skin, patients feel a rubber band snap. The heat is directed toward the abnormal blood vessels and the meibomian glands which are causing the inflammation that leads to dry, itchy eyes.
- Afterwards, they may notice some redness and discomfort in the treated area. This is a common and harmless response to the heat and should disappear within a few hours.
- Most patients should return every month for up to three or four sessions to achieve optimal results.

# Dry Eye Clinic

## Revitalise Your Vision at Auckland's Exclusive Dry Eye Clinic!

Say goodbye to dry, uncomfortable eyes.  
Book a consultation with Auckland Eye's Dry Eye Clinic and  
rediscover the joy of clear, comfortable vision.

Our cutting-edge clinic specialises in diagnosing and treating:



Dryness  
and fatigue



Eye discomfort



Eye redness



Sensitivity to  
bright light



Overproduction  
of tears

Discover the difference today.

Q [aucklandeye.co.nz](https://aucklandeye.co.nz)  
e. [dryeyeclinik@aucklandeye.co.nz](mailto:dryeyeclinik@aucklandeye.co.nz)  
p. 09 557 1937



AUCKLANDEYE  
Life Changing Eye Care



## **22** *Medications*

## 22.1 Glaucoma

The aim of glaucoma medication is to reduce intraocular pressure (IOP). This is achieved by either reducing the amount of aqueous produced or facilitating its removal.

One of the most common causes of treatment failure for glaucoma is people failing to take their drops. If a patient is on glaucoma drops, encourage them to take their drops regularly and continuously and get new prescriptions if they run out.

### Prostaglandin Analogues

- Hysite (Latanoprost)
- Travatan (Travoprost)
- Lumigan (Bimatoprost)

These drops tend to be well tolerated with few side effects. They are taken each night.

#### Side effects include:

- Red eyes for the first month or so (usually without significant pain)
- Longer, darker lashes
- Darkening of the iris and/or periocular skin
- Occasionally flu-like symptoms or muscle pain
- Occasional loss of some of the normal fatty tissue in the eye socket
- Exacerbation of asthma

## Beta Blockers

- Timolol 0.25–0.5%
- Levobunolol (Betagan)
- Betaxolol (Betoptic S)

Beta blockers are effective at reducing IOP but have some systemic side effects that may preclude their use. They may be prescribed twice daily or once a day, in the morning.

### Side effects include:

- Exacerbation of asthma or COAD
- Bradycardia (slow heart rate)
- Low blood pressure
- Fatigue
- Depression
- Impotence
- Loss of libido

## Alpha Agonists

- Brimonidine (Alphagan)
- Alphagan P (different preservative, Purite)
- Apraclonidine (Iopidine)

Alpha agonists are used two or three times a day, often as an adjuvant treatment. They should not be used in conjunction with monoamine oxidase inhibitor therapy. They are contraindicated in children under 7 years of age.

### Side effects include:

- Dry mouth
- Ocular allergic reactions (in 5–10% and often arising months after treatment initiation)
- Red eyes
- Stinging
- Headache
- Fatigue



## Carbonic Anhydrase Inhibitors (CAI)

- Brinzolamide (Azopt)
- Acetazolamide (Diamox) oral: 250mg tabs

CAI drops are often an adjunctive treatment. They are given twice a day.

### Side effects include:

- Burning or stinging on administration
- Late onset hypersensitivity with redness, pain, and swelling
- Taste perversion

Oral Diamox is commonly given as a short course as it is not often tolerated in the long term. It is given up to 250mg qid. If given long term, electrolytes must be monitored.

### Side effects include:

- Pins and needles in the extremities
- Metallic taste in mouth
- Nausea
- Malaise and GI upset
- Electrolyte imbalance
- Kidney stones

## Pilocarpine

- Pilocarpine 1, 2, 4% (Isopto-carpine)

Pilocarpine is usually used in angle closure glaucoma. It constricts the pupils. It may be prescribed up to four times a day.

### Side effects include:

- Headache
- Blurred vision
- Poor night vision
- Systemic parasympathetic overactivity (rare): salivation, sweating, nausea, vomiting, and diarrhea

## Combined Therapies

- Dortim 2x daily (Timolol + Azopt)
- Combigan 2 x daily (Timolol + Alphagan)
- Duotrav 1 x daily (Timolol + Travatan) Lattim 1x daily (Timolol + Latanaprost)

Combined therapies are designed to increase patient compliance so they can take one medication instead of two.

## 22.2 Steroid

Steroid drops are used to reduce inflammation within the eye. They may be used post-operatively or for ocular inflammatory conditions.

Severe ocular inflammation may require systemic steroids or sometimes steroid-sparing agents. The type of drop used is determined by its strength and penetration into the eye. Steroid drops may be prescribed from every hour (for severe inflammation) to once a day or sometimes every other day.

In order of strength, the available steroids are:

- Pred Forte (Prednisolone 1%)
- Maxidex (Dexamethasone 0.1%)
- Pred Mild (Prednisolone 0.12%)
- FML or Flucon (Fluorometholone 0.1%)

Preservative-free Prednisolone can be obtained when necessary.

### Side effects include:

- Vulnerability to secondary eye infection
- Exacerbation of occult fungal or viral infections
- 'Steroid response glaucoma' and associated high intraocular pressure
- Long term use may promote cataract and corneal thinning

Contact lenses should not be worn while using steroid drops.

## 22.3 Non-Steroidals

Non-steroidal eye drops are used for mild inflammatory and allergic conditions in the eye and post-operatively. They are usually used 3 or 4 times a day.

- Ketolarac (Acular)
- Diclofenac (Voltaren)
- Nepafenac (Ilevro) – only used once a day

### Side effects include:

- Painful stinging on instillation
- Nausea
- GI upset
- Headache
- Insomnia

They have similar contraindications as systemic non-steroidal drugs, but as dosage absorption is much less, they are much less likely to cause GI upset than orals.

## 22.4 Antibiotics

For most minor eye infections, Chloramphenicol or Fucithalamic drops are the most useful drops. Solframycin and Brolene are rarely used.

Blephamide and Bleph-10 are sometimes used for blepharitis. More serious eye infections may need to be treated with Ciprofloxacin or Tobramycin or Cefuroxime. In these cases, an ophthalmologist should be treating the patient. Rare eye infections such as fungal or Acanthamoeba keratitis may need special antibiotic formulations made for them, although Brolene is sometimes used for Acanthamoeba. Herpes Simplex (HSV) keratitis is treated with the antiviral agent Acyclovir.

Post-operatively, both a combined antibiotic and steroid like Maxitrol may be prescribed, or two separate drugs like Chloramphenicol and Pred Forte.

In minor eye infections, Chloramphenicol is prescribed 4 times a day. In HSV keratitis, Acyclovir is used 5 times a day.

- Chloramphenicol (Chlorsig drops or ointment)
- Fusidic acid (Fucithalamic)
- Dibromopropamidine (Brolene)
- Sulphcetamide (Bleph-10)
- Ciprofloxacin (Ciloxan)
- Tobramycin
- Gentamicin
- Cefuroxime
- Acyclovir 3% (Zovirax eye ointment)

### Combined Drops

- Maxitrol (Neomycin and Dexamethasone)
- Blephamide (Sulfacetamide and Prednisolone)

### Side effects include:

- Corneal toxicity
- Red eyes and discomfort (may relate to the preservative or the active ingredient)
- Chloramphenicol and Fucithalamic tend to be well tolerated
- Acyclovir commonly causes some corneal toxicity
- Other antibiotics vary in their corneal toxicity
- All may cause idiosyncratic allergic reactions

## 22.5 Mydriatics and Cycloplegics

Mydriatic agents are used to dilate the pupil for examination of the fundus. They have little or no cycloplegic action, but will usually make vision worse for a short period.

- Tropicamide (Mydracyl) – used when dilation of the pupil for a short duration (1–3 hours) is required.
- Phenylephrine – usually as an adjunct to Tropicamide to aid dilation of dark irides.

These agents should only be used with advice about the potential for inducing acute angle closure (rare and more commonly in hyperopes [far-sightedness]).

Cycloplegic drops are used to dilate the pupils, or to paralyse the ciliary muscle (relax accommodation). They may be used post-operatively (particularly in retinal surgery), in uveitis and other inflammatory conditions, and as a way of creating blur for amblyopia treatment. Atropine has the longest lasting effect of the cycloplegics. They are usually prescribed 1–3 times/day.

In order of strength and duration of effect they are:

- Atropine (Atropt) – lasts 2–3 weeks
- Homatropine – lasts 2–5 days
- Cyclopentolate – lasts 1–2 days
- Phenylephrine – lasts 6–12 hours

### Side effects include:

- Blurred vision
- Photophobia
- Urinary retention
- **In children:** beware of hallucinations, flushing, unusual behaviour
- **In infants:** beware of distended stomach

## 22.6 Ocular Lubricants

Ocular lubricants are the mainstay of treatment for dry eye, which may range from mild to severe. Commonly, patients underuse ocular lubricants and they should be encouraged to use them frequently.

There is no cure for dry eye and lubricants usually need to be used in the long term. Lubricating drops can be divided into those preservative-free or with preservative, and longer-lasting, thicker drops or shorter-acting thinner drops. Thicker drops and gels relieve symptoms for longer but often blur vision, while thinner drops blur vision less but their effect is shorter. People using very frequent lubricant drops should use preservative-free brands.

### Preservative-Free Drops:

- Bion tears
- Cellufresh
- Poly gel
- Celluvisc
- Refresh plus
- TheraTears
- Hylo Fresh and Hylo Forte

### With Preservative:

- Refresh tears plus
- Genteal eye drops
- Methocel
- Methopt and Methopt Forte
- Tears Naturale
- Polytears
- Liquifilm tears and Liquifilm forte
- Refresh
- Tears plus
- Systane
- Blink
- Optive

### Gels and Ointment:

- Lacrilube
- Polyvisc
- Viscotears
- Refresh Liquigel

### Side effects include:

- Blurring of vision at the time of instillation, especially for the thicker lubricants
- Reactions to the preservatives; in which case the patient should use preservative-free drops or change brands to one that contains a different preservative

## 22.7 Ocular Decongestants

These are generally purchased by patients over the counter. They contain alpha antagonists and constrict the blood vessels in the conjunctiva, making the eyes look white.

They have very little, if any, therapeutic use as they constrict the blood vessels, making the eye look whiter without treating the primary cause of redness. They can be easily abused and, when ceased, can frequently result in rebound redness (similar mechanism to nasal decongestants).

- Naphcon
- Albalon
- Visine
- Cleareyes

### Side effects include:

- Allergy (due to benzylkonium chloride [preservative component])
- Tingling or stinging of the eyes
- Rebound hyperaemia if used for greater than 3 days

## 22.8 Ocular Anti-Allergy

These fall into three broad categories: Antihistamines/Mast Cell Stabilisers/Combined Action. Some are available OTC whilst others are prescription only.

Antihistamines are useful for the symptom of itch and can reduce mild ocular allergy. Mast cell stabilisers reduce the histamine expression by the mast cells and so settle the disease. These drops need to be taken for some time before symptoms resolve and on a regular rather than PRN basis. Lomide and Patanol need to be taken twice a day. Mixed action drops address both the itch and overactivity of mast cells.

### Antihistamines:

- Livostin (Levocabastine)
- Albalon A (see above for Albalon)
- Naphcon A

### Side effects include:

- Allergy (due to benzylkonium chloride [preservative component])
- Mild stinging/burning
- Headache

### Mast Cell Stabilisers:

- Cromoclycate (Opticrom)
- Lomide (Lodoxamide)

### Side effects include:

- Allergy (due to benzylkonium chloride [preservative component])
- Stinging
- Burning
- Hyperaemia

### Mixed Action:

- Olopatadine (Patanol)

### Side effects include:

- Headache
- Burning
- Stinging
- Red eye



## 22.9 Intravitreal

Intravitreal injections are a common way of delivering drugs to the eye. The most common drugs used now are the anti-VEGF agents Avastin and Eylea.

These drugs directly target vascular endothelial growth factors (VEGF) which stimulate neovascularization and leaky vessels and so are used to treat abnormal blood vessels like choroidal neovascularization in AMD, diabetic retinopathy, and other vasculopathies like vein occlusions.

Avastin was developed as an anti-cancer drug and then discovered to have a good effect in the eye while Lucentis, Eylea, and Vabysmo were developed to be used in the eye. In New Zealand, Avastin is usually used because it is significantly cheaper; the other preparations may be subsidized or covered by insurance but not always.

Steroids are used to reduce inflammation in uveitis and in cases of chronic cystoid macular oedema (CMO). Triecence (a preservative-free steroid preparation) was most commonly used but supply chain issues mean some other similar preparations are used. Slow-release preparations like Ozurdex may be used for chronic conditions.

### Anti-VEGF:

- Bevacizumab (Avastin)
- Ranibizumab (Lucentis)
- Aflibercept (Eylea) or alternative Zaltrap
- Faricimab (Vabysmo)

### Steroids:

- Vitreal-S
- Ozurdex (slow-release implant of steroid)

### Side effects include:

- After the injection, the eye may be irritated and red for up to a week
- Floaters may be seen
- There is about 1/1000 chance of infection, and patients are warned to contact the clinic urgently if the eye becomes more painful, more red, or the vision declines
- Rarely, bleeding, retinal detachment, and cataract may be caused by the injection
- Steroid injections may cause raised intraocular pressure, and patients need regular, long-term follow-up for this

## 22.10 Cytotoxic Drugs

Mitomycin C and Fluorouracil (5FU) are used as topical preparations for treatment of some conjunctival tumors and as adjuncts to surgery to help reduce scarring.

They are potent medications, but their use is limited by their potential side effects. Patients are given extensive information about how to administer the drops and how to dispose of their containers safely.

- Mitomycin C
- Fluorouracil (5FU)

### Side effects include:

- Dry red eyes and corneal toxicity while taking drops
- Long term side effects include dry eye, scleral thinning, and melt, and, rarely, secondary tumors

## 22.11 Drops Used for Examination

Dyes like fluorescein and Lisamine green are used to define epithelial defects or other abnormalities in the surface layers of the cornea and conjunctiva.

They are not used for treatment. Similarly, topical anaesthetics like Benoxinate and Tetracaine are used during examination to enable comfortable manipulation of the eye for the removal of foreign bodies and for other procedures.

- Fluorescein
- Lisamine green
- Rose bengal
- Oxybuprocaine (Benoxinate)
- Amethocaine (Tetracaine)

### Side effects include:

- Stinging on administration
- Staining of contact lenses with dyes
- Corneal toxicity with frequent administration of topical anaesthetics and slowing of wound healing
- Rarely, allergic reactions



## 25 *Glossary and Index*

## A

**Accommodative esotropia** Esotropia caused by excessive convergence in a child with hypermetropia (long-sightedness) and usually most noticeable when the child focuses at a near target (272)

**Acid injury** Chemical injury to the surface of the eye from anything acidic. An ocular emergency that requires immediate copious irrigation (6)

**Acute angle closure glaucoma (AACG)** Rapid, marked rise in intraocular pressure. Occurs in eyes with narrow angles, and results from pupil block. An ocular emergency (127)

**Acute anterior uveitis (AAU)** Inflammation of iris and ciliary body (133)

**Acute retinal necrosis (ARN)** Inflammatory necrosis of the retina associated with viral uveitis (140)(143)

**Age-related macular degeneration** Degeneration of the central part of the retina, more prevalent with age. Leading cause of irreversible severe visual loss in the Western world (178)

**Albinism** Oculocutaneous albinism is autosomal recessive with hypopigmentation of hair, skin and eyes. Ocular albinism is usually X-linked recessive with ocular hypopigmentation only. Patients suffer decreased vision and photosensitivity (299)

**Alkali injury** Chemical injury to the surface of the eye from anything alkali. An ocular emergency that requires immediate copious irrigation (6)

**Amaurosis fugax** Fleeting loss of vision

**Amblyopia** The decrease in visual acuity caused by a disruption to normal visual experience during the critical period of vision development (270)(311)

**Amsler grid** Printed grid of small squares used by patients at risk of age-related macular degeneration to monitor for visual distortion. Also used as a diagnostic tool by clinicians (178)

**Angle Recession** Damage to the drainage angle/trabecular meshwork from blunt trauma to the eye. Predisposes the patient to glaucoma in later life (14) (125)

**Anisocoria** Difference in size between the two pupils (236) (255)

**Anisometropia** The term for when the two eyes have a significantly different refractive error (focusing error) (270)(283)

**Ankyloblepharon** Adhesion between the eye lids (60)

**Anterior blepharitis** Reddened inflamed lid margins due to a build up of lid commensals (mainly staphylococcus). Patients suffer dry gritty burning eyes (41)

**Anterior chamber tap** Where aqueous is removed from the anterior chamber and analysed for organisms

**Anterior Ischaemic Optic Neuropathy** Sudden loss of vision affecting one eye due to ischaemia of the optic nerve, most common in middle-aged patients, often with a history of hypertension. It is also referred to as non-arteritic ischaemic optic neuropathy (NAION) (235)

**Anterior scleritis** Inflammation of the sclera anterior to the equator of the globe (103)

**Anti-VEGF treatment** Treatment for active, exudative age-related macular degeneration is with intravitreal anti-VEGF therapy – e.g. Avastin or Lucentis (178)

**Arcuate scotoma** Arc-shaped visual field loss (either superior or inferior) typical of glaucoma (120)

### **Argon Laser Trabeculoplasty (ALT)**

A glaucoma procedure in which laser spots are placed around the trabecular meshwork to improve aqueous drainage. It is not usually an adequate treatment on its own but can be useful in supplementing eye drops (129)

**Artisan and Artiflex intraocular lenses** Also known as Verisyse and Veriflex. These are phakic intraocular lenses that sit in the anterior chamber clipped to the iris (320)

**Asteroid hyalosis** Degenerative condition involving small white opacities in the vitreous humor. Clinically, these opacities are quite refractile, giving the appearance of stars (or asteroids) shining in the night sky. The cause of asteroid hyalosis is unknown, but it has been associated with diabetes mellitus, hypertension, and hypercholesterolemia. Usually asymptomatic and no treatment is required

**Asthenopia** Otherwise known as “eye strain”. Manifests itself through nonspecific symptoms such as fatigue, pain in or around the eyes, blurred vision, headache and occasional double vision

**Atropine penalisation** A treatment for amblyopia in children, where atropine 1% drops are given to the better eye every alternate night, to blur the vision in the better eye and encourage use of the amblyopic eye (270)(272)

**Avastin** An anti-VEGF treatment used intravitreally for exudative age-related macular degeneration (178)

**Avellino dystrophy** Very rare autosomal dominant dystrophy with bilateral granular type opacities in the anterior corneal stroma, and lattice-like lines in the deeper stroma. Symptoms include reduced vision and sometimes recurrent corneal erosions (80)(89)

**Axial length** The length of the eye from front to back (cornea to retina). This measurement is used in formulae that indicate what power of intraocular lens to use in cataract surgery to achieve the desired refractive outcome (113)

## **B**

**Baarveldt tube** A small plastic tube used in glaucoma surgery. It is placed into the eye, usually in front of the iris, to drain aqueous to a reservoir plate under the conjunctiva superiorly (129)

**Bell’s phenomenon** Elevation of the eyes on closure of the lids. Present in 75% of the population (28)

**Benign Intra-cranial Hypertension (BIH)** see Idiopathic intra-cranial Hypertension (240)

**Best’s disease** Rare macular dystrophy, onset of symptoms usually in childhood with reduced vision (201)

**Binocular indirect ophthalmoscope (BIO)** A light device worn on the examiners head and used in conjunction with a lens to allow examination of the patient’s retina

**Bi-temporal visual field loss** Temporal visual field loss in both eyes, typical of a chiasmal lesion (242)

**Bleb** A collection of aqueous under the superior conjunctiva created during trabeculectomy surgery for glaucoma. A well-formed bleb usually indicates the trabeculectomy is working, whereas a flat bleb usually indicates the trabeculectomy has failed (129)

**Blended vision** Also called monovision. A technique used in presbyopic patients (using contact lenses), or after cataract surgery (using intraocular lenses), where one eye has distance focus and one eye has near focus. It offers a good overall range of vision, with a small sacrifice in quality of distance vision (113)(313)

**Blepharitis** A general term for inflammation of the lids, but most commonly used in relation to chronic lid margin disease. The terms anterior blepharitis and posterior blepharitis are used to differentiate the two main types seen (30)(41)

**Blepharophimosis** Autosomal dominant condition with horizontally shortened palpebral fissures, telecanthus, and severe bilateral ptosis (291)

**Blot haemorrhages** Small haemorrhages in the retina, typically in diabetic retinopathy, but also in vein occlusions and carotid occlusive disease (180)

**Blow-out fracture** Fracture of one of the orbital walls (19)

**Blunt trauma** The injury caused by blunt trauma to the eye and adnexa will depend on both the extent of energy transfer and target structure (12)

**Botox ptosis** Botulinum toxin can be used in the levator muscle in order to induce a ptosis to protect the cornea and encourage healing in cases of non-healing corneal ulcer. Especially useful in cases of neurotrophic ulcer (84)

**Branch retinal vein occlusion (BRVO)** Occlusion of a branch vein in the retina, most commonly seen in hypertension or diabetes. Usually causes reduced vision or a relative field defect, although may be asymptomatic. May require laser treatment, but often no treatment is indicated (184)

**Brown's syndrome** An ocular motility disorder thought to be caused by a tight or restricted superior oblique tendon. It results in hypotropia in the primary position that increases on adduction, and decreases on abduction, together with limitation in elevation of the eye in adduction (276)

**Bruch's membrane** Bruch's membrane is the innermost layer of the choroid between the retinal pigment epithelium and the choriocapillaris (199)

**Bulbar conjunctiva** the conjunctiva overlying the sclera

**Bull's eye maculopathy** A retinal cone dystrophy (201)

**Bullous keratopathy** Corneal oedema due to endothelial failure in the case of previous surgery, or in advanced corneal disease (96)

**Buphthalmos** The enlargement of the eye seen in children with glaucoma. The sclera is softer in children and with high intraocular pressure the eye will enlarge (298)

## C

**Capillary haemangioma of the retina** A vascular tumour consisting of large, tortuous capillaries. The lesions have high blood flow and are often multiple and bilateral. More than one lesion is highly likely to indicate von Hippel-Lindau disease (212)(227)

**Cataract** An opacity in the crystalline lens of the eye. Even though minor opacities can be seen on optometric/ophthalmological examination when relatively young, symptoms of a cataract such as reduced visions, halos and glare are not usually noticed until 60–70 years of age (108)

**Cavernous haemangioma** Orbital vascular lesion with gradual proptosis and optic nerve compromise if the lesion is situated in the orbital apex or becomes very large (212)

**Central areolar choroidal dystrophy** Choroidal dystrophy (201)

**Central retinal artery occlusion (CRAO)** A blockage in either the central retinal artery causing widespread retinal ischaemia and loss of vision. Caused by emboli (especially carotid or cardiac), thrombosis, giant cell arteritis, collagen-vascular disease and hypercoagulation disorders (182)

**Central retinal vein occlusion (CRVO)** Blockage of the central retinal vein resulting in unilateral, sudden, painless loss of vision. May lead to neovascularisation of the retina and iris (185)

**Central serous chorioretinopathy (CSR)** A localised serous detachment of the sensory retina in the macular area. Typically a sporadic, self-limiting condition (197)

**Centrocaecal scotoma** Horizontal oval defect in the field of vision situated between and embracing both the point of fixation and the blind spot (193)

**Chemosis** Conjunctival oedema, seen most commonly in allergic reactions, or in viral infections.

**Chiasmal lesions** The hallmark of these conditions is bi-temporal visual field loss, due to the neuro-anatomy of the chiasm and surrounding structures. The most common lesions to impact the chiasm are pituitary tumours with suprasellar extension. Other causes include sellar meningioma, craniopharyngioma, aneurysm, trauma, and inflammatory/infectious conditions (242)

**Choroidal folds** Undulations or wrinkles in Bruch's membrane, the retinal pigment epithelium, or the choroid. They can be caused by external pressure on the eye such as in orbital disease, or by low pressure within the eye, or be idiopathic. May be an asymptomatic finding or cause mild visual disturbance (199)

**Choroidal haemorrhage** An uncommon (< 1:2000) but potentially vision-threatening complication of intraocular surgery (110)

**Choroidal melanoma** May be pigmented (melanotic) or non-pigmented (amelanotic). They are more common in light-skinned people and are the most common form of ocular melanoma. The incidence in New Zealand is approximately 25 cases per year (225)

**Choroidal naevus** Common melanocytic lesions with a reported frequency of around 7%. The importance of documenting the presence of naevi relates to the life-time risk of malignant transformation (approximately 1%) and that the apparent naevus may in fact be a malignant melanoma of the choroid (223)

**Choroidal neovascularisation (CNV)** New choroidal vessels seen in macular degeneration (178)

**Choroideraemia** X-linked recessive choroidal dystrophy, causing significant early visual loss in males (201)

**Chronic external ophthalmoplegia** Progressive failure of eye muscle movement with ptosis, reduced eye movements, and weakness of orbicularis and facial muscles (28)

**Ciliary body** Structure in the eye that is responsible for aqueous production and also for accommodation of the eye (change of focus to near objects)

**Clear lens extraction** Also called refractive lens exchange. This is where the non-cataractous crystalline lens is removed to allow insertion of an intraocular lens to correct a patient's refractive error. It carries with it the same set of risks as cataract surgery (322)

## **Chronic open angle glaucoma (COAG)** (117)

**Collagen cross-linking** A treatment to stabilise the progression of keratoconus, involving application of riboflavin to the cornea which is then activated into creating corneal collagen cross links by ultraviolet radiation (87)

**Colobomas** Inferonasal defects in the choroid, retina and iris, that occur when the foetal cleft in the developing eye fails to close (294)

**Commotio retinae** Retinal oedema caused by physical trauma (12) (19)

**Cone dystrophy** Retinal dystrophy (201)

**Congenital cataract** Lens opacities present at birth. If significant it must be removed promptly in order to allow for visual development, otherwise dense amblyopia occurs (296)

**Congenital esotropia** A constantly manifest, large angle esotropia (in-turning of the eyes) arising in first 6 months of life (272)

**Congenital exotropia** A constant large angle exotropia (out-turning of the eyes), with onset at birth. Rare, with a high association with neurological and developmental abnormalities (274)

**Congenital glaucoma** Primary congenital glaucoma is rare but serious and needs to be dealt with promptly to minimise amblyopia and optic damage. Signs include enlarged corneal diameter and hazy cornea with elevated pressure and optic nerve cupping (298)

**Congenital hereditary endothelial dystrophy (CHED)** Autosomal recessive condition that causes bilateral corneal oedema in neonates, with severely reduced vision, amblyopia and nystagmus (89)

**Congenital nystagmus** A rhythmic, involuntary, to-and-fro movement of the eyes, presenting within 6 months of age, and associated with afferent visual system defects (289)

**Congenital ocular fibrosis syndrome** A rare restrictive strabismus secondary to fibrous replacement of the extraocular muscles, causing variable single or multiple muscle involvement, and is characterised by limitation in elevation of eyes with ptosis (276)

**Congenital ptosis** Congenital drooping of the lid, usually with dystrophy of the levator muscle (291)

**Congenital retinoschisis** Hereditary vitreoretinal degeneration (201)

**Conjunctival malignant melanoma** Rare, can arise de novo or from pre-existing naevus or primary acquired melanosis. Nodular brown or black mass on bulbar or tarsal conjunctiva. May have feeder vessels and may be mobile or fixed to underlying sclera. Treated by excisional biopsy, cryotherapy, and topical mitomycin C. Orbital or intraocular spread requires exenteration (removal of entire contents of orbit including conjunctiva, eye, lids, and muscles) (58)

**Conjunctival naevus** Benign pigmentation in the conjunctiva (58)

**Convergence insufficiency** A subset of intermittent exotropia that is manifest at near, and reflects the inability to maintain convergence on a near target. More common in teens and usually presents with diplopia or eye strain symptoms with reading (274)

**Corneal abrasion** Traumatic abrasion of the corneal epithelium (8)

**Corneal blood-staining** Where blood is “pushed” into the cornea by high intraocular pressure in the presence of blood in the anterior chamber. Causes permanent corneal opacity (43)



**Corneal decompensation** Oedema in the cornea that results from failure of the corneal endothelial cells, for example from disease such as Fuch's dystrophy, or from previous surgery. This results in reduced vision, and sometimes pain

**Corneal foreign body** (10)

**Cortical cataract** Opacities in the cortex of the lens (the layer immediately beneath the capsule of the lens). Can be a significant cause of disabling glare for some people (108)

**Cotton wool spots** Fluffy white patches on the retina, indicating areas of retinal nerve ischaemia. Seen mainly in diabetic retinopathy and hypertension (180)

**Crystalline keratopathy** Crystalline deposition in the cornea, including lipids in lipid keratopathy, immunoglobulins in multiple myeloma, urate in gout, cysteine in cystinosis etc. (92)

**Cup:disc ratio** The ratio of the optic cup to the overall size of the optic disc. Traditionally a normal ratio is 0.5 or less. Greater than that, or asymmetry between the discs, may indicate glaucoma (117)

**Cyclodiode laser** A treatment for some types of glaucoma or raised intraocular pressure. Diode laser energy is used to ablate the ciliary body and reduce aqueous production (129)

**Cycloplegic refraction** The term for checking the focus of the eyes while using drops that paralyse the accommodative system (311)

**Cystoid macular oedema (CMO)** Accumulation of fluid in the outer plexiform and inner nuclear layers of the retina in the foveal region. Multiple cystoids spaces lead to increased retinal thickness, and visual acuity reduced. The most common complication of routine cataract surgery, occurring in 1–5% of patients, and usually seen in the first few post-operative weeks. It is usually a self-limiting condition but will resolve more quickly if treated with topical steroid and non-steroidal drops (110)(195)

## D

**Dacryoadenitis** Inflammation of the lacrimal gland (208)

**Dacryocystitis** Infection of the lacrimal sac (32)

**Dacryocystorhinostomy** An operation to bypass the lacrimal drainage system (32)

**Deep anterior lamellar keratoplasty (DALK)** This is a partial thickness graft used for conditions where the patient's own endothelium/Descemet's layer is healthy. Only the stroma and epithelium are replaced. Keratoconus is the most common condition treated, but stromal dystrophies and anterior corneal scars are also suitable (96)

**Degenerative myopia** A level of myopia usually greater than minus-6 dioptries, where progressive elongation of the globe leads to degenerative changes in the retina and choroid (200)

**Dendritic ulcer** Linear branching shaped corneal epithelial ulcer, usually due to herpes simplex virus (67)

**Dermoids** Various dermal skin elements form a rounded elevated structure at the limbus, extending into the cornea. Dermoids need early assessment as they can induce astigmatism and affect the visual development, but they are best removed when the child is older. Dermoids may also be found in the orbit (210)(294)

**Descemet's stripping endothelial keratoplasty (DSEK)** This is a type of corneal transplant where only the endothelium and Descemet's layers of the cornea are replaced, and is used in conditions where the endothelium has failed but the corneal stroma is normal. The most common conditions are Fuch's endothelial dystrophy, and pseudophakic bullous keratopathy (endothelial failure after cataract surgery) (96)

**Diffuse lamellar keratitis (DLK)** Also known as Sands of the Sahara, this is a condition that occurs post-LASIK where inflammation develops underneath the corneal flap. Usually mild and responds to steroids but severe cases can lead to flap melting and can result in reduced vision (314)

**Dioptrie** The unit of measurement of focusing error in the eye

**Diplopia** Double vision that may be uniocular or binocular

**Disciform keratitis** Inflammation of the cornea that comprises an area of endothelial inflammation with overlying corneal oedema, usually centrally. Usually due to either herpes simplex virus or herpes zoster virus (67)(70)

**Dislocated intraocular lens** Also known as a subluxed intraocular lens. This refers to the dislocation of the artificial lens placed in the eye during cataract surgery. It can result from subsequent trauma, or in cases where there has been intraoperative complications (110)

**Downbeat nystagmus** Rhythmic, involuntary movement of the eyes up and down (fast phase down) Associated with craniocervical pathology (256)

**Dropped nucleus** This is when some of the lens nucleus falls back into the vitreous during surgery, either through a posterior capsule rupture, or a zonule dehiscence. Removal of retained nucleus material should take place promptly and completely via a pars plana vitrectomy (110)

**Drusen** Pale/yellow spots seen in the macular area in age-related macular degeneration (178)

**Duane's syndrome** A motility disorder due to a congenital miswiring of the medial rectus and lateral rectus muscles in one or both eyes, causing globe retraction on attempted adduction, and limitation of adduction, limitation of abduction, or both (252)(307)(276)

## E

**Ectropion** Condition where the eyelid rolls outwards (26)

**Ectropion uveae** The term used when the pupil margin rolls back on itself bringing forward the pigment from the back of the iris. Seen in some diseases of the iris, including melanoma, and also in cases of inflammation

**Electro-oculogram (EOG)** Recording of eye movements and eye position provided by the difference in electrical potential between two electrodes placed on the skin on either side of the eye

**Electro-retinogram (ERG)** Measures the electrical responses of various cell types in the retina, (including the photoreceptors (rods and cones), inner retinal cells (bipolar and amacrine cells), and the ganglion cells) to various stimuli (203)

**Elschnig spots** Clumps of retinal pigment with surrounding red or yellow halo. Indicate past episodes of acute hypertension (187)

**Endogenous endophthalmitis** Rare form of endophthalmitis that results in seeding of infection from another source in the body. Sources include endocarditis, liver abscesses, infected lines or catheters. It results in a very serious ocular infection that can be blinding (143)

**Endophthalmitis** Severe inflammation of all compartments of the eye, usually infective, but may be sterile. A rare, but very serious, complication of intraocular surgery. It constitutes a sight-threatening ocular emergency with main factors determining outcome being speed of presentation to an eye clinic, the causative organism, and the individual host pathogen response (110)

**Endothelial keratoplasty** See, Descemet's stripping endothelial keratoplasty (96)

**Enophthalmos** Where the eye is retracted into orbit, making the eye appear "smaller" or sunken (12) (19) (216)

**Entropion** Condition where the eyelids rolls inwards (27)

**Eucleation** Removal of the eye

**Epiphora** Excessive watering of the eye (32)

**Epiretinal membrane (ERM)** An epiretinal membrane looks like a piece of cellophane has been applied to the surface of the retina. In some progressive cases the retina becomes wrinkled if the membrane contracts (172)

**Episcleritis** A benign inflammation of the episclera (the vascular layer between the conjunctiva and the sclera). Seen most commonly in young adults (females more than males) and usually self limiting, although it may be recurrent. It is usually idiopathic but may occasionally be associated with systemic diseases similar to those associated with scleritis (101)

**Esotropia** In-turning of the eye (278)(311)

**Exenteration** Removal of the entire contents of the orbit (including conjunctiva, eye, lids, and muscles) to treat malignant tumours (216)

**Exophthalmos** Proptosis in thyroid eye disease (214)

**Extra-ocular muscles** Muscles that control eye movement. Six on each eye: Medial Rectus – moves the eye in; Lateral Rectus – moves the eye out; Superior Rectus – moves the eye up; Inferior Rectus – moves the eye down; Superior Oblique – moves the eye down and in, also rotates the eye; Inferior Oblique – moves the eye up and out, also rotates the eye

**Extracapsular cataract extraction (ECCE)** The method of cataract surgery used prior to 1995, and still occasionally a preferred method of surgery for extremely dense cataracts. It involves extraction of the nucleus of the lens in one piece through a 10 mm wound. ECCE is the "Fred Hollows" cataract procedure and is ideal in a third world environment, but less so when high quality outcomes are required (110)

**Exotropia** Out-turning of the eye (274)

## F

**Faden suture** A non-absorbable suture is used to secure the muscle to the scleral wall at least 15 mm posterior to the limbus. This limits the action of the muscle and is used on one eye to match a weakness on the other in order to maximise the zone of single vision (278)

**Familial dominant drusen** Hereditary condition affecting the retinal pigment epithelium (201)

**Familial exudative vitreoretinopathy** Hereditary vitreoretinal degeneration (201)

**Favre–Goldmann syndrome** Hereditary vitreoretinal degeneration (201)

**Femtosecond laser** Laser used in refractive surgery to create corneal flaps and channels (314)(309)(323)

**Fibrin** Webs and fibres of inflammatory material in the anterior chamber in inflammatory conditions

**Fluorescein** A fluorescent yellow dye used to highlight corneal epithelial defects

**Follicles** Yellow/pink lumps on inside of lids seen in viral conjunctivitis or chlamydial infection (52)

**Follicular conjunctivitis** Conjunctivitis with follicles, usually caused by adenovirus or chlamydia (52)

**Forniceal shortening** Shortening of the distance between the limbus and the fornix, seen in ocular cicatricial pemphigoid (60)

**Foster Fuch's spot** Hyperpigmented spot at the macula, seen in degeneration of the macula in case of high myopia (200)

**Fourth nerve palsy** The most common cause of vertical strabismus. The most common aetiology is congenital, or decompensation of a congenital fourth nerve palsy. Other causes include trauma, micro-vascular infarct, demyelinating disease and rarely tumour, giant cell arteritis, and hydrocephalus (250)

**Foveal hypoplasia** Underdevelopment of the fovea/macula, seen in albinism (289)(299)

**Fuch's endothelial dystrophy** Autosomal dominant or sporadic corneal dystrophy, with primary endothelial dysfunction resulting in progressive corneal oedema. Early symptoms are reduced vision, sometimes worse in the morning. As the condition progresses the vision deteriorates, and in later stages pain is experienced when bullae develop. Treatment is corneal transplantation (89)

**Functional vision impairment** Children may present with poor vision which turns out to be functional in origin. In other words the child can see perfectly well but performs poorly on testing. With functional impairment there is probably no deliberate attempt to falsify the vision but one must still consider the possibility of underlying psychological or social problems

**Fundus flavimaculatus** Retinal dystrophy (201)

**Fundus fluorescein angiography (FFA)**

A technique for examining the circulation of the retina. It involves injection of sodium fluorescein into the systemic circulation, and then an angiogram is obtained by photographing the fluorescence emitted after illumination of the retina with blue light

## G

**G Dx Scanning laser polarimetry** Use of polarised light to measure the thickness of the retinal nerve fibre layer (120)

**Giant cell arteritis (GCA)** This can be a vision-threatening condition resulting in ischaemic optic neuropathy, also known as arteritic ischaemic optic neuropathy (AION). It often presents asymmetrically and prompt recognition of the disease and aggressive treatment with steroids is required to potentially save vision in the fellow eye (236)

**Glaucoma** Optic neuropathy, usually due to raised intraocular pressure, but may also occur with normal intraocular pressure (117)

**Goldmann tonometry** The gold standard method of measuring intraocular pressure (120)

**Gonioscopy** slit lamp examination technique to assess the drainage angle in the eye (120)

**Goniotomy** Paediatric glaucoma operation where a needle or knife is passed across the anterior chamber and used to incise the trabecular meshwork (129)(298)

**Granular dystrophy** Rare autosomal dominant corneal dystrophy presenting in adulthood with deposition of hyaline material in the corneal stroma. Symptoms include reduced vision and sometimes recurrent erosions. Treatment usually involves corneal transplantation (80)(92)

**Gyrate atrophy** Choroidal dystrophy (201)

## H

**Hard exudates** Yellowish deposits seen in the retina in diabetic retinopathy (180)

**Hard lenses** Hard contact lenses, originally made of glass, and subsequently of poly methyl methacrylate (PMMA). Excellent optical properties but transmit oxygen poorly, hence no longer used (93)

**Heidelberg retina tomograph (HRT)** An instrument that provides a topographical map of the optic nerve head (120)

**Herpes zoster ophthalmicus (HZO)** Reactivation of dormant varicella zoster virus in the ophthalmic branch of the trigeminal nerve results in herpes zoster ophthalmicus (HZO). The eye itself is affected in less than 40% of cases, and usually presents with keratouveitis, although patients may less commonly develop conjunctivitis, glaucoma, retinitis, scleritis, optic neuritis, or cranial nerve palsies. Once the eye is affected with keratouveitis the condition can become chronic, recurring each time treatment is ceased, and sometimes recurring years after settling (70)(140)

**Heterochromia** A difference in iris colour between the two eyes(219)(221)

**Horner's syndrome** A condition that presents with unequal pupils (anisocoria), the smaller pupil being on the affected side. There is also ptosis, apparent enophthalmos and reduced sweating (anhidrosis). It can be congenital or acquired due to CVAs, tumours and vascular pathology (255)

### Hydrogel lenses

Contact lenses made of polymers of hydroxethyl methylacrylate, which are soft in nature making them much more comfortable to wear than hard or rigid lenses. These are the most common type of contact lens for correcting refractive error, and also for cosmetic lenses, but are not suitable for keratoconus or corneal irregularities (93)

**Hydrops** Sudden marked oedema of the cornea in patients with keratoconus. A spontaneous split in Descemet's membrane allows aqueous to flood into the corneal stroma. Usually resolves spontaneously over time (87)

**Hypermetropia/hyperopia** (Long-sightedness) Usually seen in eyes that are smaller than normal. Children are naturally hyperopic until age 7–8. Mild hyperopia can be overcome by the focusing muscles in the eye until the fifth decade at which point both near and distance vision may become blurred (but primarily near vision) (307)(311)

**Hypertropia** Strabismus with upward deviation of the visual axis of one eye

**Hyphaema** Haemorrhage inside the anterior chamber of the eye. Usually a result of trauma, but may also occur spontaneously, or in cases of intraocular inflammation or neo-vascularisation (12) (14) (125)

**Hypopyon** A “pool” of inflammatory cells settled at the bottom of the anterior chamber (96)(133)(143)(147)(151)

**Hypotropia** Strabismus with downward deviation of the visual axis of one eye

## I

**Idiopathic intra-cranial hypertension (IIH)** An idiopathic condition due to elevated cerebro-spinal fluid (CSF) pressure, usually in obese young women. Characterised by optic disc swelling with a potential for peripheral visual field loss associated with headache (240)

**Implantable contact lens (ICL)** Also known as the STAAR ICL. This is an intraocular lens that is placed in the eye in addition to the patient’s own crystalline lens to correct refractive error (320)

**Inclusion conjunctivitis** Conjunctivitis caused by Chlamydia trachomatis serotypes D to K (3–6)

**Incomitant esotropia** In-turning of the eyes where the angle of deviation varies with direction of gaze, such as sixth nerve palsy, medial orbital wall fracture, consecutive esotropia following surgery for exotropia, and Duane’s syndrome (235)(272)(276)

**Incomitant exotropia** Out-turning of the eyes where the angle of deviation varies with direction of gaze, and includes third nerve palsy, Duane’s syndrome, and consecutive exotropia that follows surgical overcorrection of an esotropia (274)(276)

**Infectious crystalline keratopathy** Feathery stromal opacities in the cornea, usually due to Streptococcus viridans, but may also be due to other organisms (92)

**Infiltrate** Opacity in the cornea, usually white or grey in colour, indicating either infection or inflammation (96)

**Intacs** Arcuate shaped polymethyl methacrylate (PMMA) implants that are inserted into the mid peripheral corneal stroma to induce a shape change thereby altering corneal power. Originally developed as a treatment for myopia, they are now used to correct early to moderate keratoconus and the iatrogenic corneal weakening keratectasia (323)

**Intraocular lens (IOL)** Artificial lens placed inside the eye at the time of cataract surgery (110)

**Intraocular pressure (IOP)** Pressure in the eye, normal range 10–21 mmHg. Usually raised in glaucoma (117)(120)

**Intermediate uveitis** Inflammation of the uveal tract, predominantly around the pars plana (area between ciliary body and peripheral retina), resulting in vitritis (137)

**Intermittent exotropia** The most common type of exotropia (out-turning of the eyes) in childhood, with onset from infancy to around 4 years old. Initially only noticed when the child is tired, sick or daydreaming. In the majority of children, the frequency and duration increases over time, and is usually most noticeable with distance fixation (274)

**Irido-dialysis** Iris becoming torn at the root creating holes in the periphery of the iris, usually due to trauma (14)

**Irido-corneal-endothelial syndrome (ICE)** A rare unilateral anterior segment condition in which the corneal endothelial cell layer is abnormal and behaves more like an epithelial layer, spreading over the angle and over the surface of the iris. Features include progressive iris atrophy, pupil abnormalities, glaucoma, and corneal oedema secondary to endothelial dysfunction (221)

**Iris bombé** Bulging forward of the iris with marked rise in intraocular pressure. Due to a build up of aqueous behind the iris due to pupil block (blockage of the normal flow of aqueous from the posterior chamber to the anterior chamber through the pupil) (125)

**Iris Haemangioma** Very rare iris tumours that may occur in children or adults. They appear as red, purple or brown lesions of the iris or pupil margin and may be confused with other iris lesions such as naevus, melanoma, xanthogranuloma, inflammatory granuloma (221)

**Iris melanomas** Can either be focal or diffuse, pigmented (melanotic) or non-pigmented (amelanotic). They are the rarest form of intraocular melanoma at 3–13% (219)

**Iris transillumination** Areas of thinning or atrophy of iris glow red/orange when light is shone directly through pupil onto the retina.

**Intraretinal microvascular abnormalities (IRMA)** Vascular abnormalities seen in severe non-proliferative diabetic retinopathy (180)

## J

### **Jerk nystagmus**

Nystagmus is rhythmic, involuntary, to-and-fro movement of the eyes. Jerk nystagmus may be either horizontal (associated with brainstem pathology), or upbeat (associated with medullary pathology) (256)(257)

**Juvenile xanthogranuloma** A rare, benign histiocytic lesion, occurring in children 2 years or younger. Most commonly it produces yellow or red-brown papular lesions of the skin, but in the eye it may be a cause of unilateral glaucoma, iris heterochromia or episodic blurred vision and pain from multiple spontaneous haemorrhages into the anterior chamber (spontaneous hyphaema) (221)

**Juxtapapillary** Adjacent to the optic nerve

## K

**Kearns-Sayre syndrome** Association of retinitis pigmentosa and chronic progressive external ophthalmoplegia (203)

**Keratectasia** A rare complication of corneal refractive surgery, where the cornea becomes progressively thinner and more distorted over time (314)(323)

**Keratic precipitates** Deposits of inflammatory cells on the corneal endothelium, seen in iritis and other inflammatory conditions in the anterior chamber, as well as in some types of keratitis (133)

**Keratoconus** A relatively common disorder with progressive conical distortion of the cornea due to ectasia (thinning). This results in increasing myopia (short-sightedness) and astigmatism. Presentation is usually in teens or early adulthood, and most cases are stable and non-progressive by the time the patients are in their mid-30s. Treatments include contact lenses, collagen cross-linking and corneal transplantation (87)

**Krukenberg spindle** A vertical line of pigment seen inferiorly/centrally on the corneal endothelium in pigment dispersion syndrome (125)

## L

**Lacquer cracks** Yellow subretinal streaks seen in degenerative myopia (203)

**Lacrimal sac** The upper dilated end of the nasolacrimal duct. Sits in the groove formed by the lacrimal bone and frontal process of the maxilla. It connects the lacrimal canaliculi, which drain tears from the eye's surface, and the nasolacrimal duct, which conveys this fluid into the nasal cavity

**Laser in-situ keratomileusis (LASIK)** A very accurate and predictable corneal refractive surgery technique to correct refractive errors. A flap is created in the cornea, either with a mechanical microkeratome (blade system), or a more advanced technique using a femtosecond laser called the Intralase. An excimer laser is then used to reshape the underlying cornea (314)

**Laser iridoplasty** A technique occasionally used for those with narrow anterior chamber angles who have had an insufficient opening of the angle with an iridotomy (129)

**Laser iridotomy** A small hole is created with a laser in the peripheral iris to allow the uninterrupted flow of aqueous from the posterior chamber to the anterior chamber in certain types of acute glaucoma (125)(127)

**Lattice degeneration** Peripheral retinal degeneration seen in myopic eyes (200)

**Lattice dystrophy** Rare autosomal dominant corneal dystrophy with progressive deposition of amyloid in the stroma. Corneas have criss-cross lines in the cornea and sometimes central corneal haze. Symptoms include reduced vision and recurrent corneal erosions (80)(92)

**Leber's congenital amaurosis** Retinal dystrophy (201)(289)

**Leucocoria** Abnormal white reflection from the retina of the eye seen in the pupil (294)

**Limbal stem cell deficiency** Lack of limbal stem cells due to chemical injury, surgical injury, or inflammation. Results in poor corneal epithelium, or non-healing epithelial defect (221)

**Limbus** Border between the cornea and sclera

**Lisch nodules** Small elevated areas of increased pigmentation on the iris which can be detected on slit lamp examination. Seen in neurofibromatosis Type 1 (221)

**Lucentis** An anti-VEGF treatment used intravitreally for exudative age-related macular degeneration (178)

## M

**Macula** Central part of the retina, responsible for central vision



**Macular dystrophy** Rare autosomal recessive dystrophy with deposition of glycosaminoglycan in the stroma and loss of corneal translucency from early adulthood. Corneas have focal ill-defined grey-white stromal opacities as well as diffuse corneal clouding. Symptoms are gradual painless vision loss. Treatment involves corneal transplantation (92)

**Macular hole** A full thickness defect at the macula which mimics a hole. In fact the circular deficit does not represent loss of retinal tissue but more of a vertical separation through the central retina. As such closure of this defect can restore central vision (174)

**Madarosis** Loss of eye lashes (24)

**Marginal keratitis** Common inflammatory reaction on the cornea due to hypersensitivity to staphylococcal exotoxin, hence also cause staphylococcal hypersensitivity. Usually seen in patients with chronic blepharitis or rosacea, and presents with pain, irritation and redness, as well as small peripheral corneal infiltrates/opacities (41)(76)

**Megalocornea** A non-progressive congenitally increased corneal diameter (296)

**Microaneurysms** Tiny red dots seen alongside vessels in the retina in diabetic retinopathy (180)

**Microkeratome** A blade system used to cut a thin flap in the cornea, used during refractive surgery (314)

**Migraine** Characterised by throbbing head pain, usually unilateral, accompanied by nausea, vomiting and photophobia. Blurred vision can precede the onset of headache symptoms by up to 60 minutes as an aura. Commonly patients describe the visual disturbance as flashing, zig-zagging, expanding lights that may be accompanied by expanding visual field defects (246)

**Mobius syndrome** Congenital aplasia of the sixth and seventh (+/- ninth and twelfth) cranial nerve nuclei, causing esotropia with limitation in abduction of the eyes, expressionless face, inadequate lid closure and risk of exposure keratopathy (252)(276)

**Molteno tube** A small plastic tube used in glaucoma surgery. It is placed into the eye, usually in front of the iris, to drain aqueous to a reservoir plate under the conjunctiva superiorly (129)

**Monofocal intraocular lens** Lens that are implanted in the eye during cataract surgery. Usually made of acrylic or silicone, and although they only have one focus distance they can provide extremely high quality vision (at the chosen distance) if the correct strength of lens is selected (113)

**Monovision** Also called blended vision. A technique used in presbyopic patients (using contact lenses), or after cataract surgery (using intraocular lenses), where one eye has distance focus and one eye has near focus. It offers a good overall range of vision, with a small sacrifice in quality of distance vision (113)(313)

**Myasthenia gravis** An autoimmune disease with impaired transmission across the myoneural junction, resulting in intermittent ptosis and diplopia. May be ocular only, but can also be systemic (257)

**Mydriasis** Enlargement of the pupil (12)

**Mydriatic** Drops used to enlarge the pupil

**Myectomy** A technique in squint surgery where a piece of the muscle is removed. This is done only to the inferior oblique muscle as it will retain some function through its muscle sheath (278)

**Myopia** Short-sightedness, where the focus of an image falls in front of the retina. Usually seen in eyes that are larger than normal. Distance vision is blurred but near vision is focused. Low and moderate degrees (up to minus 7 dioptres) usually stabilise by late teens, whereas higher degrees (greater than minus 7 dioptres) may be progressive and associated with retinal damage and poor vision (309)

**Myopic crescent** A crescent-shaped area of retinal atrophy that sometimes develops at the temporal border of disc (rarely nasal) of myopic eyes (200)

**Myositis** Inflammation of the extraocular muscles (208)

## N

**Nasal step** Nasal visual field loss (either superior or inferior) typical of glaucoma (120)

**Neurotrophic ulcer** A corneal ulcer that forms in a cornea that lacks sensation (84)

**North Carolina macular dystrophy** Retinal dystrophy (201)

**Non-proliferative diabetic retinopathy (NPDR)** Diabetic retinopathy that precedes the formation of new blood vessels in the retina (180)

**Neo-vascularisation elsewhere (NVE)** (180)

**Neo-vascularisation of the disc (NVD)** (180)

**Neo-vascularisation of the iris (NVI)** (180)

**Non-accommodative esotropia** In-turning of the eyes that may be constant or intermittent, and is caused by decompensation of fusional mechanisms. Rarely associated with CNS pathology (272)

**Non-arteritic ischaemic optic neuropathy (NAION)** Sudden loss of vision affecting one eye due to ischaemia of the optic nerve, most commonly in middle-aged patients, often with a history of hypertension. Specifically not caused by giant cell arteritis. Also known as anterior ischaemic optic neuropathy (AION) (235)

**Nuclear sclerosis (NS)** This is a progressive hardening and brunescence of the nucleus of the lens. Initially, this often causes improved reading vision along with a reduction in distance vision, but over time the brunescence progresses and cataract surgery is required to restore vision (108)

**Null point** Where nystagmus dampens in one direction of gaze (256)(289)

**Nystagmus** a rhythmic, involuntary, to-and-fro- movement of the eyes (256)(289)

**Nystagmus blockage syndrome** This is characterised by an esotropia (in-turning of the eyes) that occurs with a horizontal nystagmus, where the convergence of the eye is thought to dampen the nystagmus. A face turn head posture is frequently adopted (276)

## O

**Ocular cicatricial pemphigoid (OCP)** A rare autoimmune conjunctival inflammation that may produce relentless scarring resulting in eventual blindness. Its occurrence is unusual in patients younger than 55 years of age. The diagnosis should be considered in any case of chronic remitting relapsing conjunctivitis. Definitive diagnosis and systemic immunosuppression is essential to prevent progression (60)

**Ocular hypertension**

This is when the intraocular pressure is elevated but there is no optic nerve damage. Some of these people will develop glaucoma over time (117)

**Ocular surface squamous neoplasia (OSSN)** This includes pre-invasive conjunctival intraepithelial neoplasia (CIN), and invasive squamous cell carcinoma (SCC). It occurs especially in white males, middle aged and older, and incidence increases closer to the equator. Usually asymptomatic and first noted as a visible lesion on the eye. Prompt treatment is usually successful (56)

**Ophthalmia neonatorum** Early onset conjunctivitis may be due to tear duct obstruction but one must consider the possibility of ophthalmia neonatorum. The two most likely infective agents are gonococcus (presents 3–5 days after birth) and chlamydia (5–14 days postnatally), but it may also be caused by staphylococcus and streptococcus (293)

**Optic nerve gliomas** Gliomas that involve the orbital, intracranial or chiasmal components of the optic nerve in neurofibromatosis type 1 (305)

**Optic nerve hypoplasia** Maldevelopment of the optic nerve, the degree of which determining the visual potential. If it is bilateral then paediatric assessment and scanning to look for midline brain defects is required. With bilateral optic nerve hypoplasia one must always consider Septo-Optic Dysplasia (de Moursier's Syndrome) where involvement of the hypothalamus and pituitary can lead to hormone deficiencies and growth and developmental retardation (304)

**Optic neuritis** Also known as retrobulbar optic neuritis. An acute inflammatory condition of the optic nerve resulting in rapid monocular vision loss. It occurs in young patients 15–45 years and is more frequently seen in females. The cause is usually idiopathic but may also be the initial presenting sign of multiple sclerosis (233)

**Optical coherence tomography (OCT)** An instrument that measures the thickness of the retinal nerve fibre layer (120)(178)

**Orbital cellulitis** As opposed to pre-septal cellulitis in which infection is limited to anterior structures, orbital cellulitis is a more severe and potentially sight-threatening disorder. Infection is usually from adjacent structures such as the lid, lacrimal system or sinuses, but rarely can be blood borne (206)

**Orbital decompression** Surgical treatment for proptosis in thyroid eye disease (214)

**Orbitotomy** Surgical approach to removing orbital tumours (216)

**Orthokeratology** Also called Ortho-K. A technique to treat low levels of myopia. Hard contact lenses are worn overnight to induce semi-permanent changes in corneal shape (309)

**Oscillopsia** Visual disturbance in which objects in the visual field appear to oscillate due to nystagmus. (Acquired) (256)

## P

**Pachymetry** The measurement of corneal thickness (120)

**Pan-retinal photocoagulation (PRP)** Laser treatment to the periphery of the retina to reduce or reverse the formation of new blood vessels in the retina in diabetic retinopathy and other causes of neo-vascularisation such as central retinal vein occlusion (184)(189)

**Papillae** Multiple fine red lumps (velvet appearance) or larger “cobblestone” lumps in the conjunctiva. Most commonly seen with allergic conjunctivitis and bacterial conjunctivitis (45)(48)

**Papilloedema** Swelling of the optic disc from increased intracranial pressure. It must be differentiated from optic disc swelling due to other causes. Bilateral papilloedema is particularly suggestive of increased intracranial pressure which can be due to reasons such as brain tumours, central nervous system inflammation, or idiopathic intracranial hypertension (IIH) (238)

**Pars plana** The area between the ciliary body and the peripheral retina

**Pattern dystrophy** Retinal dystrophy (201)

**Pellucid marginal degeneration** A relatively rare progressive ectasia of the inferior peripheral cornea (86)

**Penetrating eye injury** Leading cause of monocular visual loss. There is usually a history of sudden visual loss in association with an activity involving a potential penetrating object. Common examples include car crashes, hammering metal, machinery, nail guns, falls with sharp objects (scissors, knives), and airguns or firearms (16)

**Penetrating keratoplasty**

A type of corneal transplant where the full thickness of the cornea is replaced, usually the central 7 to 9 mm. Until recently this was the most common type of graft, although newer partial thickness (lamellar) grafting techniques have superseded it for many conditions. It remains the graft of choice for full thickness trauma and scars of the cornea, for corneal perforations, and for advanced keratoconus (96)

**Perception of Light (PL)** Ability to discern light from dark in general direction of light source

**Peripheral anterior synechiae** Adhesions between the iris and the peripheral cornea (125)

**Peripheral iridectomy** Removal of piece of peripheral iris (129)

**Perkins tonometry** A handheld device that measures intraocular pressure (120)

**Persistent hyperplastic primary vitreous (PHPV)** Rare congenital developmental anomaly of the eye that results following failure of the embryological, primary vitreous and hyaloid vasculature to regress (296)

**Peter's anomaly**

Developmental abnormality with a central corneal opacity with strands of iris adherent to the posterior corneal surface and a high risk of glaucoma (294)(298)

**Phacoemulsification** Contemporary cataract surgery technique. The crystalline lens is removed via a small 2–3 mm wound, using ultrasound energy via a small probe to emulsify the lens before removal. A foldable acrylic or silicone lens is then inserted through the same small wound. Recovery is rapid, and excellent visual outcomes are normally achieved (110)

**Phakic intraocular lenses** These are intraocular lenses that are put into the eye as an addition to the natural crystalline lens. They are used to treat refractive error, offering an alternative to excimer laser vision correction and are generally reserved for patients who have a focusing error that is outside the limits of correction by laser (320)

**Phakomatoses** These conditions are characterised by the formation of hamartomas, proliferations of tissue normally found in the organ, in multiple organ systems including the eyes. Includes Sturge–Weber syndrome, Neurofibromatosis Type 1 and tuberous sclerosis (305)

**Photo refractive keratectomy (PRK)** A refractive surgery technique. Unlike with LASIK where a corneal flap is created in PRK the epithelium is removed and the cornea underneath is lasered directly. Superseded by LASIK, but still used for some patients with thin corneas. Visual outcomes are as good as LASIK, but the healing process is slower and more painful (318)

**Photodynamic therapy (PDT)** Treatment for some types of age-related macular degeneration and some types of ocular tumour. It involves injection of a dye called Visudyne, followed by laser energy applied to the eye which activates the Visudyne to close blood vessels (178)

**Photophobia** Discomfort or pain in the eyes due to light

**Phthisis bulbi** A shrunken, non-functional eye that results from severe ocular disease, inflammation, or injury

**Physiologic blind spot** The normal blind spot in the eye (238)

**Pigment dispersion syndrome** A condition where the iris bows backwards and the posterior pigment layer rubs on the lens zonules. This releases pigment into the aqueous which can then clog the trabecular meshwork and cause raised intraocular pressure. There is usually a vertical streak of pigment on the corneal endothelium called a Krukenberg spindle (125)

**Pigmentary retinopathy** Retinitis pigmentosa (201)

**Pingueculum** Creamy or yellow triangular area of conjunctival thickening adjacent to the limbus medially or laterally (54)

**Polycoria** More than one pupillary opening in the iris

**Posterior blepharitis** Also referred to as meibomian gland dysfunction. An extremely common condition affecting as much as 50% of the population to some degree. There is inflammation of the meibomian glands resulting in a lack of healthy meibomian secretions which causes symptoms of dryness, burning and irritation. It is often associated with rosacea (62)

**Posterior capsule rupture** A complication during cataract surgery where the posterior capsule of the lens is accidentally ruptured. In most cases this presents no problem, but it does increase the risk of cystoid macular oedema, endophthalmitis and post-operative intraocular lens dislocation (110)

**Posterior chamber tap** Where fluid or vitreous is removed from the posterior segment and analysed for organisms

**Posterior polymorphous dystrophy** An autosomal dominant condition in the cornea. The appearance of the cornea is variable but often clusters or lines or vesicles are seen on the endothelium. Also seen are irregular bands or diffuse haze in the cornea. Treatment is usually not necessary but if there is significant vision loss corneal transplantation may be considered (89)

**Posterior scleritis** Inflammation of the sclera posterior to the equator of the globe which may be severe and destructive (105)

**Posterior Subcapsular Cataract** A type of cataract more common in metabolic or inflammatory disease. Reading or bright light vision is often affected more than that in lower light and it may also be a cause of significant glare (108)

**Posterior synechiae** Adhesions between the iris (usually pupil margin) and the lens (125)(133)

**Posterior vitreous detachment (PVD)** A physiological age-related phenomenon where the vitreous gel in the eye undergoes collapse. The patient experiences flashes and floaters. The risk for patients with a symptomatic PVD is the development of a retinal tear, a precursor for a retinal detachment (164)

**Post-operative uveitis** Normally in the post-operative period after cataract surgery topical steroid drops are required for a period of 2–4 weeks. On occasion these may need to be recommenced for a further few weeks if uveitis develops on initial drop cessation. Symptoms are persistent photophobia, redness, and ache (6–2)

**Presbyopia** The age-related loss of near or reading vision associated with decreased function of the natural crystalline lens. It is inevitable for all eyes and becomes symptomatic in patients with good distance vision at an average age of 45. For those who have hyperopia it may be earlier, for those who have myopia it may be later (313)

**Presbyopia correcting intraocular lenses** Similar to standard intraocular lenses, but differ in their ability to provide both near and distance vision in the same eye. There are several different types, all of which have subtle nuances regarding function and none will restore the quality of vision experienced by most people in their earlier years. They do however now offer a good chance of spectacle independence after cataract surgery (113)

**Primary acquired melanosis** Conjunctival pigmentation that develops in mid-life and has the potential to become malignant in some cases (58)

**Primary intraocular lymphoma** Intraocular lymphoma may be primary, arising in the retina or vitreous, or less commonly secondary due to metastatic spread of systemic lymphoma. Primary intraocular lymphoma is a subset of primary central nervous system lymphoma (PCNSL) and intracranial disease develops in over two-thirds of patients who initially have isolated ocular disease (230)

**Proliferative diabetic retinopathy (PDR)** Diabetic retinopathy that includes dot and blot haemorrhages, and cotton wool spots, but also new vessel formation at the disc, retina or iris (180)

**Proptosis** Forward displacement of the eye due to orbital tumours or inflammation, or thyroid eye disease (214)(216)

**Pseudo-esotropia** Where there is no true strabismus, and the apparent in-turning of the eyes is an illusion caused by the lid contour, or a prominent epicanthal fold, or a broad base of nose (272)

**Pseudoexfoliation** This is a basement membrane disease that manifests only in the eyes. It produces a flakiness to the anterior capsule of the lens and this material may block the trabecular meshwork and cause intraocular pressure elevation (125)

**Pseudomembranes** Sheets of white/grey tissue on the conjunctiva that peel off easily. Seen typically in adenoviral conjunctivitis (50)

**Pseudotumour cerebri (PTC)** See Idiopathic intra-cranial hypertension (IIH) (240)

**Pterygium** Redness and thickening of the conjunctiva, extending over the limbus onto the cornea. Usually medial, but can be lateral. Small ones require no treatment but larger ones may require surgical removal (54)

**Ptosis** Drooping of the upper lid 2 mm or greater below the normal height. Involutional ptosis is by far the most common form of acquired ptosis but other forms such as neurogenic (third nerve palsy or Horner's syndrome), myogenic, mechanical, traumatic and myasthenic ptoses are seen (28)

**Pupil block** This is when the pupil margin adheres to the lens and blocks flow of aqueous from the posterior chamber to the anterior chamber. In turn this causes bowing forward of the iris which blocks the drainage angle and leads to acute marked pressure rise (acute angle closure glaucoma) (127)

## R

**Recession** A surgical technique to weaken a muscle by repositioning it more posteriorly on the sclera. For example, recession of the medial recti is done to correct an esotropia (278)

**Red desaturation** The optic nerve is sensitive to red, so when it is damaged, red-coloured objects may appear washed-out or faded. Some patients who have optic neuropathy describe a red colour as appearing orange or pink (233)(242)

**Red reflex** Refers to the reddish-orange reflection from the eye's retina that is observed when using an ophthalmoscope, retinoscope or slit lamp

**Refraction** This refers both to the focusing error of the eye (myopia, hypermetropia, astigmatism) and also the technique used to measure it

**Refractive error** Focusing errors – myopia, hyperopia, or astigmatism

**Refractive lens exchange** Also called clear lens extraction. This is where the non-cataractous crystalline lens is removed to allow insertion of an intraocular lens to correct a patient's refractive error. It carries with it the same set of risks as cataract surgery (322)

**Regression** This is the term used for loss of treatment effect after corneal refractive surgery (314)(318)

**Rejection** The commonest cause of corneal graft failure. Usually the endothelium is rejected but the stroma and epithelium can also be rejected. If treated early full recovery can be expected, but even a short delay in diagnosis and treatment can lead to irreversible graft failure. Symptoms are very variable (and often mild) but include reduced vision, redness, and pain. All graft patients are advised to seek immediate help if they suffer any of these symptoms (96)

**Relative afferent pupillary defect (RAPD)** A sign observed during the swinging-flashlight test whereupon the patient's pupils constrict less (therefore appearing to dilate) when a bright light is swung from the unaffected eye to the affected eye. The affected eye still senses the light and produces pupillary sphincter constriction to some degree, albeit reduced. The most common cause of an RAPD is a lesion of the optic nerve (proximal to the optic chiasm) or severe retinal disease (182)(185)(259)(235)(236)(238)(240)

**Resection** A surgical technique to strengthen a muscle by removing a measured section and resuturing the muscle to the original insertion. For example, resection of the lateral recti may be used to correct an esotropia (278)

**Retinal break** Breaks in the retina that can be spontaneous or as a result of trauma. Breaks can lead to retinal detachment (203)

**Retinal detachment** The generic term "retinal detachment" refers to a separation of the retina from the retinal pigment epithelium. Rhegmatogenous retinal detachment (RRD) is when that separation occurs as a consequence of a retinal break; traction retinal detachment is when the retina is pulled off the wall of the eye by scar tissue; and serous retinal detachment is caused by fluid developing under the retina rather than entering through a break (168)(170)

**Retinal dysgenesis** Rare condition arising through maldevelopment of the retina with features resembling retinal detachment (323)

## Retinal dystrophy (201)

**Retinal pigment epithelium (RPE)** The pigmented cell layer just outside the neurosensory retina that nourishes retinal visual cells, and is firmly attached to the underlying choroid and overlying retinal visual cells

**Retinitis pigmentosa (RP)** A group of hereditary disorders involving progressive loss of photoreceptor and retinal pigment epithelium function. Typical RP is a diffuse, bilateral, symmetrical, retinal dystrophy with damage to rod function predominant. Progressive difficulty with night vision and eventual night blindness and loss of peripheral vision. Poor central vision and colour vision occur relatively late in the disease (201)(203)

## Retinopathy of prematurity (302)

**Retinopexy** Refers to the surgical technique of sealing retinal breaks by either laser or cryotherapy (176)

**Retinoschisis** This is a splitting of the retina. Mostly asymptomatic, although a minority of patients are aware of a peripheral field defect. All patients need to be aware of the low risk of developing a retinal detachment and or extension of the defect to involve the macula (175)

**Retinoscope** Hand-held instrument used to bounce light off the retina in conjunction with different strength lenses, with assessment of the reflected light allowing accurate measurement of focusing errors in the eye (283)

**Retrobulbar optic neuritis** Also known as optic neuritis. An acute inflammatory condition of the optic nerve resulting in rapid monocular vision loss. It occurs in young patients 15–45 years and is more frequently seen in females. The cause is usually idiopathic but may also be the initial presenting sign of multiple sclerosis (233)

**Retrochiasmal lesions** Lesions that involve the visual pathway posterior to the chiasm, resulting in homonymous patterns of visual field loss affecting both eyes. The most common cause of a retrochiasmal lesion is a CVA often in association with hypertension, but may also occur with intracranial tumours (244)

**Rhegmatogenous retinal detachment (RRD)** The generic term “retinal detachment” refers to a separation of the retina from the retinal pigment epithelium. Rhegmatogenous retinal detachment is when that separation occurs as a consequence of a retinal break, usually with the configuration of a tear (168)

## Rigid gas permeable lenses (RGP)

Contact lenses that are rigid in nature and made of complex polymers. They provide good transmission of oxygen, but can be uncomfortable to wear. Because of their rigidity the space between the lens and the cornea becomes filled with tears (the “lacrimal lens”) which neutralises corneal astigmatism and surface irregularities and hence they are the lens of choice for patients with keratoconus and corneal scars (87)(93)

**Roth spots** Retinal haemorrhages with white or pale centres. Usually seen in bacterial endocarditis, but also seen in diabetes and leukaemia (193)

**Rubeotic glaucoma** Retinal ischaemia from, for example, severe diabetic disease or a retinal vein occlusion results in the release of vasoproliferative substances such as vascular endothelial growth factor. This can result in neo-vascularisation of the iris and these new vessels can cause scarring in the angle which leads to a very difficult type of secondary angle closure glaucoma (125)



## S

**Sands of the Sahara** Also known as diffuse lamellar keratitis (DLK) This is a condition that occurs post-LASIK where inflammation develops underneath the corneal flap. Usually mild and responds to steroids but severe cases can lead to flap melting and can result in reduced vision (314)

**Scleral buckling** A method of re-attaching the retina in cases of retinal detachment, sometimes called conventional treatment (176)

**Sclerocornea** An opacified patch extending from the edge of the cornea (limbus) caused by that part of the cornea being structurally similar to sclera (278)

**Scleromalacia perforans** A form of anterior scleritis (103)

**Scotoma** Area of diminished vision in the visual field (120)

**Sensory esotropia** In-turning of the eye that occurs as a result of vision loss in the turned eye (272)

**Sensory exotropia** The divergence of an eye with poor vision (274)

**Serous retinal detachment** Retinal detachment caused by fluid developing under the retina rather than entering through a break. There are dozens of possible causes of serous detachment but the most important are inflammatory (including infection), and neoplastic (170)

**Silicone hydrogel lenses** Soft contact lenses that are particularly permeable to oxygen. It is possible to wear them therefore overnight. "Extended wear" contact lenses are silicone hydrogel lenses that are worn day and night and replaced each month. When worn as extended wear there is a significantly higher risk of infective keratitis (93)

**Sixth nerve palsy** Binocular horizontal diplopia, worse in the direction of the paretic lateral rectus muscle (252)

**Snowball opacities** Large clumps of cells in the inferior vitreous (137)(140)

**Sorsby's dystrophy** Retinal dystrophy (201)

**Spasmus nutans** Acquired nystagmus that may have a benign self-limiting course, with onset in infancy, and resolving within 2 years (289)

**Spontaneous venous pulsation** Normal pulsation of the vein seen in the optic disc (238)

**STAAR ICL** Also known as an implantable contact lens (ICL). This is an intraocular lens that is placed in the eye in addition to the patients own crystalline lens to correct refractive error (320)

**Stargardt dystrophy** Retinal dystrophy (201)

**Stationary night blindness** Retinal dystrophy (201)

**Stereopsis** The process in visual perception leading to the perception of depth from the two slightly different projections of the world onto the retinas of the two eyes (270)

**Stickler syndrome** Hereditary vitreoretinal degeneration (201)

**Strabismus** Condition in which the eyes are not properly aligned with each other

**Stromal keratitis** Inflammation or infection of the corneal stroma

**Subacute angle closure** A precursor to acute angle closure glaucoma. Recurrent episodes of aching pain, blur and haloes around lights at night time (127)

**Subconjunctival haemorrhage** Haemorrhage under the conjunctiva. May occur spontaneously or as a result of trauma. Resolves spontaneously

**Subluxation** Dislocation of the lens in the eye

**Subtarsal foreign body** Foreign bodies can become trapped under the upper lid. It is easy to miss these unless the eyelid is everted for examination (10)

**Superficial lamellar keratoplasty** This is a partial thickness corneal graft where only the anterior stroma is replaced. It is used for superficial scars, and has the same benefits as a deep anterior lamellar keratoplasty (96)

**Supranuclear paresis (palsy)** Sudden onset vertical diplopia due to thalamic lesions such as infarction, with ataxia and somnolence. Also seen with demyelination/metabolic disorders (247)

**Symblepharon** Adhesions between bulbar and tarsal conjunctivae (50)(60)

**Sympathetic ophthalmia** Inflammation that can occur in a fellow eye subsequent to severe damage or penetrating injury to an eye. If the prospect for return of vision to the injured eye is very poor the eye may be removed to decrease the risk of sympathetic ophthalmia to the other eye (16)

## T

**Tarsal conjunctiva** Conjunctiva lining the inside of the lids

**Tarsorrhaphy** Temporary or permanent closure of the eyelids to protect the cornea

**Tenotomy** A surgical technique done to weaken the superior oblique tendon (278)

**Terrien's marginal degeneration** Corneal degeneration with peripheral corneal thinning, but intact epithelium. The condition is often bilateral and may occur at any age, although it typically occurs in middle-aged males. Asymptomatic, or resulting astigmatism may cause reduction in visual acuity

**Thyroid eye disease (TED)** Thyroid-related eye disease is a condition characterised by an acute inflammatory phase followed by a more chronic fibrotic phase. The disease process typically runs for about 2 years and is usually associated with hyperthyroidism (Graves' Disease) (214)

**Tolosa-Hunt syndrome** Inflammation at the orbital apex (208)

**Tonopen** An small portable instrument used to measure intraocular pressure (120)

**Toric intraocular lenses** These are similar to standard intraocular lenses in that they only have one focus distance, but they also incorporate correction for astigmatism. 20% of all patients undergoing cataract surgery have sufficient astigmatism in their cornea to benefit from a toric intraocular lens (113)

**Trabecular meshwork** Spongy tissue located around the base of the cornea in the angle, responsible for draining the aqueous humor from the eye (125)(127)(129)

**Trabeculectomy** A surgical procedure for glaucoma. A partial opening is made through the sclera, allowing aqueous to drain into a blister or "bleb" under the conjunctiva superiorly. This surgery has an 80–90 % success rate (129)

**Trabeculotomy** A paediatric glaucoma procedure (129)

**Traction retinal detachment** A type of retinal detachment where the retina is pulled off the wall of the eye by scar tissue. This is most common in advanced diabetic retinopathy, in which proliferating new vessels at the posterior pole can contract causing loss of central vision (170)

**Transient light sensitivity syndrome (TLSS)** Photophobia that occurs after LASIK in less than 5% of patients. It normally responds well to topical steroids (314)

**Trichiasis** Misdirection of eyelashes towards eye (30)

**Triple procedure** This is where cataract surgery and intraocular lens implantation are carried out at the same time as a corneal graft procedure (96)

## U

**Urrets-Zavalía syndrome** Fixed dilated pupil that can rarely occur after corneal transplanation

## V

**Verisyse and Veriflex intraocular lenses** Also known as Artisan and Artiflex. These are phakic intraocular lenses that sit in the anterior chamber clipped to the iris (320)

**Visual evoked potential (VEP)** An evoked potential caused by a visual stimulus, such as an alternating checkerboard pattern on a computer screen. Response is recorded from brain waves by using electrodes taped to the head

**Vitelliform maculopathy** Best's disease (201)

**Vitrectomy** This is a surgical procedure that involves removal of the vitreous for therapeutic or diagnostic purposes (177)

**Vitreous tap** Where fluid or vitreous is removed from the posterior segment and analysed for organisms

**Vitritis** Accumulation of inflammatory cells or exudates in the vitreous humour (137)

**Von Hippel-Lindau disease** Capillary haemangioma of the retina is a vascular tumour consisting of large, tortuous capillaries. The lesions have high blood flow and are often multiple and bilateral. Early tumours can become apparent in childhood and gradually enlarge and proliferate throughout life. More than one lesion is highly likely to indicate von Hippel-Lindau disease, with multiple systemic associations including CNS haemangiomas and kidney tumours (227)

**Vortex keratopathy** Deposits in the corneal epithelium caused by certain drugs, most commonly amiodarone. Also seen in Fabry's disease. Patients are usually asymptomatic. On examination with the slit lamp brown/grey lines are seen to radiate out from a point in the lower central cornea (92)

## W

### Weiss ring

A ring-shaped floater in the vitreous in front of the optic disc. It is pathognomonic of a posterior vitreous detachment (164)

**Wilson's disease** Also called hepatolenticular degeneration. Rare autosomal recessive condition with a deficiency in a copper-binding protein and hence copper deposition throughout the tissues. The patient does not usually have any ocular symptoms. A brownish ring is seen deep in the peripheral cornea at the level of Descemet's (92)

## Y

**YAG laser iridotomy** A treatment for angle closure glaucoma where the YAG laser is used to make a small hole in the peripheral iris in order to allow free flow of aqueous from the posterior chamber to the anterior chamber. May also be done prophylactically to prevent angle closure in patients with narrow angles (7-5, 7-6)(127)(129)

## Z

**Zonule dehiscence** This is when the suspensory ligaments of the crystalline lens (the zonules) are weak or broken. This is more common in advanced cataracts, psuedo-exfoliation syndrome, or trauma, and makes cataract surgery technically challenging (110)(113)(125)

**Zonules** (125)



# Refractive Lens Exchange (RLE)

## Experience clear vision with lifestyle lenses

Refractive lens exchange (RLE) is the perfect solution, especially for those in their 40s and 50s looking to enhance their vision.

This ground breaking procedure replaces your eye's natural lens with a premium artificial lens (IOL), correcting focusing errors and bringing sharp clarity back to your life—no more need for reading glasses, bifocals, or graduated lenses!

## Why Choose Refractive Lens Exchange?



### Permanent Vision Correction

Say goodbye to glasses and contact lenses for good!



### Advanced Technology

Benefit from state-of-the-art surgical techniques and top-of-the-line premium lenses.



### Expert Surgeons

Trust your vision to our experienced ophthalmologists who specialise in RLE.



### Quick Recovery

Experience minimal downtime so you can swiftly get back to the activities you love.

Want to see better – better see Auckland Eye

Q [aucklandeye.co.nz](http://aucklandeye.co.nz)

e. [admin@aucklandeye.co.nz](mailto:admin@aucklandeye.co.nz)

p. 0800 25 53 93



**AUCKLANDEYE**  
Life Changing Eye Care



## 26 *Referral Guide*

## 26.1 Auckland Eye specialists



**Dr Archie McGeorge**

Cataract, Medical Retina,  
Vitreous-Retinal Surgery



**Dr Alison Pereira**

Cataract, Medical Retina



**Dr Aaron Wong**

Cataract, Glaucoma



**Dr Chi-Ying Chou**

Cataract, Glaucoma,  
Cornea/Anterior Segment



**Dr David Pendergrast**

Cataract, Cornea/ Anterior Segment, Laser/  
Refractive Surgery



**Dr Dean Corbett**

Cataract, Glaucoma,  
Laser/Refractive Surgery



**Dr Joel Yap**

Cataract, Medical Retina, Vitreoretinal Surgery



**Dr Justin Mora**

Cataract, Glaucoma, Laser/Refractive Surgery,  
Paediatric/Strabismus





**Dr Rachael Niederer**

Uveitis, Medical Retina



**Dr Riyaz Bhikoo.**

Cataract, Medical Retina, Vitreoretinal  
Surgery, Ocular Oncology



**Dr Sarah Hull**

Cataract, Paediatric/Strabismus, Genetics



**Dr Sarah Welch**

Cataract, Vitreoretinal Surgery, Medical  
Retina



**Dr Shenton Chew**

Cataract, Glaucoma



**Dr Sid Ogra**

Cataract, Oculoplastics



**Dr Stephen Best**

Cataract, Glaucoma,  
Neuro-ophthalmology



**Dr Stuart Carroll**

Cataract, Paediatric/  
Strabismus, Laser/Refractive Surgery



**Dr Sue Ormonde**

Cataract, Cornea/Anterior  
Segment, Laser/Refractive Surgery



**Dr Taras Papchenko**

Cataract, Oculoplastics, Neuro-Ophthalmology



**Dr Yvonne Ng**

Cataract, Paediatric/Strabismus



# Vitreoretinal

Our retinal specialists strive to restore and preserve your vision

Auckland Eye's ophthalmologists are highly skilled at medically and surgically treating conditions of the retina and vitreous, such as macular degeneration, diabetic retinopathy, retinal detachments, and more.

Our cutting-edge clinic specialises in diagnosing and treating:



#### Night Blindness

Struggling to see in low light conditions?



#### Floaters, Spots, or Flashes

Noticing strange shapes that disrupt your vision?



#### Loss of Vision

Experiencing central or peripheral vision loss?



#### Distorted Words

Finding it difficult to read due to distorted text?

These symptoms could indicate underlying eye conditions that need attention.  
It's essential to prioritise your vision health!

Take the first step toward clearer, healthier vision!

Q [aucklandeye.co.nz](https://aucklandeye.co.nz)  
e. [admin@aucklandeye.co.nz](mailto:admin@aucklandeye.co.nz)  
p. 0800 25 53 93



AUCKLANDEYE  
Life Changing Eye Care

## 26.4 Doctors and their specialties

TREATMENT	DOCTOR						
Acutes	All Doctors						
Cataract	All Doctors						
Laser Eye Surgery	David Pendergrast	Dean Corbett	Stuart Carroll	Sue Ormonde	Justin Mora		
Cornea/Anterior Segment	Chi Ying Chou	David Pendergrast	Sue Ormonde				
Glaucoma	Aaron Wong	Chi Ying Chou	David Pendergrast	Dean Corbett	Shenton Chew	Stephen Best	Justin Mora
Lid & Watery Eye	David Pendergrast	Sid Ogra	Taras Papchenko				
ICL	Dean Corbett						
Paediatric	Sarah Hull	Stuart Carroll	Yvonne Ng	Justin Mora			
Medical Retina	Archie McGeorge	Alison Pereira	Sarah Welch	Joel Yap	Rachael Niederer	Riyaz Bhikoo	
Surgical Retina	Archie McGeorge	Sarah Welch	Joel Yap	Riyaz Bhikoo			
Oculoplastics	Sid Ogra	Taras Papchenko					
Ocular Oncology	Riyaz Bhikoo						
Neuro Ophthalmology	Stephen Best	Taras Papchenko					
Genetics	Sarah Hull						
Uveitis & Iritis	David Pendergrast	Rachael Niederer					
Dry Eye	David Pendergrast	Dean Corbett	Chi Ying Chou	Sue Ormonde			
Diabetic Screening	Alison Pereira	David Pendergrast					
Photodynamic Therapy	Alison Pereira	Riyaz Bhikoo					

# 26.2 Auckland Eye locations

All Auckland Eye specialists consult from our central rooms situated at 8 St Marks Road, Remuera, Auckland. Additionally, appointments are available at a number of satellite clinics across Auckland.

## Remuera

8 St Marks Road, Remuera

## Oasis Surgical

2 MacMurray Road, Remuera

## Takapuna

Auckland Eye North Shore

3 Fred Thomas Drive, Takapuna

## Ormiston

Ormiston Medical Centre

211 Ormiston Road, Ormiston

## New Lynn

Totara Health Services

1 McCrae Way, New Lynn

## Pukekohe

Franklin Specialist Suites

12 Glasgow Road

Pukekohe

## Westgate

Westgate Medical Centre

Fernhill Drive, Massey

## Out of Auckland

### Whangarei

Eye Specialists Ltd.

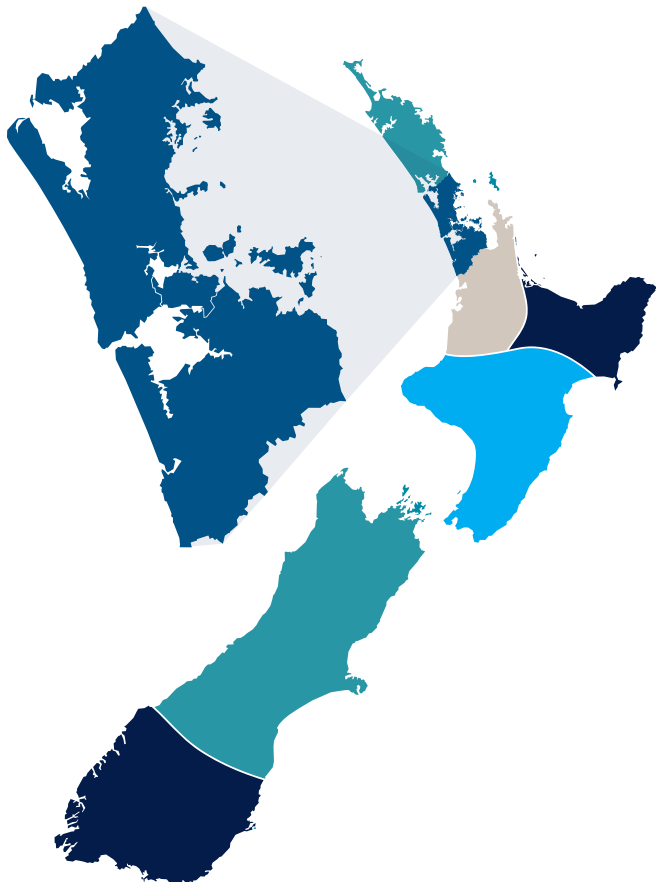
19 Kamo Road, Whangarei

### Queenstown

Kawarau Park Consulting Suites

Unit C, Kawarau Park Consulting Suites

Twelfth Avenue, Lake Hayes



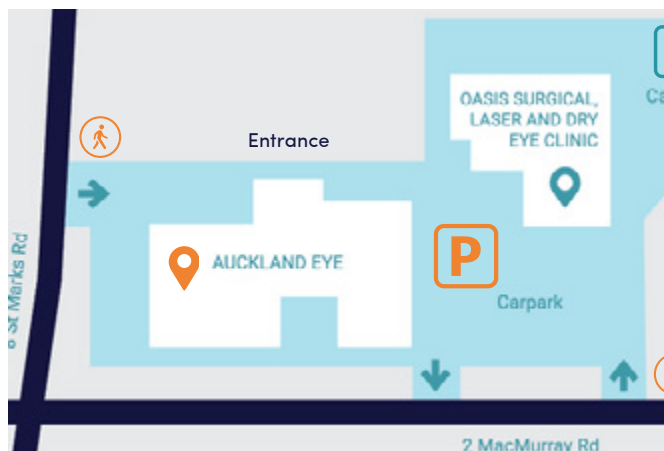
## Remuera

## Auckland Eye Remuera

8 St Marks Road, Remuera, Auckland

## Contact

09 529 2480



## Doctors

Dr Stephen Best  
Dr Chi-Ying Chou  
Dr Justin Mora  
Dr Sue Ormonde  
Dr Sarah Welch  
Dr Riyaz Bhikoo  
Dr Dean Corbett  
Dr Yvonne Ng  
Dr Taras Papchenko  
Dr Aaron Wong  
Dr Stuart Carroll  
Dr Sarah Hull  
Dr Rachael Niederer  
Dr David Pendergrast  
Dr Joel Yap  
Dr Shenton Chew  
Dr Archie McGeorge  
Dr Sid Ogra  
Dr Alison Pereira

## Services

All Ophthalmology  
Services

## Aesthetics

## Biometry

## Dry Eye Assessment

## Dry Eye Treatment

## Eyelash ablation

## Laser Assessment

OCT

Optos

Pachy

PDT Laser

Ret Laser

SLT

### SPR/ IV injections

Surgical Unit

## Topography

## Ultrasound Bscan

VF

## Yag Caps

Yag Pi

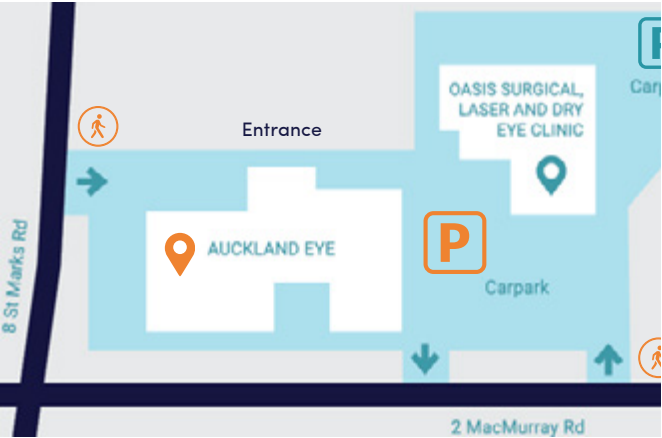# Remuera – Oasis

## Oasis Surgical Remuera

8 St Marks Road, Remuera, Auckland

### Contact

09 529 2480



### Doctors

Dr Stephen Best  
Dr Chi-Ying Chou  
Dr Justin Mora  
Dr Sue Ormonde  
Dr Sarah Welch  
Dr Riyaz Bhikoo  
Dr Dean Corbett  
Dr Yvonne Ng  
Dr Taras Papchenko  
Dr Aaron Wong  
Dr Stuart Carroll  
Dr Sarah Hull  
Dr Rachael Niederer  
Dr David Pendergrast  
Dr Joel Yap  
Dr Shenton Chew  
Dr Archie McGeorge  
Dr Sid Ogra  
Dr Alison Pereira

### Services

All Ophthalmology  
Services

Surgery

Aesthetics

Biometry

Dry Eye Assessment

Dry Eye Treatment

Eyelash ablation

Laser Assessment

Ret Laser

SPR/ IV injections

Surgical Unit

Topography

Ultrasound Bscan



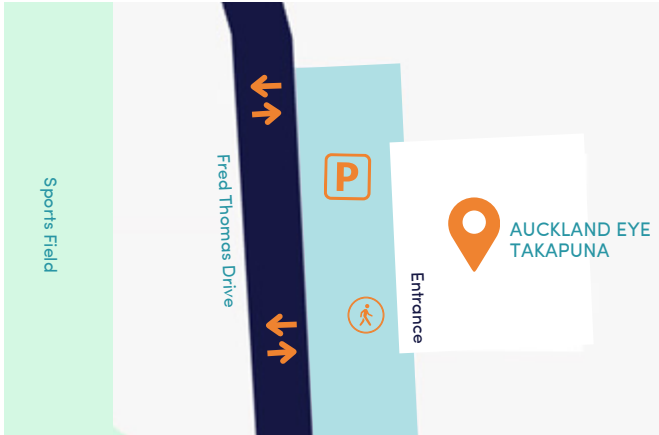# Takapuna

## Auckland Eye Takapuna

3 Fred Thomas Drive, Takapuna,  
Auckland 0622

### Contact

09 486 3937



### Doctors

Dr. Stephen Best  
Dr. Stuart Carroll  
Dr. Shenton Chew  
Dr. Chi-Ying Chou  
Dr. Dean Corbett  
Dr. Archie McGeorge  
Dr. Yvonne Ng  
Dr. Sue Ormonde  
Dr. Alison Periera  
Dr. Sid Ogra  
Dr. Riyaz Bhikoo  
Dr. Aaron Wong  
Dr. Rachael Niederer  
Dr. Taras Papchenko  
Dr. Joel Yap  
Dr. Sarah Hull

### Services

All Ophthalmology  
Services

Surgery

Aesthetics

Biometry

Dry Eye Treatment

Dry Eye Assessment

Eyelash ablation\*\*

Laser Assessment

OCT

Optos

Pachy

Ret Laser

SLT

SPR/ IV injections

Surgical Unit

Topography

Ultrasound Bscan

VF

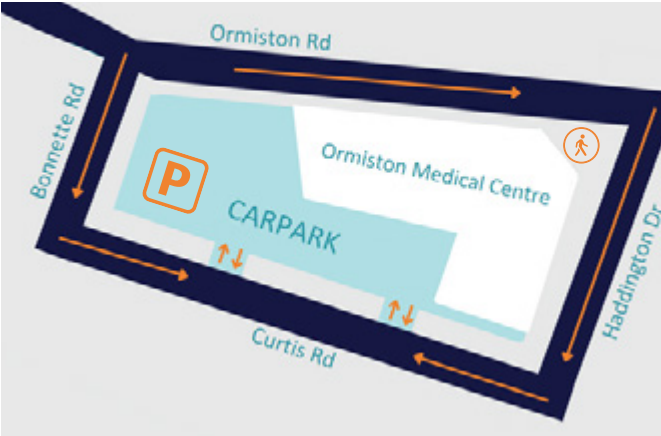
Yag Caps

# Ormiston

Level 1, Ormiston Medical Centre  
211 Ormiston Road, Flatbush

## Contact

09 282 2057



## Doctors

Dr. Stephen Best  
Dr. Shenton Chew  
Dr. Chi-Ying Chou  
Dr. Justin Mora  
Dr. Yvonne Ng  
Dr. Taras Papchenko  
Dr. David Pendergrast  
Dr. Sarah Welch  
Dr. Sid Ogra  
Dr. Joel Yap  
Dr. Riyaz Bhikoo  
Dr Aaron Wong

## Services

All Ophthalmology  
Services

Surgery

Aesthetics

Biometry

Eyelash ablation\*\*

Laser Assessment

OCT

Pachy

SLT

SPR/ IV injections

Surgical Unit

Topography

Ultrasound Bscan\*\*

VF

Yag Caps

Yag Pi

# New Lynn

Level 2, Totara Health Services  
1 McCrae Way, New Lynn

Contact  
09 529 2480

## Doctors

Dr Sid Ogra  
Dr. Shenton Chew  
Dr. Justin Mora  
Dr. Taras Papchenko  
Dr. Sarah Welch  
Dr. Joel Yap  
Dr Riyaz Bhikoo  
Dr Aaron Wong

## Services

All Ophthalmology  
Services

Biometry

OCT

Pachy

SLT

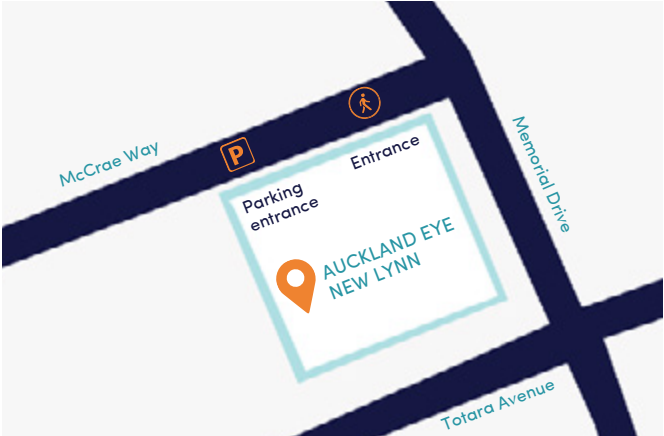
SPR/ IV injections

Ultrasound Bscan\*\*

VF

Yag Caps

Yag Pi



# Pukekohe/Franklin

Franklin Specialist Suite  
12 Glasgow Road, Pukekohe

Contact  
09 529 2480

## Doctors

Dr Riyaz Bhikoo  
Dr David Pendergrast  
Dr Justin Mora  
Dr Sarah Welch

## Services

All Ophthalmology  
Services

Eyelash ablation\*\*

OCT

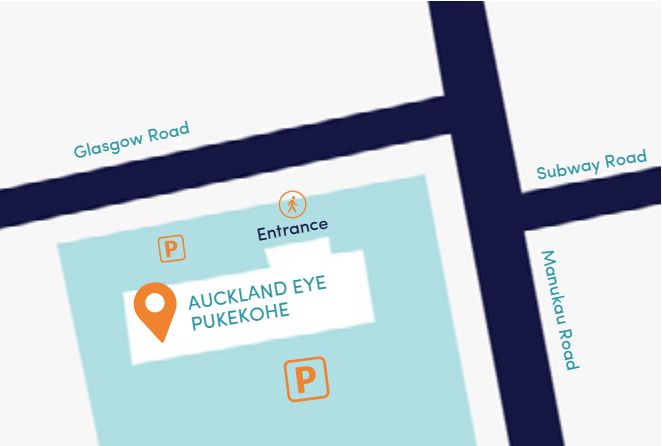
Pachy

SPR/ IV injections

Topography

Ultrasound Bscan\*\*

VF



# Westgate

## Westgate Medical Centre

13E Maki Street, Massey, Auckland

### Contact

09 529 2480

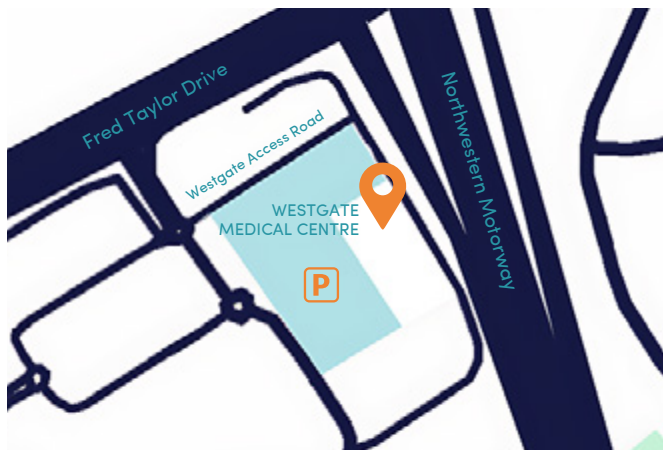
### Doctors

Dr Sue Ormonde

### Services

All Ophthalmology  
Services

Consultations



# Whangarei

## Eye Specialists

19 Kamo Road, Whangarei

## Doctors

Dr Joel Yap

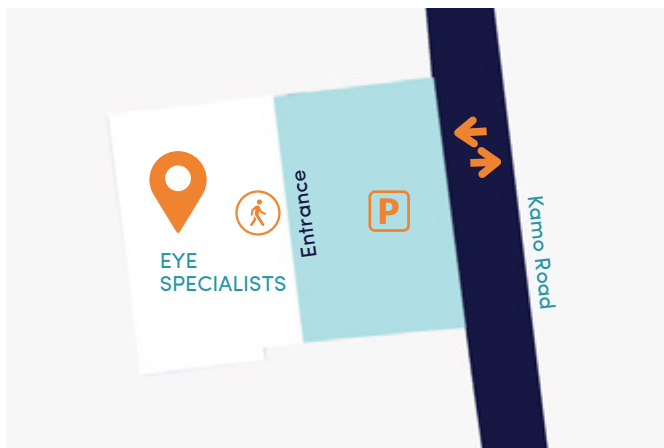
## Services

All Ophthalmology  
Services

Avastin Injections (IVA)

YAG laser

Retinal Laser



# Queenstown

Kawarau Park Consulting Suites Unit,  
Unit C, Twelfth Avenue, Lake Hayes,  
Queenstown 9304

### Contact

09 529 2480

### Doctors

Dr Riyaz Bhikoo  
Dr Sid Ogra  
Dr Joel Yap

### Services

All Ophthalmology  
Services

Biometry

Eyelash ablation

Laser Assessment

OCT

Pachy

Ret Laser\*\*

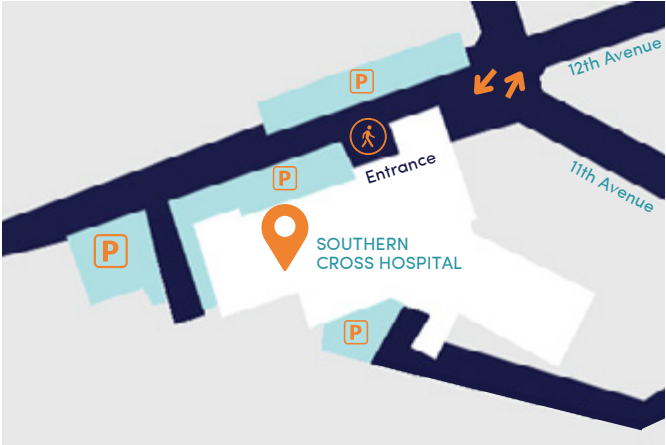
SPR/ IV injections

Topography

VF

Yag Caps

Yag Pi



## 26.3 Referrals

**Referrals can be made to Auckland Eye via our dedicated referral line:**

**Phone:** 09 520 9135  
**Email:** [referrals@aucklandeye.co.nz](mailto:referrals@aucklandeye.co.nz)  
**EDI:** auckleye  
**Mail:** PO Box, 99311, Newmarket, Auckland 1149  
**Website:** [www.aucklandeye.co.nz/optometrists/](http://www.aucklandeye.co.nz/optometrists/)  
[www.aucklandeye.co.nz/general-practitioners](http://www.aucklandeye.co.nz/general-practitioners)

### Insurance and ACC

#### **Southern cross patients:**

We can apply for pre-approval on behalf of patients and in most cases we can know instantly what cover patient has, so there is no guessing game for patients.

#### **NIB patients:**

If patients can obtain a pre-approval, then we can accept and claim on behalf of the patient.

#### **Other insurance companies:**

We provide the invoice to the patient after payment and we can assist them by providing the referral & clinic letter to help them make the claim.

#### **ACC:**

Auckland Eye is an affiliated ACC provider, therefore we can put the claim through ACC for patients, however there is no guarantee ACC will accept the claim. ACC patient should see the GP first where the ACC registration form is completed before sending to us.



## 26.5 Locations and Offerings

	Whangarei	Westgate	Takapuna	Remuera	Queenstown	New Lynn	Ormiston	Franklin
Aesthetics	✗	✗	✓	✓	✓	✓	✓	✗
Biometry	✓	*	✓	✓	✓	✓	✓	✗
Dry Eye Assessment	✗	✗	✓	✓	✗	✗	✗	✗
Dry Eye Treatment	✗	✗	✓	✓	✗	✗	✗	✗
Eyelash ablation	✗	✗	**	✓	✓	**	**	**
Laser Assessment	✗	✗	✓	✓	✗	✗	✓	
OCT	✓	✗	✓	✓	✓	✓	✓	✓
Optos	✓	✗	✓	✓	✗	✗	✗	✗
Orthoptic Assessment	✗	✗	✓	✓	✗	✗	✓	✗
Pachy	✓	✗	✓	✓	✓	✓	✓	✓
PDT Laser	✗	✗	✗	✓	✗	✗	✗	✗
Ret Laser	✓	✗	✓	✓	**	✗	✗	✗
SLT	✓	✗	✓	✓	✓	✓	✓	✗
SPR/ IV injections	✓	✗	✓	✓	✓	✓	✓	✓
Surgical Unit	✗	✗	✓	✓	✗	✗	✓	✗
Topography	✓	✗	✓	✓	✓	✗	✓	✓
Ultrasound Bscan	✓	✗	✓	✓	✗	**	**	**
VF	✓	✗	✓	✓	✓	✓	✓	✓
Yag Caps	✓	✗	✓	✓	✓	✓	✓	✗
Yag Pi	✓	✗	✓	✓	✓	✓	✓	✗

\*Biometry not available at Westgate but Cataract can be booked and biometry can take place on the day of surgery at Remuera.

\*\*Sent from SMEC (Portable Unit Used)



A state-of-the-art facility specialising in advanced eye surgery and private surgical care.

**Cataract  
Surgery**



**Retinal  
Surgery**



**Squint  
Surgery**



**Eyelid  
Surgery**



**Corneal  
Surgery**



**Refractive  
Surgery**



**Dry Eye  
Clinic**



**Aesthetics**



Discover Oasis Surgical and experience a contemporary, tranquil setting for surgeries. Ample, convenient parking, inviting day-stay spaces, and cutting-edge surgical facilities boasting the latest in ophthalmic technology.

2 MacMurray Road, Remuera, Auckland

 [oasissurgical.co.nz](https://oasissurgical.co.nz)

Medical professionals interested in our state of the art facility are welcome to get in touch!

09 524 1820

[reception@oasissurgical.co.nz](mailto:reception@oasissurgical.co.nz)





**AUCKLANDEYE**  
Life Changing Eye Care

## **Auckland Eye**

8 St Marks Road  
Remuera, Auckland, NZ  
P O Box 99311, Newmarket, Auckland, NZ

**Phone:** 0800 25 53 93 (8am –5pm)

**Email:** [admin@aucklandeye.co.nz](mailto:admin@aucklandeye.co.nz)

**Website:** [www.aucklandeye.co.nz](http://www.aucklandeye.co.nz)

## **Opening Hours:**

Monday to Friday 7am – 6pm

Saturday by appointment only

First edition published by Auckland Eye, 2012

Modified 2024

13 5 7 9 10 8 6 4 2

Copyright © Auckland Eye, 2024

The right of Auckland Eye to be identified as the author of this work in terms of section 96 of the Copyright Act 1994 is hereby asserted.

Designed and typeset by Ideology Limited

Digitally published by Ideology Limited

All rights reserved. Without limiting the rights under copyright reserved above, no part of this publication may be reproduced, stored in or introduced into a retrieval system, or transmitted, in any form or by any means (electronic, mechanical, photocopying, recording or otherwise), without the prior written permission of both the copyright owner and the above publisher of this book.